Stomatološki vjesnik

Stomatological review

Stomatološki vjesnik 2016; 5 (1-2)

ISSN 0350-5499 UDK 616.31

Izdavač / Publisher: Stomatološki fakultet Univerziteta u Sarajevu / Faculty of Dentistry, University of Sarajevo

Za izdavača / For publisher: Muhamed Ajanović

ČLANOVI UREĐIVAČKOG ODBORA / EDITORIAL BOARD :

Glavni urednik / Editor in chief: Sadeta Šečić

Sekretar uređivačkog odbora / Secretary of editorial board: Selma Zukić

Članovi /Members: Sead Redžepagić, Muhamed Ajanović, Sedin Kobašlija, Amra Vuković, Enita Nakaš, Sanja Hadžić, Alma Konjhodžić Prcić, Lejla Kazazić

MEĐUNARODNI UREĐIVAČKI ODBOR / INTERNATIONAL EDITORIAL BOARD:

Anwar Barakat Bataineh (Irbid, Jordan), Jasenka Živko-Babić (Zagreb, Hrvatska), Andrija Petar Bošnjak (Rijeka, Hrvatska), Hrvoje Brkić (Zagreb , Hrvatska), Dolores Biočina Lukenda (Split, Hrvatska), Davor Katanec (Zagreb, Hrvatska), Šahza Hatibović Koffman (London Ontario Kanada), Mladen Kuftinec (USA), Darko Macan (Zagreb, Hrvatska), Berislav Perić (Zagreb, Hrvatska), Tore Solheim (Oslo, Norveška), Dragoslav Stamenković (Beograd, Srbija), Marin Vodanović (Zagreb, Hrvatska)

Lektor za engleski jezik / English language editor: Nermana Bičakčić

Tehničko uređenje / Technical editor: Branislav Trogrančić

Štampa / Printed by: Štamparija Fojnica

Dizajn naslovnice / Cover page design: Lana Malić

Tiraž/ Number of copies: 200

KONTAKT / CONTACT:

Stomatološki vjesnik
Stomatološki fakultet sa klinikama
Bolnička 4a, 71000 Sarajevo
Bosna i Hercegovina
Telefon: + 387(33)214 294
e-mail: stomatoloskivjesnik@sf.unsa.ba
Web: www.stomatoloskivjesnik.ba

TRANSAKCIJSKI RACUN / TRANSFER ACCOUNT:

33386902296551066
UniCredit Bank dd

Printed on acid free paper

Svrha i i cilj :

Stomatološki vjesnik je neprofitni naučno stručni časopis koji publicira originalne naučne radove, prikaze slučajeva, pisma uredniku, savremene perspektive, editorijale, preliminarne komunikacije u oblasti stomatologije i drugih biomedicinskih nauka. Radovi su na Bosanskom/Hrvatskom/Srpskom jeziku sa naslovom, sažetkom i ključnim riječima bilingvalnim B/H/S i engleskom jeziku. Radovi se mogu koristiti u edukacijske svrhe bez predhodnog odobrenja, a uz obavezno navođenje izvora. Korištenje cijelih ili dijelova članaka u komercijalne svrhe nije dozvoljeno bez predhodnog pismenog odobrenja izdavača Autorska prava posjeduje izdavač: Stomatološki fakultet sa klinikama Univerziteta u Sarajevu.

Aim and Scope:

Stomatološki vijesnik / Stomatological review is a non-profit scientific journal that publishes original articles, case reports, letters to the editors, current perspectives, editorials, fast-track articles in a field of dentistry and other bio-medical sciences. Papers are in Bosnian/ Croatian/Serbian language with at least title, abstract and key words bilingual in B/C/S and English language. All manuscripts undergo the peer review process before can be accepted for publishing in Stomatološki vjesnik/ Stomatolgical review. Papers can be used for educational purposes without prior consent only with adequate citation of the sources. Using whole or parts of articles for commercial purposes is not permitted without prior written permission of the publisher. Copyright owns the publisher: Faculty of Dentistry with Clinics, University of Sarajevo.

Časopis Stomatološki vjesnik je oslobođen poreza na promet prema Mišljenju Federalnog ministarstva obrazovanja, nauke, kulture i sporta br: 04-15-661/2002.

Journal Stomatological review is tax exempt according to the opinion of the Federal Ministry of Education Science Culture and Sports no: 04-15-661/2002.

Indexed in: **IIC** (Index Copernicus International), **DOAJ** (Directory of Open Access Journal), **EZB** (Electronishe Zeitschriftenbibliothek), **SJIF** (Scientific Journal Impact Factor Value 2.502), **EBSCO**, **HINARI**, **INFOBASE**, **GOOGLE SCHOLAR, AE GLOBAL INDEX, DRJI ORG, SJIF, ONE SEARCH, PUBGET, RESEARCH BIBLE, SIS**

Stomatološki vjesnik

CONTENTS / SADRŽAJ

OUTCOME OF IMPLANT SUPPORTED SINGLE-TOOTH CROWNS IN ANTERIOR MAXILLA USING OBJECTIVE INDICES AND PATIENTS' PERCEPTIONS: A YEAR PROSPECTIVE STUDY

Tosum S.*[1], Ajanović M.[1], Kamber-Ćesir A.[1], Dervišević A.[2], Kazazić L.[1]

[1] Department of Prosthodontics, Faculty of Dentistry, University of Sarajevo, Sarajevo, Bosnia and Herzegovina
[2] Department of Maxillofacial Surgery, Faculty of Dentistry, University of Sarajevo, Sarajevo, Bosnia and Herzegovina

***Corresponding author**

Tosum Selma, PhD
Department of Prosthodontics
Faculty of Dentistry
University of Sarajevo
Bolnička 4a
71000 Sarajevo
Bosnia and Herzegovina
Phone: +387 (33) 214 249
e-mail: selma_tosum@hotmail.com

ABSTRACT

Aim: The main purpose of this study was to determine the degree of success of oral rehabilitation in patients with implant therapy using implants bredent blueSKY (bredent medical GmbH & Co.KG Senden, Germany).

Materials and methods: The study evaluated 32 implants a year after the implant therapy. The observed patients were of both sexes, aging from twenty to seventy years and randomly sampled. All patients underwent the OHIP-CRO49 index in order to determine the level of their satisfaction with implant therapy, implant type bredent blueSKY. The ICAI index was assessed aiming to determine the degree of success in aesthetic and functional rehabilitation.

Results: In 23 individuals of both sexes with an average age of 60.13 ± 13.1 (21-73) who were included in the study, a total of 32 implants retaining a single-crown tooth restoration were inserted. In our research we used a conventional (two-phase) restoration of implants, without immediate loading. The crown was installed 90 days after the placement of the implants. With ICAI (Implant Crown Aesthetic Index), in the results of our study with the largest number of the implant-supported single-tooth restoration, labial gingival margin did not differ from the labial edge of the control natural tooth. In significantly smaller number of compensation (3.13%), the deviation was greater than 1.5 mm compared to the control natural tooth (chi-square test, p = 0.001). No deviation was found in 56.25% cases and in 40.63% there was a deviation less than 1.5 mm. Chi square test showed a statistically significant difference. The highest total OHIP score was 142 and was recorded in one patient. Most of the patients had a total OHIP score 0 meaning a favorable quality of life.

Conclusions: A statistically significant difference was found in a distribution of the implant-supported single-tooth restorations cemented on implants type bredent blueSKY, with varying degrees of aesthetic success / failure. The largest number of single tooth crowns achieved satisfactory aesthetic outcome one year after being in function.

Key words: dental implant, oral rehabilitation, single tooth crown, gingiva.

Introduction

The goal of dentistry is to restore lost functions of stomatognathic system such as: chewing, speech, esthetic, comfort. Regardless of the bone atrophy, disease, or injury of the stomatognathic system, implant dentistry could achieve an ideal goal [1].

The use of implants prosthetically restores function and aesthetics. The loss of a single tooth has become a common treatment alternative to conventional tooth supported reconstruction, mainly due to the benefit of avoiding sacrificing the intact tooth substance of adjacent teeth.

The use of implants prosthetically restores function and aesthetics. The loss of a single tooth has become a treatment option instead of conventional fixed prosthesis, mainly due to the benefit of avoiding the preparation of adjacent teeth [2,3]. As the predictability of dental implants has been proved beyond doubt, achieving a good success rate in terms of stability is no longer a big concern among dentist, but aesthetic success of therapy is of mayor concern now [4].

Restoration of the missing tooth should not be designed only to withstand the forces of occlusion and mastication, but also to create an acceptable aesthetic result [5].

For many patients, an aesthetic result is the main motivating factor when deciding in favor of dental implantation [6-8]. In visible anterior region priority is given to aesthetics while in the posterior region the function can be emphasized as the most important factor. But requirements for aesthetics and function must be balanced with regard to predictable longevity, minimal biological effects and cost aspects [9].

Achieving an aesthetically optimal result is determined by a number of factors: tooth related factors such as tooth dimensions, form and color contribute to aesthetics as well as soft tissue-related factors including inter-dental and mid-facial soft tissue dimensions, texture and color [10]. When estimating aesthetic of the crown restoration, it should be considered that the crown restoration has to be in harmony and symmetry with the crown form adjacent natural teeth as well as with the one of the contralateral tooth [11]. Soft tissue management is one of the final esthetic result, with the need to harmonize color, form, and contour with that of the adjacent tissues [12].

The concern from an aesthetic point of view is also the topography of the surrounding soft tissues i.e., the position of the soft tissue margin at the facial aspect of the crown and the degree of inter-dental papillae fill in the embrasure spaces lateral to the implant-supported crown [11,13].

Meijer et al. introduced a new index for rating aesthetics of implant-supported single crowns and adjacent soft tissue – the Implant Crown Aesthetic Index (ICAI). This index is important for considering parameters for the evaluation of the implant crown and peri-implant mucosa [14].

The recent concepts of implant dentistry is not restricted to the basic needs, but has evolved to cosmetic or aesthetic correction to uplift the self-esteem and confidence of people [4].

To evaluate patients' view regarding the change in their quality of life after receiving dental implant treatment, the Oral Health Impact Profile-49 (OHIP-49) was developed. The OHIP-49 is a reliable and valid instrument for detailed measurement of the social impact of oral disorders and has potential benefits for clinical decision making and research [15,16].

The main purpose of this study was to determine the degree of success of oral rehabilitation in patients with implant therapy using implants bredent blueSKY (bredent medical GmbH & Co.KG Senden, Germany).

Materials and methods

In this prospective study, patients with tooth loss in the aesthetic region in maxilla that were referred to the Faculty of Dentistry in Sarajevo for prosthetic rehabilitation were included. This study was approved by the Ethics Committee of the Faculty of Dentistry, and it was conducted in accordance with the ethical principles of the Helsinki. Patients were informed of the options for tooth replacement including the risks and benefits of dental implants. All included patients required replacements with single-tooth restorations. The inclusion criteria were: age >18, single tooth loss in the maxillary front, presence of contra-lateral natural tooth, good oral hygiene. The exclusion criteria were: history of radiotherapy in head and neck, current chemotherapy, metabolic bone disorders, absence of any serious systemic disease which would jeopardize bone healing, glucocorti-

coids and bisphosphonates medication. The study evaluated 32 implants a year after the implant therapy. Observed patients were of both sexes, aging from twenty to seventy years (mean age: 60.13±13.1) and randomly sampled. Surgical treatment was carried out under local anesthesia by specialist in prosthodontics and oral implantology, following manufactures instructions. Metal-ceramic crowns and metal alloy abutments were used for the coronal part in all constructions.

All patients underwent the Croatian version of the Oral Health Impact Profile questionnaire (OHIP-CRO49 index) to determine the level of patient satisfaction with implant therapy, implant type bredent blueSKY® (bredent medical GmbH & Co. KG Senden, Germany). The OHIP-CRO49 consisted of 49 questions. Each answer was scored with a Likert response scale from 0 (never experienced problem) to 4 (problem experienced very often). Higher scores indicated more impaired oral health. The questionnaire was filled in by hand at the Clinic without assistance [16].

Patients were clinically examined one year after completion of implant-supported restorations. The contra-lateral/natural tooth was used as a reference when a single implant rehabilitation was assessed [7]. The ICAI index was assessed, with a goal to determine the degree of success in aesthetic and functional rehabilitation. The ICAI evaluates five variables for the crown restoration (hard tissue) of the implants and four variables for the mucosa (soft tissue) surrounding the implant (color, anatomic contour and surface texture). These nine variables were: 1. Mesiodistal dimension of the crown, 2. Position of the incise edge of the crown, 3. Labial convexity of the crown, 4. Color and translucency of the crown, 5. Surface of the crown, 6. Position of the labial margin of the peri-implant mucosa, 7. Position of mucosa in the approximate embrasures, 8. Contour of the labial surfaces of the mucosa, 9. Color and surface of the labial mucosa. Each item is given score I, while major / gross deviation takes 5 penalty points. The total score leads to judgment regarding aesthetics: 0 penalty points = excellent; I or 2 points = satisfactory; 3 or 4 points = moderate; 5 or more points = poor aesthetics.

The score ranging from 0 to 45, where 0 represents the most positive score. Statistical analysis was performed using software package SPSS for Windows version 18.0. The descriptive analysis of data was presented as frequency and mean ± standard deviation, minimal and maximal value. Che-square test was performed to determine differences for variables: mesio-distal dimension of the crown, labial convexity of the crown, the color and translucency of the implant-supported crown, the position of the labial margin of the peri-implant mucosa, the position of mucosa in approximate embrasures, the color and surface of the labial mucosa of the implant-supported crown. Spearman rank correlation was used to determine correlation between the quality of life and three variables: age, gender and smoking habits. The level of statistical significance was set at 5%.

Results

The study included 23 patients (age: 21-73 years) treated for tooth loss with 32 dental implants. All the patients had received an implant-supported crown following tooth loss due to TDI (traumatic dental injury). 53.1% were female and 46.9% male. According to smoking habits, 78.1% were non-smokers and 21.9% smokers.

Excellent aesthetic (score O) was carried out by 18,8% evaluated metal-ceramic crowns on implant supported single tooth restorations; 68,8% showed satisfactory aesthetic success (score 1 or 2); 6.1% moderate aesthetic success (score 3 or 4) and only two patients (6.1%) had poor aesthetics success (score 5 and 10)(**Table 1.**).

Aesthetic success (total ICAI score)	N (%)
Excellent (Score=0)	6 (18,8%)
Satisfactory (Score =1 or 2)	22 (68,8%)
Moderate (Score =3 or 4)	2 (6,2%)
Poor aesthetics (Score =5 or more)	2 (6,2%)
Total	**32 (100%)**

Table 1.
The frequency of total ICAI scores as indicators of aesthetic success of prosthetic restorations

	Aesthetic success*	Aesthetic failure**
Smokers	0 (0,0%)	7 (21,9%)
Non-smokers	4 (12,5%)	21 (65,6%)
Total	**32 (100%)**	
Women	3 (9,4%)	14 (43,8%)
Men	1 (3,1%)	14 (43,8%)
Total	**32 (100%)**	

* Aesthetic success: total ICAI=0-2; ** Aesthetic failure: total ICAI ⩾ 3

Table 2. Aesthetic success of prosthetic restoration according gender and smoking habits

Domain	Quality of life			
	Favorable		Unfavorable	
	N	%	N	%
Functional limitation	20	62.5	12	37.5
Physical discomfort	20	62.5	12	37.5
Psychological discomfort	27	84.4	5	15.6
Physical disability	28	87.5	4	12.5
Psychological disability	29	90.6	3	9.4
Social disability	30	93.8	2	6.2
Handicap	29	90.6	3	9.4

N= number of implant-supported single-tooth restorations
[a] Chi square test

Table 3. Evaluation of quality of life according OHIP domains

Total OHIP score	N
0	12
1	10
2	4
6	2
8	1
36	1
49	1
142	1
Total	**32**

Table 4. Frequency of total OHIP score

According to mesio-distal dimension of the crown, there were 75.0 % without deviation, 18.8% were slightly under-contoured compared to contra-lateral tooth, 6.3 % were slightly over-contoured compared to contra-lateral tooth. Chi square test revealed statistical significance (p<0.001).

According to position of incisal edge of the implant-supported crown, there were no deviation.

Labial convexity of the crown was in the most cases (93.8%) in harmony with the adjacent tooth and in 6.2 % was big mismatch. Chi square test revealed statistical significance (p<0.001).

The color and translucency of the implant-supported crown were in harmony with contra-lateral tooth in the most cases (81.3%) and in 18.8% was a slight mismatch. Chi square test revealed statistical significance (p<0.001).

Analysis of the position of the labial margin of the peri-implant mucosa showed no deviation in 56.25%, 40.63% deviation was less than 1.5 mm and 3.13% deviation was more than 1.5 mm (Chi square test, p=0.001).

Analysis of the position of mucosa in the approximate embrasures showed no deviation in 87.5% and 12.5% deviation less than 1.5 mm (Chi square test, p<0.001).

Analysis of the contour of the labial surface of the mucosa showed no deviation in 87.5%, 9.4% slightly under-contoured and 3.1% rather over-contoured.

The color and surface of the labial mucosa of the implant-supported crown were statistically different compared to contra-lateral natural tooth; 78.1% had no mismatch, 21.9% had slight mismatch (Chi square test, p= 0.001) (**Table 2.**).

Spearman rank correlation revealed no statistically significant correlation between aesthetic success prosthetic restoration and: age (rho=-0.283, p=0.117), gender (rho=-0.166, p=0.365) and smoking habits (rho=-0.200, p=0.272).

Analysis of seven domains of OHIP-49 showed no statistical significance in two domains: functional limitation and physical discomfort (**Table 3.**).

The highest total OHIP score was 142 (one patient). 12 patients had total OHIP score 0 (**Table 4.**).

The mean value and standard deviation of total OHIP score were presented in **Table 5**. and **Table 6**.

Spearman rank correlation revealed no statistical significant correlation between the quality of life of implant supported single-tooth restoration in

aesthetic zone and: age (rho=-0.302, p=0.093), gender (rho=-0.081, p=0.660) and smoking habits (rho=-0.059, p=0.750).

Logistic regression showed no statistically significant influence of gender, age, smoking habits as a predictor of quality of life with implant supported single tooth restorations (**Table 7.**).

Discussion

In our study, the mesio-distal width of the most implant-supported crown was different compared to mesio-distal width of clinical crown of contra-lateral tooth and the difference was statistically significant. Chang et al. found no statistically significant differences in mesio-distal width of the implant-supported crown and the clinical crown of contra-lateral tooth [7]. In study from 2009., after guided bone regeneration and early implant placement (Nobel-replace tapered Ti Unite® Nobel Biocare, Göteborg, Sweden), Cosyn at al. found the mean disparity width of 0.2 mm between the implant crown and teeth [10].

Vilhjálmur et al. evaluated aesthetic outcome of implant-supported crowns in the anterior maxilla and periimplant soft tissue using three different indexes: ICAI, modified version of the ICAI (mod-ICAI), Pink Aesthetic Score (PES), and the index of Californian Dental Association (CDA), one year after the crown placement. Implants used in this study were Brånemark (Nobel Biocare, Göteborg, Sweden) or Astra (Astra Tech AB, Mödalen, Sweden). They found correlation between color of the new crown and the sum of hard tissue related items of the ICAi and the mod-ICAI was significant [17].

In our study, the position of incision edge of the implant-supported crown was in harmony with contra-lateral tooth. From available literature we didn't find relevant results for the position of incision edge but Chang et al. measured the distance between the soft tissue margin and the incision edge and found statistically significance difference in clinical crown length in aesthetic maxillary region. The crowns supported by implants (Brånemark, Nobel Biocare, Göteborg, Sweden) were on the average 1.0 mm longer than the clinical crown of contra-lateral teeth [7]. To the contrary, Cosyn et al. found no statistically significant difference in clinical crown length [10].

Total OHIP score	
Mean Value	8,28
95% confidence interval	from -1,29 to 17,85
Median	1,00
Standard deviation	26,536
Minimum	0
Maximum	142

Table 5. Descriptive statistics of total OHIP score

	Quality of life	
	Favorable*	Unavorable**
Smokers	3 (9,36%)	4 (12,50 %)
Non-smokers	9 (28,13%)	16 (50,0 %)
Total	**32 (100%)**	
Women	7 (21,88%)	10 (31,25 %)
Men	5 (15,63%)	10 (31,25 %)
Total	**32 (100%)**	

*Total OHIP score=0; ** Total OHIP score ⩾1

Table 6. The quality of life of patients with implant supported single-tooth restoration according gender and smoking habits

Predictor	B	S.E.	Sig.	Exp(B)
Gender	-,469	,794	,554	,626
Age	-,094	,060	,115	,910
Smoking habits	-,404	,928	,663	,667

Table 7. Logistic regression: Influence of gender, age and smoking habits on the quality of life

Choquet et al. concluded that the shape of the crown may be more difficult to fit with the neighboring teeth and the contra-lateral tooth especially when there is lack of alveolar bone and soft tissue in the implant region [18].

In the study of 53 implant supported single-tooth replacements Scheller et al. reported that a majority (75%) of the implant-supported crowns the soft tissue margin remained stable during a 5-year follow-up period and that recession of the soft tissue margin occurred at only 10% of the single implant restorations [19]. These results are in accordance with our results from 1-year follow-up period.

In the highest percentage in our study inter-dental papillae of implant-supported single crowns were in harmony with contra-lateral tooth (87.5%), which is consistent with the results reported by Cosyn et al. They found a borderline significant difference (p= 0.053) in the mesial papilla height between implant crowns and contra-lateral teeth. The mesial papilla was on average 0.4 mm and the distal papilla 1mm shorter at implant restoration in comparison with the corresponding site at contra-lateral teeth [10].

Three years after treatment, 59 patients with 98 implant supported single-tooth , Hosseini et al. evaluated aesthetic outcome of peri-implant mucosa using Copenhagen Index Score. They used three abutment materials (zirconia, titanium and gold alloy) and the results showed that the color of the marginal mucosa was comparable at zirconia and metal abutments. When titanium abutments were used, in 52 % cases there was no marginal discoloration. In our study, in 87.5% cases, the color and surface of the labial mucosa of implant-supported single crowns were in harmony with contra-lateral tooth [20].

In this study, a possible impact on oral health-related quality of life after implant treatment was evaluated using OHIP-CRO49 index. Oral Health Impact Profile is explicitly aimed to collect a variety of impacts ranging from oral functional effects to pain and personal affects as well as social interaction. The theoretical model and empirical methods are used to constitute the aspects of the OHIP which are distinctive from other indices such as those developed by Cushing et al., Atchinson and Dolan and Strauss and Hunt [16,21,22,23]. The OHIP-49 is suitable for use as an outcome measure in a clinical trial in which different treatment protocols are compared, and it is regarded as the best descriptor of the consequences of oral disorders [16]. Treatment with dental implants results in a major change of the oral status for patients, but implants will never precisely replicate the feeling of natural teeth. On the other hand, implant therapy will most certainly influence appearance, speech, chewing function, temper, and self-esteem thus affecting a patient's quality of life [24,25]. Erkapers et al. reported that the patients treated with immediately loaded implants in the edentulous maxilla generally reported statistically significant increased satisfaction. All seven domains showed a statistically significant improvement in the post-treatment period[26]. The quality of life was estimated as better in five domains (psychological discomfort, physical disability, psychological disability, social disability, handicap) than functional limitation and physical discomfort. However, responses for these two domains were more favorable than unfavorable.

The equal number of male and female patients estimated their quality of life as unfavorable (**Table 6**). Factors such as age, gender, education, self-esteem, functionality and past dental history may also contribute to a patient's opinion regarding the aesthetics of the single crown of implants and its adjacent mucosa.

Conclusion

A statistically significant difference was found in the distribution of the implant-supported single-tooth restorations cemented on implants type bredent blueSKY, with varying degrees of aesthetic success / failure. The largest number of single tooth crowns achieved satisfactory aesthetic outcome one year after being in function.

Declaration of interest

No conflict of interest as declared by authors.

References

1. Tatum OH: The Omni implant system. Proceedings of the Alabama Implant Congress, Birmingham, Ala, May 1988.

2. Andreasson, B. Implants for single-tooth replacement. A clinical and experimental study on the Brånemark CeraOne system. Swedish Dental Journal, supplement 1995;108; 7-41.

3. Misch CE. Dental Implant Prosthetics. 1st ed. St Louis, Missouri. Mosby publisher. 2005. Pg 35.

4. Elias AC, Sheiham A. The relationship between satisfaction with mouth and number and position of teeth. J Oral Rehab 1998; (25):649–61.

5. Qualtrough AJ, Burke FJ.A look at dental esthetics. Quinn. Int. 1994: (25):7-14.

6. Chang M, Odman PA, Wennstrom JL, Andersson B. Esthetic outcome of implant-supported single-tooth replacements assessed by the patient and by prosthodontics. Int J Prosthodont 1999; 12 : 335-341.

7. Chang M, Wennstrom JL, Odman PA, Andersson B. Implant supported single-tooth replacements compared to contralateral natural teeth. Crown and soft tissue dimensions. Clin Oral Implants Res 1999; 10: 185-194.

8. Sammartino G, Marenzi G, di Lauro AE, Paoloantoni G. Aesthetics in oral implantology: biological, clinical, surgical and prosthetic aspects. Implant Dent. 2007; 16:54-65.

9. Priest GF. Esthetis comparison of alternatives for replacement of a single missing tooth. J of Esth Dent 1996; (8):58-65.

10. Jan Cosyn, Tim De Rouck. Aesthetic outcome of single-tooth implant restorations following early implant placement and guided bone regeneration: crown and soft tissue dimensions compared with contralateral teeth. Clin Oral Impl Res 2009; (20): 1063–1069.

11. Phillips, K. & Kois, J.C. Aesthetic peri-implant site development. The restorative connection. Dental Clinics of North America 1998; (42); 57-70.

12. Croll BM. Emergence profiles in natural tooth contour. Part I: Photographic observations. J Prosthet Dent 1989; (62):4–10.

13. Takei H, Yamada H, Han T. Maxillary anterior estethics. Preservation of the interdental papilla. Dental Clinics of North America 1989; (33); 263-273.

14. Meijer HJA, Stellingsma K, Meijndert L, Raghoebar GM. A new index for rating aesthetics of implant-supported single crowns and adjacent soft tissue- The Implant Crown Aesthetic Index. A pilot study on validation of a new index. Clin. Oral Impl. Res 2005; (16): 645-649

15. Allen PF, McMillan AS, Walshaw D, Locker D. A comparison of the validity of generic- and disease-specific measures in the assessment of oral health–related quality of life. Community Dent Oral Epidemiol 1999; (27):344–352.

16. Slade GD, Spencer AJ. Development and evaluation of the Oral Health Impact Profile. Community Dent Health 1994; (11):3–11.

17. Vilhjálmur VH, Kristin SK, Kjell S,Asgeir B. Aesthetics of implant-supported single anterior maxillary crowns evaluated by objective indices and participants' perceptions. Clin. Oral Impl. Res. 2011; (22): 1399-1403.

18. Choquet V, Hermans M, Adriaenssens P, Daelemans P, Tarnow DP, Malevez C. Clinical and radiographic evaluation of the papilla level adjacent to single-tooth dental implants. A retrospective study in the maxillary anterior region. J Periodontol. 2001; 72:1364-71.

19. Scheller H, Urgell JP, Kultje C, Klineberg I, Goldberg PV, Stevenson Moore P, Alonso JMN, Schaller M, Corria RM, Engquist B, Toreskog S, Kastenbaum F & Smith CR. A 5-year multicenter study on implant-supported single crown restorations. Intern Journal of Oral and Maxilofacial Implants 1998; (13): 212-218.

20. Hosseini M,Worsaae N, Schiødt M, Gotfredsen K. A 3-year prospective study of implant –supported, single-tooth restorations of all-ceramic and metal-ceramic materials in patients with tooth agenesis. 2012: 1-10.

21. Cushing AM, Sheiham A, Maizels J. Developing sociodental indicators- the socialimpact of dental disease. Com Dent Health 1986; (3):3-17.

22. Atchinson KA, Dolan TA. Development of the Geriatric Oral Health Assesment Index. J of Dent Edu 1009; (54):680-687.

23. Strauss RP, Hunt RJ. Understanding the value of teeth to older adults: influencs on the quality of life. J of the American Dent Ass 1993; (124):105-110.

24. Reisine ST, Fertig J, Weber J,Leder S. Impact of dental conditions on patient's quality of life. Community Dent Oral Epidemiol 1989;17:7-10.

25. Awad MA, Locker D, Korner-Bitensky N, Feine JS. Measuring the effect of intra-oral implant rehabilitation on health-related quality of life in a randomized controlled clinical trial. J Dent Res 2000; 79:1659-1663.

26. Erkapers M, Ekstrand K, Baer RA, Toljanic JA, Thor A. Patient satisfaction following Dental Implant Treatment with Immediate Loading in the Edentulous Atrophic Maxilla. Int J Oral Maxillofac Implants 2011;(26):356–364.

PERIODONTAL STATUS AND CANDIDA CARRIAGE IN TYPE 1 DIABETES MELLITUS

Huseinbegović A.*[1], Fazlić Imamović R.[2], Bektaš S.[3], Bajrić E.[1], Dedić A.[4], Šečić S.[5]

[1] Department of Preventive Dentistry and Pedodontics , Faculty of Dentistry, University of Sarajevo, Sarajevo, Bosnia and Herzegovina
[2] Dental department of Health centre of the Sarajevo Canton, Sarajevo, Bosnia and Herzegovina
[3] Department of Microbiology, Institute for Public Health of the Sarajevo Canton, Sarajevo, Bosnia and Herzegovina
[4] Department of Oral Medicine and Periodontology, Faculty of Dentistry, University of Sarajevo, Sarajevo, Bosnia and Herzegovina
[5] Department of Oral Surgery, Faculty of Dentistry, University of Sarajevo, Sarajevo, Bosnia and Herzegovina

***Corresponding author**

Amina Huseinbegović, Ph.D
Faculty of Dentistry
Bolnička 4a
71000 Sarajevo
Bosnia &Herzegovina
Phone: +387 (33) 216-219
e-mail:
aminahuseinbegovic@hotmail.com

ABSTRACT

Objective: The aim of our study was to evaluate the association of type 1 diabetes mellitus as well as of metabolic control of the disease, with the periodontal health and Candida carriage in diabetic adolescents.

Methods: The study sample consisted of 90 school adolescents aged 12-18 years, divided into two groups. Diabetic group consisted of 60 patients with type 1 diabetes mellitus divided into two sub-groups: D1 with individuals having well controlled glycemia and D2 having poorer metabolic control, each consisting of 30 patients. Control group consisted of 30 healthy individuals. Plaque index and gingival index as described by Sillnes and Löe, as well as Community Periodontal Index, were used to assess the level of oral hygiene and periodontal health. Cotton swab samples from oral mucosa were taken and cultured in order to determine Candida carriage.

Results showed that the average plaque and gingival index values for the diabetic patients were significantly higher ($p<0.01$) than one of the control group. Poorly controlled diabetics also had significantly more plaque accumulations and gingival inflammation when compared with well-controlled diabetics group. CPI categories had different distributions among groups, with CPI0=16,67%, CPI1=40,0% , CPI2=36,7% , CPI3=6,7% for the controls and CPI0=8,3%, CPI1=23,3% , CPI2=31,7% , CPI3= 36,7% for diabetics. Candida was more prevalent in Diabetic group.

Conclusion: According to the results obtained, type 1 diabetes mellitus considerably affects periodontal health in adolescents. Poorer metabolic control may be a precipitating factor for increased oral colonization of Candida.

Key words: Type 1 diabetes mellitus, periodontal health, Candida

Introduction

Diabetes mellitus represents a group of metabolic diseases characterized by hyperglycemia due to a relative or absolute insufficiency of insulin secretion and/or concomitant resistance to the metabolic action of insulin on target tissues [1,2].

Type 1 diabetes (T1DM) is the result of an absolute insulin deficiency. This type of diabetes is usually diagnosed during childhood or early adolescence [3].

The classic micro- and macro-vascular complications associated with diabetes include retinopathy, neuropathy, nephropathy, cardiovascular complications and delayed wound healing [4]

The oral complications of T1DM include xerostomia, periodontal disease (gingivitis and periodontitis), dental abscesses, tooth loss, soft tissue lesions and burning mouth syndrome. [5]. Periodontal diseases were considered as the sixth most prevalent complication of diabetes mellitus following other diabetic complications [6].

Several mechanisms have been proposed to explain the increased susceptibility of diabetic patients to periodontal disease, including alterations in host response, subgingival microflora, collagen metabolism, vascular and gingival crevicular fluid, as well as compromised neutrophil function, decreased phagocytosis and leukotaxis [7].

There is emerging evidence to support the existence of a two-way relationship between diabetes and periodontitis, with diabetes increasing the risk for periodontitis, and periodontal inflammation negatively affecting glycaemic control [8]. That is, particularly if glycaemic control is poor, diabetes is associated with an increased prevalence and severity of periodontitis, and, severe periodontitis is associated with compromised glycaemic control [9].

It is also frequently claimed that uncontrolled glycemia predisposes to a variety of local and systemic infections. Oral candidiasis is known to be more prevalent among diabetic patients, with the course of infection being more complicated than in healthy individuals [10]. Candida is a normal commensal in the oral cavity, but during hyperglycemic episodes, the environmental alteration in the oral cavity may occur, such as: immune dysfunction, increased salivary glucose and acid production favour, the transition of the harmless commensal to a pathogen [11].

Available literature evidence on the oral health status of children and adolescents with type 1 diabetes suggest that they are at increased risk of developing periodontal disease at an early age. The only study that assesses correlation between glycemic control and periodontal health in B&H population is the study of Dedić [12] which was performed among adult patients in 1994. Our study was conducted to provide information on possible influence of T1DM on periodontal health in adolescents in the Sarajevo Canton area.

Metabolic control of the disease in the study was assessed by the mean values of glycated haemoglobin A1c (HbA1c), which is widely used marker of chronic glycaemia, reflecting average blood glucose levels over a 2- to 3-month period of time. The test plays a critical role in the management of the patient suffering from diabetes, since it correlates well with both microvascular and, to a lesser extent, macrovascular complications and is used as the standard biomarker for the adequacy of glycaemic management [13,14].

The aim of our study was to evaluate the association of T1DM, as well as of metabolic control of the disease, with the periodontal health and Candida carriage in diabetic adolescents.

Material and Methods

This prospective study was conducted in the Public Institution for Health Care of the Sarajevo Canton from January 2014 to February 2015.

Ethical considerations

The study design was approved by Ethical Committee of Faculty of Dentistry, University of Sarajevo. The nature and purpose of the research was presented to the parents/guardians of all individuals participated in the study, who then signed a consent form. At the end of the research, all patients received dental treatment.

Individuals

The study sample consisted of 90 school adolescents aged 12-18 years, who reside in the area of the Sarajevo Canton, divided into two groups: d*iabetic group (D)* and a *control group (C).*

Group D consisted of 60 patients who had been diagnosed with T1DM according to the diagnostic protocol of Endocrinology Department of Pediatric Clinic in Sarajevo, at least two years before.

This group of individuals was further divided into two subgroups each comprising of 30 persons, according to their glycemic control: subgroup D1 consisted of patients with well controlled glycaemia (HbA1c⩽ 7%); whereas subgroup D2 consisted of patients with poorer metabolic control, with HbA1c>7% [13,14]. These data were obtained from patient medical records.

The recruitment of the individuals was done at the Endocrinology Department in the period from January 2014 to February 2015. All the consecutive patients of the corresponding age were handed written information about the study, and the invitation for dental examination. We were able to recruit a total of 30 patients with poorer metabolic control (subgroup D2) who matched inclusion criteria and agreed to participate in the study. They were scheduled for the dental examination at the Dental Department of the Public Institution for Health Care of the Sarajevo Canton. As well, 30 consecutively attending individuals with well controlled glycaemia (subgroup D1), who accepted to participate in the study and matched the criteria, were scheduled for the examination. The inclusion criteria were: age from 12-18 years, written parental consent and those being diagnosed with T1DM at least 2 years earlier. Individuals were excluded for the following criteria: undergoing active orthodontic therapy, having professionally applied topical fluorides in the previous 6 months, using antibiotics and/or oral antiseptics in the previous 2 weeks.

The Control group (C), comprised of 30 age-matched healthy subjects not affected with any systemic diseases, as determined through medical history. This group consisted of the adolescents who were regular patients of Dental Department of the Public Institution for Health Care of the Sarajevo Canton. The inclusion criteria for controls were: age, parental consent, and no history of systemic illness, whereas the exclusion criteria were the same as those for the Diabetic group.

Dental examinations

Clinical examinations were performed at the Dental Department of Health Care of the Sarajevo Canton, by a single dentist, using straight dental mirror and World Health Organization (WHO) periodontal probe.

The level of oral hygiene was assessed by means of a plaque index (PI) and gingival index (GI), using scores 0-3, as described by Silness and Löe [15, 16]. The evaluation was performed on 6 index teeth: 16, 11, 26, 36, 31 and 46. Scores were recorded for 4 sites per tooth: mesial, distal, buccal, and lingual surface. Plaque quantity was assessed at the cervical tooth area.

The Community Periodontal Index (CPI) was used for periodontal evaluation. The same index teeth were used as for PI and GI. Three indicators of periodontal status were used for this assessment: bleeding gums, periodontal calculus and periodontal pockets. According to WHO recommendations, when examining adolescents under the age of 15, only bleeding gums and calculus were recorded to avoid falsely scoring deepened sulci due to eruption as periodontal pockets [17].

Candida sample collection and cultivation

After the dental examination, the samples were collected from the oral mucosa using sterile cotton swab and transported immediately to laboratory for microbiology analysis. Swab cultures were inoculated on Sabouraud dextrose agar (Difco Becton Dickinson, Franklin Lakes, NJ, USA) (SDA). Inoculated plates were incubated for 48 hours at 37°C. After that, the presence of Candida was confirmed by colony characteristics on SDA.

Statistical analysis

Data were analyzed using Microsoft Office XP Excel. Descriptive data were presented as Mean ± SD (standard deviation) or the percentages. The differences between groups were assessed by using the Student t-test. Differences were considered to be statistically significant at $p < 0.05$.

Results

The individuals enrolled in the study aged from 12 to 18 years. The mean age in Diabetic group was 15.8±1.79, while of those in Control group it was 15.2±1.99 respectively. Mean ages from subgroups D1 and D2 were 15.97±1.59 and15.63±1.99 respectively.

Average duration of illness in subgroup D1 was 8.87±3.13 year, while in subgroup D2 it was 8.37±3.12. This is not regarded as statistically significant difference.

Plaque index

The mean PI score was higher in the Diabetic group than in the Control group (diabetics subjects 1.60 ± 0.74; healthy subjects 0.87 ± 0.73), which was a significant difference (t=4.39, p<0.01). Also, significant difference was disclosed in mean PI score between well and poorly controlled diabetics (t=2.92, p<0.01) – namely; subgroup D2 subjects had a higher PI than those from subgroup D1(1.87± 0.73 versus 1.33±0.66, respectively).

Gingival index

Adolescents with diabetes had significantly more gingival inflammation than controls. Mean GI for the Diabetic group was 1.62±0.74, whereas for the Control group it was 0.87±0.78 (t=4.33, p<0.01). Distribution of of sites with gingival inflammation among diabetic and healthy subjects is shown in **Figures 1. and 2.**

The differences in mean GI remained significant between subgroups D2 and D1 as well (1.87±0.73 and 1.37±0.67 respectively; t=2.72, p<0.01).

CPI score

The proportion of subjects with a healthy periodontium in Control group was 16.67% versus 8.3% in Diabetic group. The most frequent CPI score in healthy adolescents was score 1 (bleeding on probing) and among diabetics score was 3 (periodontal pocket 4 - 5 mm). In subgroup D1, the most frequent finding was bleeding, as well as in healthy individuals, while 4-5mm periodontal pockets were mostly found in subgroup D2. **Table1.** shows distribution of CPI categories among groups in detail.

Candida carriage

Candida was isolated in 60.0% diabetic and in 43.3% healthy adolescents. Regarding metabolic control, this difference was considerable, with 73.3% positive yeast growth in poorly controlled patients and 46.7% in well controlled patients.

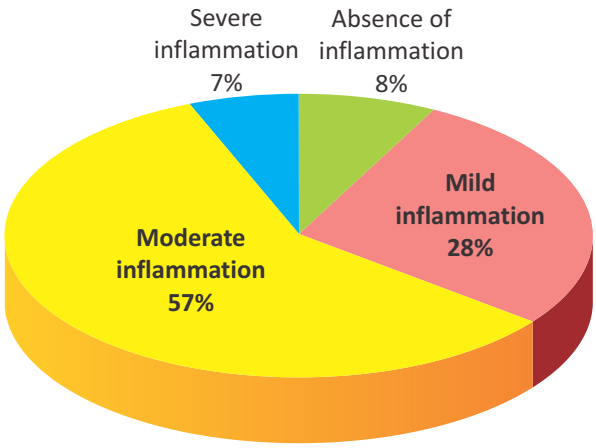

Figure 1. Distribution of sites with gingival inflamation in diabetic subjects

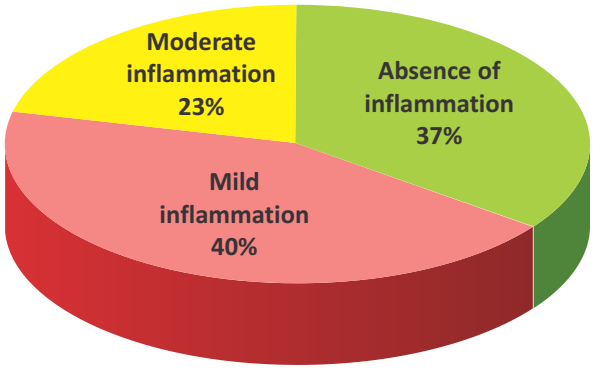

Figure 2. Distribution of of sites with gingival inflamation in healthy individuals

CPI score	Control group (%)	Diabetic group (%)	Subgroup D1 (%)	Subgroup I (%)
0	16,67	8,33	10,00	6,67
1	40,00	23,33	33,33	13,33
2	36,67	31,67	36,67	36,67
3	6,67	36,67	30,00	43,33

Table1. Distribution of CPI categories among groups

Discussion

Increased susceptibility to periodontal disease in diabetes patients has been subject of big interest for long time. Epidemiological studies have clearly identified that diabetes is a major risk factor for periodontitis, increasing the risk approximately three times compared to non-diabetic individuals, particularly if glycaemic control is poor [9]. The meta-analysis of Khader et al. [18] based on 23 comparative studies, demonstrated that diabetics had poor oral hygiene as measured by the average of PI, higher severity of the gingival disease as measured by the average of GI, and higher severity of periodontal disease. The most prevalent periodontal disease among children is gingivitis, and it usually becomes more severe in adolescence [19].

In our study Plaque index and Gingival index as described by Sillnes and Löe [15,16], and Community Periodontal Index [17] were used to assess the level of oral hygiene and periodontal health of diabetic and healthy adolescents.

According to results obtained, oral hygiene of controls can be categorized as good, while that of T1DM patients as fair [20]. Diabetics had significantly higher mean PI values than healthy adolescents regardless of metabolic control. The evidence that our study presents coincides with that of Aren et al. [21], which showed that both newly diagnosed diabetic patients and those with longer duration of the disease had significantly more plaque accumulations than healthy subjects. The study of Lalla et al. [22] also demonstrated that children with diabetes had significantly more dental plaque than non-diabetic control children, and when the percentage of sites that had visible plaque was calculated (plaque index >2) a significant difference was found again. Other studies [23,24,25] also revealed higher PI scores in patients with diabetes mellitus.

To the contrary, study of Tagelsir [26] disclosed no statistically significant difference in PI between diabetics and non-diabetics. Furthermore, in the study of Siudikiene [27], diabetics even had less plaque on their teeth, but significantly more calculus than controls.

Increased plaque accumulation could be explained by increased levels of glucose in the saliva and the gingival cervical fluid of diabetic patients, which enhances biofilm growth; as well as by the impaired salivary secretion, which prolongs oral clearance [28].

On the other hand, non-significant results might be attributed to regular follow up and the well-controlled metabolic level of the diabetic children [29], but also to the fact that the oral hygiene practice of diabetic patients may be similar to that of non-diabetic controls.

Multiple studies showed that children with diabetes had significantly more gingival inflammation than control children measured by GI [21,22,24,25,30], which corresponds with our results. This difference in our study remained significant between subgroups D2 and D1, mean GI values being higher in adolescents with poor metabolic control. In Lithuanian study [27], higher values of GI in poorly controlled subjects were also determined, although the differences were not statistically significant. Some studies showed no significant difference in GI between the T1DM patients and controls, as those of Luczaj [31] and Firatli [32].

In our study, 64% of diabetic subjects had mean GI scores 2 or 3, that denotes a bleeding site. Although this finding is an indicator of inflammation, it is possible that vascular changes in diabetes mellitus add to increased gingival bleeding [24]. Also, it has been shown that patients with T1DM mount an exaggerated gingival inflammatory response to a bacterial challenge compared to that found in non-diabetics [30], which might be one of the explanations for our results.

Considering CPI score results in our study, percentage of subjects with healthy periodontium was two times higher in Control than in Diabetic group, and furthermore, while periodontal pockets were registered in only about 7% healthy adolescents, the same score was found in almost 37% diabetic patients.

Earlier epidemiological study conducted on national and regional levels in Bosnia and Herzegovina among 15-year-old from Sarajevo [33] reported somewhat less favorable distributions of CPI categories (CPI0=18%, CPI1=38%, CPI2=28%, CPI3=14%, CPI4=1%) with larger proportion of individuals with registered periodontal pockets than in healthy ones in our study, but even so, our findings still present an indication of greater severity of periodontal disease in diabetic patients.

Study of Lalla [22] found that attachment loss, the hallmark of periodontitis, calculated as either a subject based mean, or as the number of affected teeth, was also significantly higher in diabetic children compared to non-diabetic control individuals. Similar results were presented by Firatli et al. [32].

Besides posing a risk to periodontal disease, diabetes is often considered a precipitating factor for increased oral colonization of Candida. This yeast is a normal commensal of the oral cavity but increased salivary glucose and acid production favor its transition to a pathogen [11]. In our study Candida was isolated in 43.3% of healthy adolescents, in 46.7% well controlled diabetics and in even 73.3% poorly controlled T1DM patients. A study comparing Candida carriage in adult diabetic patients [34] found positive growth of Candida colonies in 30% T1DM patients as opposed to only 7% in healthy individuals. The CFU/ml values in diabetics compared to controls were also significantly higher. In another study, 67.8% of diabetic patients and 50.4% of healthy individuals were Candida positive, and the difference was statistically significant [35]. Regarding metabolic control, Siudikiene et al. showed an inverse correlation of salivary microbial counts of Candida and the level of metabolic control of T1DM. Poorly controlled diabetics had significantly higher counts of yeasts, when compared to the group of well-to-moderately controlled diabetics [36].

Conclusion

The results presented in this study demonstrate that young patients with type 1 diabetes mellitus are more prone to periodontal disease, with higher severity exhibited in patients with poorer metabolic control. Furthermore, higher rate of isolation of Candida in diabetics implies potential for increased susceptibility to oral mucosal candidiasis.

In light of this findings it is clear that early oral screening of paediatric T1DM patients is necessary in order to timely prevent or stop further progression of periodontal disease and oral infection.

Conflict of interest

The authors declare no conflict of interest.

References

1. Al-Maskari AY, Al-Maskari MY, Al-Sudairy S. Oral manifestations and complications of diabetes mellitus. A review. Sultan Qaboos Univ Med J. 2011;11(2):179-86.
2. Garber A. Diabetes mellitus. In: Stein JH, editor. Internal Medicine. 5th Ed. Vol. 1. St Louis: Mosby; 1998. p. 1850–4.
3. Loghmani E. Diabetes mellitus: type 1 and type 2. In: Stang J, Story M, editors. Guidelines for adolescent nutrition services. Minneapolis, MN: Center for Leadership, Education and Training in Maternal and Child Nutrition, Division of Epidemiology and Community Health, School of Public Health, University of Minnesota; 2005. p. 167-82.
4. Ismail AF, McGrath CP, Yiu CK. Oral health of children with type 1 diabetes mellitus: a systematic review. Diabetes Res Clin Pract. 2015; 108(3):369-81.
5. Carneiro VL, Fraiz FC, Ferreira Fde M, Pintarelli TP, Oliveira AC, Boguszewski MC. The influence of glycemic control on the oral health of children and adolescents with diabetes mellitus type 1. Arch Endocrinol Metab. 2015;59(6):535-40.
6. Löe H. Periodontal disease: The sixth complication of diabetes mellitus. Diabetes Care 1993; 16:329–34.
7. Ship JA. Diabetes and oral health: An overview. J Am Dent Assoc 2003;134:4S-10S.
8. Preshaw PM, Alba AL, Herrera D, Jepsen S, Konstantinidis A, Makrilakis K, Taylor R. Periodontitis and diabetes: a two-way relationship. Diabetologia. 2012 Jan;55(1):21-31.
9. Casanova L, Hughes FJ, Preshaw PM. Diabetes and periodontal disease: a two-way relationship. Br Dent J. 2014 Oct;217(8):433-7. doi: 10.1038/sj.bdj.2014.907.

10. Tekeli A, Dolapci I, Emral R, Cesur S. Candida carriage and Candida dubliniensis in oropharyngeal samples of type-1 diabetes-mellitus patients. Mycoses 2004; 47: 315–318.

11. Balan P, B Gogineni S, Kumari N etal.Candida Carriage Rate and Growth Characteristics of Saliva in Diabetes Mellitus Patients: A Case–Control Study. J Dent Res Dent Clin Dent Prospects. 2015; 9(4):274-9. doi: 10.15171/joddd.2015.048.

12. Dedić A. Korelacija između visine glikoziliranog hemoglobina HbA1c i promjena na parodontu i drugim organima kod pacijenata sa diabetes mellitusom-tip1. Doktorska disertacija, Univerzitet u Sarajevu; 1994.

13. International Expert Committee. International Expert Committee report on the role of the A1C assay in the diagnosis of diabetes. Diabetes Care. 2009;32:1327-34.

14. American Diabetes Association. Diagnosis and classification of diabetes mellitus. Diabetes Care. 2012;35(Suppl 1):S64-71.

15. Silness J, Löe H. Periodontal disease in pregnancy II. Correlation between oral hygiene and periodontal condition. Acta Odontol Scand 1964; 22:121-35.

16. Löe H, Silness J. Periodontal disease in pregnancy I. Prevalence and severity. Acta Odontol Scand 1963;21:533-51.

17. World Health Organization. Oral Health Surveys: Basic Methods,4th ed. Geneva: World Health Organization;1997.

18. Khader YS, Dauod AS, El-Qaderi SS, Alkafajei A, Batayha WQ. Periodontal status of diabetics compared with nondiabetics: A meta-analysis. J Diabetes Complications 2006;20:59-68.

19. Nakagawa S, Fujii H, Machida Y, Okuda K: A longitudinal study from prepuberty to puberty of gingivitis. Correlation between the occurrence of Prevotella intermedia and sex hormones. J Clin Periodontol 1994;21:658– 665.

20. Marya CM. Dental indices. In: Marya CM, editor. A textbook of public health dentistry. New Delhi : Jaypee Brothers Medical Publisher; 2011. p.185-211.

21. Aren G, Sepet E, Ozdemir D, Dinccag N, Guvener B, Firatli E. Periodontal health, salivary status, and metabolic control in children with type 1 diabetes mellitus. J Periodontol 2003;74(12):1789–95.

22. Lalla E, Cheng B, Lal S, Tucker S, et al. Periodontal changes in children and adolescents with diabetes: a case-control study. Diabetes Care. 2006; 29(2):259-99.

23. Lopez del Valle LM, Ocasio-Lopez C. Comparing the oral health status of diabetic and non-diabetic children from Puerto Rico: a case–control pilot study. P R Health Sci J. 2011;30:123-27.

24. Orbak R, Simsek S, Orbak Z, Kavrut F, Colak M. The influence of type-1 diabetes mellitus on dentition and oral health in children and adolescents. Yonsei Med J. 2008;49(3):357-65.

25. Dakovic D, Pavlovic MD. Periodontal disease in children and adolescents with type 1 diabetes in Serbia. J Periodontol 2008;79:987–92. doi: 10.1902/jop.2008.070549

26. Tagelsir A, Cauwels R, van Aken S, Vanobbergen J, Martens LC. Dental caries and dental care level (restorative index) in children with diabetes mellitus type 1. Int J Pedriatic Dent. 2011;21(1):13-22. doi: 10.1111/j.1365-263X.2010.01094.x.

27. Siudikiene J, Maciulskiene V, Dobrovolskiene R, Nedzelskiene I. Oral hygiene in children with type I diabetes mellitus. Stomatologija. 2005;7(1):24-7.

28. Siudikiene J, Machiulskiene V, Nyvad B, Tenovuo J, Nedzelskiene I. Dental caries increments and related factors in children with type 1 diabetes mellitus. Caries Res. 2008 ;42(5):354-62. doi: 10.1159/000151582.

29. Sbordone L, Ramaglia L, Barone A, Ciaglia RN, Iacono VJ. Periodontal status and subgingival microbiota of insulin-dependent juvenile diabetics: a 3-year longitudinal study. J Periodontol. 1998; 69(2):120–8.

30. Al-Khabbaz AK, Al-Shammari KF, Hasan A, Abdul Rasoul M. Periodontal health of children with type 1 diabetes mellitus in Kuwait: a case–control study. Med Princ Pract. 2013;22(2):144-9. doi: 10.1159/000342624.

31. Luczaj-Cepowicz E, Marczuk-Kolada G, Waszkiel D. Evaluation of periodontal status in young patients with insulin-dependent diabetes mellitus (type 1). Adv Med Sci. 2006;51 (Suppl 1):134-7.

32. Firatli E. The relationship between clinical periodontal status and insulin-dependent diabetes mellitus. Results after 5 years. J Periodontol. 1997;68(2):136–40.

33. Marković N, Arslanagić-Muratbegović A, Kobašlija S, Bajrić E, Selimović-Dragaš M, Huseinbegović A. Caries prevalence of children and adolescents in Bosnia and Herzegovina. Acta Med Acad. 2013;42(2):108-16.

34. Shenoy MP, Puranik RS, Vanaki SS, Puranik SR, Shetty P, Shenoy R. A comparative study of oral candidal species carriage in patients with type1 and type2 diabetes mellitus. J Oral Maxillofac Pathol. 2014;18:S60-5. doi: 10.4103/0973-029X.141361.

35. Zomorodian K, Kavoosi F, Pishdad GR, Mehriar P, Ebrahimi H, Bandegani A, Pakshir K. Prevalence of oral Candida colonization in patients with diabetes mellitus. Journal De Mycologie Médicale. 2016; http://dx.doi.org/10.1016/j.mycmed.2015.12.008

36. Siudikiene J, Machiulskiene V, Nyvad B, Tenovuo J, Nedzeiskiene I. Dental caries and salivary status in children with type 1 diabetes mellitus related to the metabolic control of the disease. Eur J Oral Sci. 2006; 114: 8–14.

CORRELATION BETWEEN PSYHOACTIVE SUBSTANCE ABUSE AND PERIODONTAL ALTERATION

Hadžić S.*[1], Gojkov-Vukelić M.[1], Pašić E.[1], Šečić S.[2]

[1] Department of Oral Medicine and Periodontology, Faculty of Dentistry, University of Sarajevo, Sarajevo, Bosnia and Herzegovina
[2] Department of Oral Surgery and Dental Implantology, Faculty of Dentistry, University of Sarajevo, Sarajevo, Bosnia and Herzegovina

***Corresponding author**

Sanja Hadžić, PhD
Faculty of Dentistry,
University of Sarajevo
Bolnička 4a, 71000 Sarajevo
Bosnia and Herzegovina
Phone: +387 33 210 683
e-mail : shadzic@sf.unsa.ba

ABSTRACT

Introduction: The World Health Organization has defined drugs or psychoactive substances as all substances of natural or synthetic origin which, when introduced into the organism, may alter one or many various bodily functions, and which, after repeated use, may lead to development of a mental or physical addiction. In oral cavities of drug addicts, drug addiction may induce direct or indirectly caused alterations. Incidence of periodontal diseases is higher among drug addicts than among those who do not consume psychoactive substances.

Objective: Evaluate the effect of psychoactive substances among persons with alcohol and opiate addiction on the level of oral hygiene and periodontal alteration.

Materials and Methods: The sample consisted of 60 subjects of both sexes, from 18 to 60 years of age, divided into 2 groups: Group A: subjects addicted to psychoactive substance - alcohol, and Group B: subjects addicted to psychoactive substance - opiates. Following an extensive anamnesis and clinical examination of the mucosa, periodontal examination was performed. Plaque index and gingival bleeding index were used for quantification of periodontium.

Results and Conclusions: Data obtained by clinical examination was statistically processed: oral hygiene, plaque index, gingival index, and presence of gingivitis and periodontitis in psychoactive substance abusers. Statistical analysis confirmed ($p = 0.00397$) a higher incidence of periodontal disease in alcohol-dependent patients (60%), compared to opiate addicts (23%). Regardless of age, type of psychoactive substance, or length of substance abuse, there is a correlation between the abuse of psychoactive substances (drugs) and periodontal alterations.

Key words: psychoactive substances (opiates, alcohol), periodontal diseases, oral hygiene.

Introduction

Dependence on psychoactive substances is currently a leading social and health problem worldwide. The World Health Organization has defined drugs or psychoactive substances as all substances of natural or synthetic origin which, when introduced into the organism, may alter one or many various bodily functions 1, 2.

Drugs are natural or synthetic substances that may cause alterations or disorders of one or more somatic or mental functions, and are used in medical or non-medical purposes. Drugs are divided into hard and soft drugs. Hard drugs cause severe mental and physical dependence (heroin, cocaine). Soft drugs have a moderate potential for psychological dependence, and a small risk of physical dependence. These include alcohol, amphetamines, nicotine, hallucinogens, caffeine, marijuana (hashish), organic solvents, and others 3, 4.

Psychoactive substance can enter a body in several ways: orally (alcohol, tablets), by smoking, inhalation (marijuana, cocaine, opium), sniffing (cocaine, heroin), subcutaneously, and intravenously (heroin, cocaine). Psychoactive substances (drugs) have a major impact on oral health. Oral alterations depend on the type of drug. Incidence of caries, periodontal diseases, and fungal infections is higher among drug addicts than among those who do not consume psychoactive substances.

Alterations in the oral mucosa are not pathognomonic for those addicted to psychoactive substances, but the following may be observed: Cheilitis angularis, Candidiasa mucosae oris, Glossitis rhombica mediana, Gingivostomatitis ulceromembranacea, Gingivitis catharalis, Linear gingival erythema, Parodontitis agresiva, Lingua nigra villosa, Leukoplakia, Hyperceratisis mucousae oris, Stomatitis aphthosis recurrens (SAR), Erosiae mucosae oris, Herpes simplex, Morsicatio mucosae oris, caries, bruxism, and other 5, 6. In patients addicted to psychoactive substances (alcohol, opiates), immunosuppression of the immune system is observed, giving rise to an increased incidence of opportunistic infections. Patients who use methamphetamine display the so-called "Meth mouth", characterized by: poor oral hygiene, xerostomia, caries, gingivitis, and aggressive periodontitis (AGP) 7.

Research done by many authors points to the interdependence between psychoactive substance (drugs) intake, length of addiction, and types of drugs, and poor motivation for oral hygiene and periodontal disease. Mc Grath, *et al.* (2005) examined the influence of amphetamines on oral health, and the most common diseases they recorded were: rapid caries, reminiscent of nursing caries, decaying tooth surface, aggressive periodontitis, and oral candidiasis, probably caused by xerostomia, toxic effects of drugs, and poor oral hygiene.

Angular cheilitis, oral candidiasis, and gingival lacerations are often observed in cocaine addicts (Brunnswich 2005), while patients addicted to alcohol more frequently display severe periodontitis 8, 9. Numerous oral, periodontal, and dental diseases occur with an increased incidence in the group of psychoactive substance abusers. Periodontal diseases can be an initial or secondary symptom of AIDS; hence, the importance of symptomatology is preventive and therapeutic 10.

Aim of this research is to evaluate the effect of psychoactive substances among persons with alcohol and opiate addiction on the level of oral hygiene and periodontal alteration.

Materials and methods

The study included 60 patients who were hospitalized at the Institute for Alcoholism and Substance Abuse of Canton Sarajevo, who have provided their consent to participate in this research. They are divided into two groups: Group A – alcohol addicts, and Group B - opiate addicts; both sexes were included and the participants were 18 to 60 years of age (**Figure 1,2**).

Extensive anamnesis was carried out prior to clinical examination. All anamnestic data and observed pathological alterations were noted in a working chart specifically designed for the purpose of this study. The chart records data on the types of psychoactive substance used by the patient, commencement of substance intake, and duration of addiction. Clinical examination included an extraoral (assessment of exterior appearance, constitution, examination of the head and neck), and intraoral examination (examination of the labial mucosa, cheeks, palate, tongue, floor of the mouth, periodontium, and teeth) (**Figures 3, 4, 5, 6, 7, 8**).

Figure 1.
Alcohol addict with carious teeth, plaque, and periodontitis

Figure 2.
Opiate addict with decayed crowns, carious teeth, and periodontitis

Figure 3.
Examination of the lips

Figure 4.
Examination of the tongue

Figure 5.
Examination of the buccal mucosa

Figure 6.
Caries profunda, gingivitis catarrhalis

Figure 7.
Linear gingival erythema

Figure 8.
Parodontitis agressiva

Periodontium is a functional organ composed of gingiva, periodontal ligament, alveolar bone, and cementum. Gingiva is the only visible part of periodontium. During the clinical examination of the gingiva, we observed its size, shape, colour, and consistency. We used the Pitting-test (verification of oedema or gingival hyperplasia) to estimate the size of the gingiva.

The following indices were used for quantification of periodontium:

Plaque index (Silness and Löe)

0: No plaque on tooth, scraping the neck of the tooth produces no plaque on the end of the probe;

1: No plaque on tooth, but scraping the neck of the tooth produces plaque;

2: Plaque is visible on tooth;

3: Tooth contains a lot of plaque;

Plaque index was used to quantify the presence of dental biofilm (plaque) on teeth.

Gingival bleeding index (Löe and Silness)

0: Change in colour, shape, and size of gingiva not observed, no inflammation;

1: Colour of gingiva changed, blunt pressure does not cause bleeding, mild inflammation;

2: Blunt pressure causes gingival bleeding, moderate inflammation;

3: Gingiva bleeding spontaneously, significant erythema, hypertrophy, ulcerations, severe inflammation.

Normal and pathological conditions of the gingiva are quantitatively expressed using gingival index.

Results

The study included 60 patients of both sexes, aged 18-60 years, addicted to alcohol (Group A) and opiates (Group B), with various degrees of periodontal alteration.

State of oral hygiene is a reflection of the general habits of psychoactive substance abusers to tooth brushing.

Table 1 shows the frequency (percentage) of tooth brushing in examined groups, and in total.

Chi-square test ($p = 0.0021$) has confirmed that there are significant differences in the frequency of tooth brushing in groups. In Group A, 12 patients (40.00%) do not brush their teeth, while of 24 patients (80.00%) in Group B brush their teeth once or twice a day.

Table 2 shows the frequency (percentage) of plaque index in examined groups, and in total.

In Group A, 20 patients had plaque index 2, 8 patients had plaque index 3, and only 1 patient had plaque index 1. In Group B, 18 patients had plaque index 2, 6 patients had plaque index 3, and 6 patients had plaque Index 1. Chi-square test ($p = 0.30256$)

	1 time per day		2 and more times per day		Occasionally		Does not brush	
	n	%	n	%	n	%	n	%
Group A	5	16,67	6	20,00	7	23,33	12	40,00
Group B	5	16,67	19	63,33	4	13,33	2	6,67
Total	10	16,67	25	41,67	11	18,33	14	23,33

Table 1.
Frequency of tooth brushing

Plaque index	Index 1		Index 2		Index 3	
	n	%	n	%	n	%
Group A	2	6,67	20	66,67	8	26,67
Group B	6	20,00	18	60,00	6	20,00
Total	8	13,33	38	63,33	14	23,33

Table 2.
Plaque index frequencies

confirmed that there are no significant differences in frequencies of plaque index in groups. 38 patients (63.33%) had plaque index of 2. In Group A, 20 patients (66.67%) had index 2, while there were 18 such patients (60.00%) in Group B.

Table 3 shows the frequency (percentage) of gingival index in examined groups, and in total.

Chi-square test ($p = 0.68990$) confirmed that there are no significant differences in frequencies of gingival index in groups. 31 patients (51.67%) had gingival index 1. In Group A, 15 patients (50.00%) had index 1, and there were 16 such patients (53.33%) in Group B. Index 2 was determined in 23 patients (38.33%), of which 11 patients (36.67%) in Group A, and 12 patients (40.00%) in Group B.

Plaque index	Index 1		Index 2		Index 3	
	n	%	n	%	n	%
Group A	15	50,00	11	36,67	4	13,33
Group B	16	53,33	12	40,00	2	6,67
Total	31	51,67	23	38,33	6	10,00

Table 3.
Gingival index frequency

Chelitis	None		Plaquosa		Catarrhalis		Hyperplasia		Total
	n	%	n	%	n	%	n	%	
Group A	17	56,67	5	16,67	7	23,33	1	3,33	30
Group B	20	66,67	5	16,67	4	13,33	1	3,33	30
Total	37	61,67	10	16,67	11	18,33	2	3,33	60

Table 4. Frequency of gingivitis by groups

	Has periodontitis		Does not have periodontitis		Total
	n	%	n	%	
Group A	18	60,00	12	40,00	30
Group B	7	23,33	23	76,67	30
Total	25	41,67	35	58,33	60

Table 5. Frequency of periodontitis in groups

Table 4 shows the frequency (percentage) of occurrence by type of gingivitis, in groups.

Gingivitis catarrhalis was present in 23.3% of patients in Group A, and 13.3% patients in Group B. Gingivitis plaquosa was recorded in 16.67% of patients in both Group A and B. Chi-square test ($p = 0.78639$) confirmed that there are no significant differences in frequency according to the type of gingivitis in groups. Most common in both groups were gingivitis plaquosa with 10, and catarrhalis with 11 patients. Linear gingival erythema was recorded only in 4 patients (13.33%) from Group B.

Table 5 shows the frequency (percentage) of occurrence of periodontitis in examined groups, and in total.

Chi-square test ($p = 0.00397$) confirmed that there are significant differences in the frequencies of occurrence of periodontitis in groups. In Group A, 18 patients (60.00%) had periodontitis, while there were 7 such patients (23.33%) in Group B. It is evident that the group of alcohol addicts has clinically validated periodontitis at the rate of 60%.

Discussion

Alcohol and opiate abuse is harmful to general and oral health. In recent years, pathological aspect of substance abuse on dental and oral tissues has been the subject of research by many authors because of the increased number of young addicts.

One of the major causes of periodontal disease is low motivation of addicts to maintain good oral hygiene. Patients in our sample, regardless of their age were, not motivated for maintenance of good oral hygiene, particularly the participants in Group A (alcohol addicts). In Group A (alcohol addicts), 12 patients (40%) do not brush their teeth at all, while 24 patients (80%) in Group B (drug addicts) brush their teeth once or twice a day. Supplemental products for oral hygiene are not used by 85% of patients.

Due to poor oral hygiene, patients had a high frequency of plaque and cavities, and had periodontal diseases (gingivitis and periodontitis) due to the

absence of immunological components of salivary and gingival fluid 11.

Psychoactive substances, or drugs, destroy the internal structure of the teeth, and alcohol helps the release of fluoride from certain nutrients thus affecting the lower incidence of caries. In his study, Harris (2010) confirmed that a group of drug addicts had a higher incidence of caries ($p < 0.5$) 1.3 (25) than in the group of alcohol addicts 0.95 (1.7), and that the understanding of the true effect of psychoactive substances on dental health is the subject of further research. In 2007, it was estimated that about 22.3 million Americans aged 12 years were classified as addicted to some type of psychoactive substance 12. Khockh (2009) examined the periodontium of 102 patients (addicts), mean age 41 years, using plaque index and gingival index. The results showed that there is a correlation between the frequency of tooth brushing and plaque levels. Post-hoc analysis showed that in the group of non-alcoholics, those who brushed their teeth once or twice a day had less plaque and fewer cavities 13.

Alcohol addicts have poorer oral hygiene, high plaque index, and prevalence of periodontal diseases, which was confirmed by Araujo (2004), who recorded 47.7% of alcohol addicts and 61.8% of smokers in his sample of 34 patients. Prevalence of dental disease was 82%, and 70% of patients had plaque index 3 14, 15.

Our results are consistent with the results of the aforementioned authors, confirmed by 2 patients (6.7%) in Group A who had plaque index 1, 20 patients (67%) in the same group had plaque index 2, and 8 patients (27%) had plaque index 3. In Group B, 6 patients (20%) had plaque index 1, plaque index 2 was found in 18 patients (60%), and plaque index 3 was observed in 6 patients (20%).

Chi-square test confirmed that there is a statistically significant difference in the occurrence of periodontitis between the groups. In Group A, 18 patients (60%) had clinically recorded periodontitis, compared to Group B, where periodontitis was identified in 7 patients (23%).

Psychoactive substances - in our sample, alcohol and opiates - have had a great influence on the incidence of periodontal disease. By their chemical composition, psychoactive substances have directly influenced the emergence of diseases. Low level of oral hygiene, poor motivation, and lack of and education influenced the increased adherence of plaque, and were correlated with the occurrence of dental diseases 16.

Conclusions

Patients addicted to psychoactive substances are not motivated to maintain oral hygiene. Alcohol addicts do not maintain proper oral hygiene in 40% of cases.

Correlation between substance abuse (alcohol, opiates) and alteration of periodontium (gingivitis and periodontitis) has been confirmed.

A significantly higher incidence of periodontal disease in patients who are addicted to alcohol (60%), compared to patients addicted to opioids has been demonstrated.

References

1. Cerić I, Mehić Basara N i sar. Zloupotreba psihoaktivnih supstanci i lijekova. Medicinski fakultet Univerziteta u Sarajevu 2007.
2. The World Health Report. Media Information. WHO Geneva 2001.
3. Health in the European Union. Health and Consumer Protection. Report on the State of Young Peoples. European Comission 2000.
4. Studija ispitivanja znanja i stavova vezanih za zloupotrebu droga kod djece i omladine u Kantonu Sarajevo. Zavod za javno zdravstvo Kantona Sarajevo: Sarajevo 2001.
5. Sinanović O. Posljedice zloupotrebe psihoaktivnih supstanci po tjelesno zdravlje korisnika u : Sinanović O. (urednik) Ovisnost o drogama/uzroci i posljedice prevencija i liječnje. Behrambegova medresa i Medicinski fakultet:Tuzla 2002;45-70.
6. Mehić Basara N, Cerić I, Hasečić H. Plan and Program of fighting drug abuse in Federation of Bosnia and Herzegovina;13 th International Conference of Reduction of Drug Related Harm. Ljubljana 3-7 March, 2002; Ljubljana Slovenia.
7. Hamamoto DT, Rhodus NL. Methamphetamine abuse and dentistry. Journal Of Oral Disease. Shool of Dentistry University of Minnesota USA 2010;15:27 37.

8. Mc Grath C, Chan B. Oral health sensations associated with illicit drug abuse. Aust Dent J. 2005;198(3):159-62.

9. Brunswick M. Meth users can look forward to gumming their food. Chicago Sun Tim, January 10, 2005.

10. Jiantao Wang, Jian Lv, Wanchun Wang, Xiubo Jiang, *Alcohol consumption and risk of periodontitis: a meta-analysis,* Journal of Clinical Periodontology, 2016, 43, *7, 572*

11. Amanda P, Warmakulasuriya S. Tooth decay in alcohol abusers compared to alcohol and drug abusers. Journal of dentistry 2010.

12. Harris CK, Warnakulasurya KA et al. Prevalence of oral mucosal lesions in alcohol misusers in south London. J Oral Pathl Med 2004;33(59):253-9.

13. Khocht A et al. Dental care and oral disease in alcohol dependent person. Journal subs. Abuse Treat 2009;37(2):214-218.

14. Araujo MW, Dermen K, Connors G et al. Oral and health among in patients in treatment for alcohol use disordes: pilot study. J Int. Acad Periodontol 2004;6(4):125-30.

15. Forner L, Larsen T, Kilian M, Holmestrip P. Incidenca of bacteremia after chewing, tooth brushing and scaling in individuals with periodontalis inflammation. Journal of clinical Periodontology 2006;138:227-230.

16. Susin C, Wagner MC, Haas AN, Oppermann RV, Albandar JM. The association between alcohol consumption and periodontitis in southern Brazilian adults. J Periodontal Res 2015 Oct; 50(5): 622-8.

THE RANGE OF MAXIMUM MOUTH OPENING IN PARTIALLY EDENTULOUS PATIENTS WITH SYMTPOMS OF TEMPOROMANDIBULAR JOINT DYSFUNCTION

Strujić-Porović S.[*1], Ajanović M.[1], Kazazić L.[1], Berhamović L.[1], Đonlagić A.[1], Kamber-Ćesir A.[1]

[1] Department of Prosthodontics, Faculty of Dentistry, University of Sarajevo, Sarajevo, Bosnia and Herzegovina

***Corresponding author**

Sanela Strujić - Porović, Ph.D
Department of Prosthodontics
Faculty of Dentistry
University of Sarajevo
Bolnička 4a
71 000 Sarajevo
Bosnia and Herzegovina
Phone: + 387 (61) 144 350
e-mail: sanelastrujic@yahoo.com

ABSTRACT

Objective: The objective of this research was to determine the range of active maximum mouth opening and the condylar position in partially edentulous patients with and without symptoms of temporomandibular joint dysfunction.

Subjects and Methods: The sample consists of partially edentulous patients with (30) and partially edentulous patients without symptoms of temporomandibular joint dysfunction (30). In all patients involved in the research a case history was taken accompanied by a detailed clinical intro-oral and extra-oral examination. The range of active maximum mouth opening was measured as a maximum distance between the incisal edges of the upper and lower central incisors at mid-line. Radio-graphs of the right and left temporomandibular joint in the position of the maximally opened mouth were taken using the Ortopantomograph OP 100, program 6. On the obtained radio-graphs the analysis of condylar position in relation to the top of articular eminence and the linear measurements were performed.

Results: Partially edentulous patients with symptoms of temporomandibular joint dysfunction had a higher range of maximum mouth opening ($p<0.008$) and the condyles significantly more in front of the top of articular eminence in the sagittal plane ($p<0.001$) compared to the partially edentulous patients without symptoms of temporomandibular joint dysfunction.

Conclusion: Partially edentulous patients with symptoms of temporomandibular joint dysfunction had a higher range of maximum mouth opening and temporomandibular joint hypermobility in comparison to partially edentulous patients without symptoms of temporomandibular joint dysfunction.

Key words : range of maximum mouth opening, temporomandibular joint hypermobility, condyle position.

Introduction

The range of maximum mouth opening is considered as one of the parameters to evaluate the function of temporomandibular joint (TMJ) and the status of masticatory musculature [1]. The maximum mouth opening (MMO) shows a great variability because it is related to age, gender, antropometric characteristics, height, weight, race, size of mandible, but also the size of the cranial base [2,3,4]. Both excessive and reduced mandibular movement can show the signs and symptoms of the muscular and TMJ dysfunction. Maximum mouth opening in patients with myogenous problems is reduced but in patients with anterior disc discplacement with reduction is similar to those without symptoms and signs of temporomandibular disorders (TMD) [1,5].

Patients with the condylar hypermobility showed wide range of mouth opening with an greater interincisal distance [5]. Previous studies have shown that a higher condylar translation may be related to the disc displacement with reduction and symptoms of TMJ dysfunction [6,7]. The findings of magnetic resonance have shown that in patients with the symptoms of clicking and pain in the area of TMJ, and also with the pain at palpitation of masticatory muscles and the condyle position considerably in front of the articular eminence, there exist structural and pathological changes in the lateral pterygoid muscle. These changes play an important role in the occurrence of clinical symptoms [8]. Because of great variability in the range of active maximum mouth opening (MMO) in asymptomatic patients, the diagnostic value of this parameter in patients with the symptoms of TMJ dysfunction is questionable [9]. Therefore, the objective of this research was to determine the range of active maximum mouth opening and the condyle position in partially edentulous patients with and without symptoms of TMJ dysfunction.

Subjects and methods

The research included the patients who came to the Department of Prosthodontics at the Faculty of Dentistry University of Sarajevo. The research was approved by the Ethical Committee of the Faculty of Dentistry. Partially edentulous patients (60) of either gender, aging from 40 to 60, with the eugnathic jaw relationship were included in the study. Patients without upper and lower anterior teeth, prosthetic rehabilitated patients with crowns on the anterior teeth, patients with abrasion of teeth, tumors in the facial area have been excluded from the research. A medical history of each patient was taken, clinical examination was carried out as well as TMJ radiographs at the maximum mouth opening.

The patients in this study were divided according to the presence of clinical symptoms and signs of TMJ dysfunction: pain in the TMJ area, painful reciprocal clicking, painful terminal clicking, deviation and deflection of the mandible, headache, ringing and tinnitus into the experimental group – partially edentulous patients with the symptoms of TMJ dysfunction (30) and the control group – partially edentulous patients without symptoms of TMJ dysfunction (30). The measurements were taken with patients in the upright position who were given instructions to maximally open their mouth three times as much as possible.

The biggest interincisal distance was recorded as a referential value. The range of active maximum mouth opening was measured as a maximum distance between the incisal edges of the upper and lower central incisors at mid-line without the overbite by using a millimeter ruler. The TMJ radio-graphs in the position of maximum mouth opening were taken by using Ortopantomograph® OP100, Instrumentarium Imaging (Finland), program 6. The lead apron, covering the back, shoulders and the upper thorax, were used as a protection of patients against irradiation.

The patient's head was positioned by light lines so that his mediosaggital plane was directed to the floor while its Frankfurt plane was parallel to the floor. In the medial line an appropriate nasal support was placed. A temporomandibular pointer placed in line with the external auditory canal was used to adjust the direction of focal beam to TMJ. At this the patient's head was fixed in cephalostat by a semi ring holder in the area of the forehead. On the obtained radio-graphs of both TMJs at the maximum mouth opening linear measurements of the range of articular surfaces in the sagittal and vertical planes were carried out.

The range was measured between the two marked points, ie. point A on the top of the articular eminence as an anterior border of the upper articular surface of mandibular fossa and point C on the top of the lower articular surface (**Figure1.**). The results of all measu-

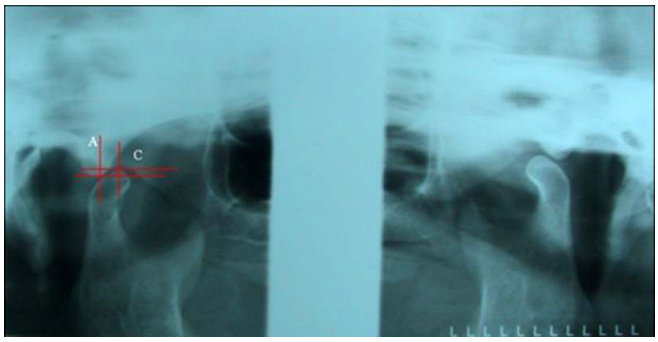

Figure 1.
X –ray of TMJ at maximum mouth opening.
A – Top of the articular eminence
C – Top of the lower articular surface.

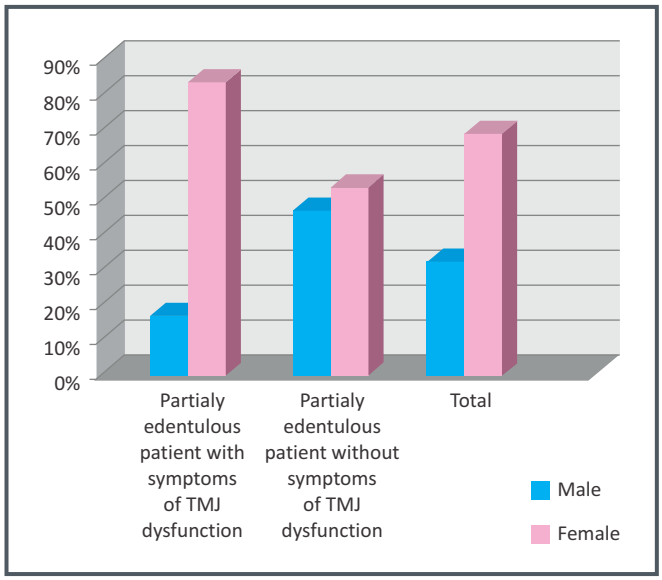

Figure 2. Percentage of partially edentulous patients by gender.

	Range of maximum mouth opening (mm)	
	Experimental group	Control group
Interval	40-60	40-50
N	30	30
Mean	48.700	45.667
SD	5.730	2.758
SE	1.046	0.504
Median	50	45
Mann-Whitney Rank Sum Test	**p = 0.008**	

N – number ; SD- standard deviation; SE- standard error

Table 1. Range of maximum mouth opening in partially edentulous patients with and without symptoms of TMJ dysfunction.

rements were statistically analyzed by using the standard methods of descriptive statistics. Statistically significant differences between the two groups were evaluated by using *Mann-Whitney Rank Sum test, t-test and Chi-square test*. The significance level was $p < 0.05$.

Results

Out of the total of 60 partially edentulous patients 19 (32%) were males, while 41 (68%) were females. In the group of partially edentulous patients with the symptoms of TMJ dysfunction females were prevalent (83%) compared to males (17%). In the control group there were 53% of female subjects and 47% of male subjects (**Figure 2.**).

The difference with regards to gender between the examined groups was statistically significant ($p<0.05$). In partially edentulous patients with the symptoms of TMJ dysfunction the mean of maximum mouth opening was 48.700 mm (± 5.730) with minimum and maximum mouth opening 40 and 60 mm, while in partially edentulous patients without symptoms of TMJ dysfunction it amounted to 45.667 mm (± 2.758).

By statistical analysis it was established that there is a statistically significant difference between the examined groups at the level of probability $p = 0.008$ (**Table 1.**).

At the maximum mouth opening the difference in the condyle position between the right and left TMJ in the sagittal and vertical planes is neither statistically significant in the experimental group ($p=0.252$ and $p=0.308$) nor in the control group ($p=0.535$ and $p=0.250$). At the maximum mouth opening in partially edentulous patients with the symptoms of TMJ dysfunction, the lower articular surface was on average 6.400 mm (± 4.029) in front of the top of articular eminence in the sagittal plane, while in partially edentulous patients without symptoms of TMJ dysfunction it amounted to 3.933 mm (± 2.883). By analysis, it was established that there is a highly significant difference in values ($p<0.001$) (**Table 2.**). The difference in the position of the lower articular surface superior to the top of articular eminence in the vertical plane between the experimental group (3.107 mm ± 1.720) and the control group (2.511 mm ±1.237) was not statistically significant ($p=0.127$) (**Table 3.**) (**Figure 3.**).

	Maximum open mouth	
	Right and left TMJ Sagital plane Experimental group	Right and left TMJ Sagital plane Control group
Interval	1-18	0.5-12
N	60	60
Mean	6.400	3.933
SD	4.029	2.883
SE	0.520	0.372
Median	6	3
Mann-Whitney Rank Sum Test	**p < 0.001**	

N – number ; SD- standard deviation; SE- standard error

Table 2. The position of the lower articular surface in front of the top of articular eminence in partially edentulous patients with and without symptoms of TMJ dysfunction.

	Maximum open mouth	
	Right and left TMJ Vertical plane Experimental group	Right and left TMJ Vertical plane Control group
Interval	0.5-3	1-4
N	42	44
Mean	3.107	2.511
SD	1.720	1.237
SE	0.265	0.186
Median	3	2.5
Mann-Whitney Rank Sum Test	**p = 0.127**	

N – number ; SD- standard deviation; SE- standard error

Table 3. The position of the lower articular surface superior f rom the top of articular eminence in partially edentulous patients with and without symptoms of TMJ dysfunction.

Discussion

Maximum mouth opening is an important diagnostic parameter in the evaluation of patients with temporomandibular disorders (TMD). Limited mouth opening can be a result of extracapsular or intracapsular disorders [1,10] while increased maximum mouth opening is commonly an argument in diagnosing TMJ hypermobility [11,12], namely, subluxation. The previous research has shown a wide range of MMO values in asymptomatic subjects, from 40-60 mm, and depending on many factors, age, gender, race, ethnic origin, differences in body size, facial morphology, size of mandible, position of head [2,13-15]. The average of MMO value in Americans amounts to 48.8 mm [13], in Chinese 49.10 mm [14], in Croats 49.89 mm [16], in Irish 42.2 mm [3], in French 50.77 mm [17]. In this study, patients without symptoms of TMJ dysfunction had MMO value ranging from 40-50 mm, the average being 45.66 mm.

Patients with the symptoms and signs of TMJ dysfunction and condylar hypermobility showed wide range of mouth opening with an interincisal distance greater than 4 cm [5]. The findings of this research have shown that partially edentulous patients with the symptoms of TMJ dysfunction and condylar hypermobility had a significant higher range of maximum mouth opening in relation to partially edentulous patients without symptoms (p=0.008) (**Table 1. and 2.**). In comparison to our findings Kitsoulis et al. (2011) found a statistically significant difference

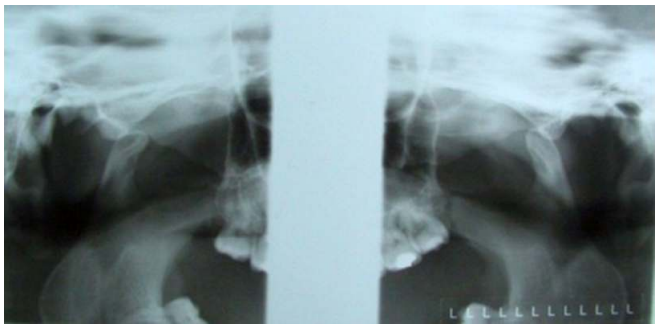

Figure 3. X- Ray of patient with symptoms of TMJ dysfunction.

(p<0.05) in the average value of MMO between those with symptoms (44.45 mm, SD 6.11) and asymptomatic ones (46.45 mm, SD 7.16) [18].

Also, Čelić et al. found a higher value of MMO in asymptomatic persons (50.8 mm) in relation to those with TMD (48.4 mm), but the difference was statistically significant only between asymptomatic persons and the persons with symptoms of muscular disorders and disc displacement with reduction. The authors concluded that this data did not have a clinical significance because they were in the range of "normal" MMO values [19]. In our research the average MMO values in both groups of individuals are also in the range of ''normal'' values. These differences in MMO values in asymptomatic persons and those with symptoms in our research and the previous ones could be accounted for by the age difference of persons, gender influence, condylar hypermobility, great inter-individual variation, antropometric characteristics, overbite of incisors included in the MMO values along with a different methodology of measurement.

Contrary to our findings, Casanova et al. (2012) did not find a statistically significant difference in the average value of MMO between asymptomatic persons and those with symptoms such as miofacial pain and dislocation of the articular disc [2]. Gallagher et al. found that there were no apparent differences in mean maximum opening between the group with symptoms (TMJ "abnormal") and group without symptoms of TMJ dysfunction (TMJ "nor-mal") [3].

Sawair et al. (2010) found that there was a weak but significant negative correlation between the active maximum mouth opening and the number of lost teeth [20]. Sarita et al. state that a statistically significant correlation between shortened dental arch and symptoms and signs of TMD does not exist. Only the complete absence of posterior occlusal support increases a risk of TMD development [21].

The range of maximum mouth opening is used as an indirect assessment of TMJ mobility while a more direct measurement is determined by the evaluation of condylar translation and the condyle position in relation to the top of articular eminence both clinically and radiographically [22]. The results of this research have shown that in partially edentulous patients with symptoms of TMJ dysfunction at the maximum mouth opening, in the sagittal plane, the condyles are found considerably higher in front of the articular eminence in relation to asymptomatic patients ($p<0.001$) (Table 2.). In the vertical plane, the difference in the condyle position between the examined groups was not statistically significant (**Table 3.**). Patients with symptoms of TMJ dysfunction who had condyles considerably higher in front of the top of articular eminence had a statistically significant higher values of the range of the MMO in relation to patients without symptoms, which is in accordance with the findings of Juce et al. and Stegenge et al. [12,22].

Gallagher et al. did not find a correlation between the reduced mouth opening and TMJ dysfunction which corresponds to our findings [3]. Muto et al. have found a significant correlation between the MMO range and the condyle position in front of the top of articular eminence in the sagittal plane, while the correlation was not significant in the vertical plane [23]. Obwegeser et al. showed that this correlation did not exist [24]. Kalaykovom et al. indicate that the condylar position itself is not an indicator of symptomatic hypermobility of condyle [25]. In the absence of symptoms subluxation of TMJ is to be considered as variation of the normal [26] as it is a case with the individuals in the control group. Nevertheless, condyle hypermobility causes acute and chronic trauma of the joint structure and associated muscles and ligaments, and it is one of the etiological factors of TMJ disorder and the occurrence of clinical symptoms [27].

Females show a higher degree of TMJ hypermobility and TMD symptoms in relation to males [28], which can be explained by a higher degree of TMJ hypermobility in the experimental group with the prevalent presence of females compared to the control group. The relationship between the symptoms of TMJ dysfunction and condylar hypermobility was also confirmed by Şener et al. [29], Katzberg et al. [6], Kavucun et al. [30]. The loss of teeth, accompanied by chronic subluxation can later develop into a recurrent TMJ dislocation [31].

Conclusion

Partially edentulous patients with symptoms of temporomandibular joint dysfunction had a higher range of maximum mouth opening and temporomandibular joint hypermobility in comparison to partially edentulous patients without symptoms of temporomandibular joint dysfunction.

References

1. Miller VJ, Bookhan V, Brummer D, Singh JC. A mouth opening index for patients with temporomandibular disorders. J Oral Rehabil. 1999; 26:534-538.
2. Casanova –Rosado JF, Medina Solis CE, Casanova –Rosado AJ, Vallejos- Sánchez AA, Patiño- Marín, Maupome G, Gomez-Gomez V. Clinical characterization of mouth opening among Mexican adolescents and yang adults. J Dent Sci. 2012;7:81-4
3. Gallagher C, Gallagher V, Whelton H, Cronin M. The normal range of mouth opening in an Irish population. J Oral Rehabil. 2004; 31(2) : 110-116.
4. Dijekstra PU, de Bond LG, Stegenga B, Boering G. Angle of mouth opening measurement: reliability of a technique for temporomandibular joint mobility assessment. J Oral Rehabil. 1995; 22:268-8.
5. Eberhard D,Bantleon HP, Steger W. Functional magnetic resonance imaging of temporomandibular joint disorders. European Journal of Orthodontics. 2000;22(5):489-97.
6. Katzberg RW, Keith DA, Guralnick WC, Ten Eric WR. Correlation of condilar mobility and arthrotomography in patients with internal derange-

ments of the temporomandibular joint. Oral Surg Oral Med Oral Pathol Oral Radiol Endod. 1982; 54(6):622-7.

7. Holmlund AB, Gynther GW, Kardel R, Axelsson SE. Surgical treatment of temporomandibular joint luxation. Swed Dent J.1999;23(4):127-32.
8. Yang X, Pernu H, Phytien J. et al. MRI Findings Concerning the Lateral Pterygoid Muscle in Patients with Symptomatic TMJ Hypermobility. J Craniomand Pract. 2001;19(4):261-8.
9. Hochstedler JL, Allen JD, Follmar MA. Temporomandibular joint range of motion: a ratio of interincisal opening to excursive movement in a healthy population. Cranio. 1996;14(4): 296 -300.
10. Dworkin SF, LeResche L, DeRouen T, Von Korff M. Assessing clinical signs of temporomandibular disorders: reliability of clinical examiners. J Prosthet Dent. 1990; 63(5):574-9.
11. Maruyama T, Kotani M, Ozaki H, Sumida N, Akanishi M, Kuroda T. A study on the condylar position of temporomandibular joint in the dysfunction of the stomatognathic system using tomography. J Osaka Univ Dent Sch. 1984; 24:89-96.
12. Juca FK, Suazo Galdames IC, Guimarães AS. Mandybular condyle position in maximum mouth opening. A magnetic resonance imaging evaluation. Int J Morphol. 2009;27(3):867-71.
13. Zawawi KH, Al-Badawi EA, LoboSL et al. A index for measurement of normal maximum mouth opening. J Can Dent Assoc. 2003;69(11):737-41.
14. Yao KT, Lin CC, Hung CH. Maximum mouth opening of ethnic Chinese in Taiwan. J Dent Sci. 2009; 4(1):40-44.
15. Visscher CM, Huddleston Slater JJ, Lobbezoo F, Naeije M. Kinematics of the human mandible for different head postures. J Oral Rehabil. 2000;27: 299-305.
16. Celic R, Jerolimov V, Knezovic D: Relationship of slightly limited mandibular movements to temporomandibular disorders. Braz Dent J. 2004; 15(2):151-154.
17. Placko G, Bellot-Samson V, Brunet S, Guyot L, Richard O, Cheynet F, Chossegros C, Ouaknine M: Normal mouth opening in the adult French polulation. Rev Stomatol Chir Maxillofac. 2005; 106:267-71.
18. Kitsoulis P, Marini A, Iiiou K, Galani V, Zimps A, Kanavaros P, Paraskevas G. Signs and symptoms of temporomandibular joint disorders related to the degree of mouth opening and hearing loss. Ear, Nose nd Throat Disorders. 2011; 11:5.
19. Čelić R, Jerolomov V, Knezović Zlatarić D, Klaić B. Measurements of mandibular movements in patients with temporomandibular disorders and asymptomatic subjects. Coll.Antropol. 2003; 27 Suppl 2:43-49.
20. Sawair FA, Hassoneh YM, Al-Zawawi BM, Baqain ZH. Maximum mouth opening. Associated factors and dental significance. Saudi Med J. 2010; 31(4): 369-73.
21. Sarita PTN, Kreulen CM,Witter DJ, Creugers NHJ. Signs and Symptoms Associated with TMD in Adults with Shortened Dental Arches. Int J Prosthodont. 2003;16(3): 265.
22. Stegenga B, de Bont L.G.M, de Leeuw R, Boering G. Assesment of mandibular function impairmant associated with temporomandibular joint osteoarthrosis and internal derangement. J Orofac Pain. 1993; 7:183.
23. Muto T, Kohara M, Kanazawa M, Kawakami J.The position of the mandibular condyle at maximal mouth opening in normal subjects. J Oral Maxillofac Surg. 1994; 52(12):1269-72.
24. Obwegeser HL, Farmand M, Al-Majali F, Engelke W. Findings of mandibular movement and position of the mandibular condyles during maximal mouth opening.Oral Surg OralMed Oral Pathol 1987; 63 (5):517-25.
25. Kalaykova S, Naeije M, Huddleston Slater JJ, Lobbezoo F. Is condylar position a predictor for functional signs of TMJ hypermobility? J Oral Rehabil. 2006;33(5): 349-55.
26. Caminiti MF, Weinberg S. Chronic Mandibular Dislocation: The role of Non-Surgical and Surgical Treatment. J Canad Dent Assoc.1998; 64(7): 483-91.
27. Hong L, Zhou J, Hong M. The use of panoramic radiograph to observe abnormal movement of condyle. Zhonghua Kou Qiang Yi Xue Za Zhi. 1997;32(2):92-4.
28. Barrera-Mora JM, Espinar Escalona E, Abalos Labruzzi C, Llamas Carrera JM, Ballesteros EJ, Solano Reina E, Rocabado M.The relationship between malocclusion, benign joint hypermobility syndrome, condylar position and TMD symptoms. Cranio. 2012 Apr;30(2):121-30.
29. Sener S, Akgüniü F. Correlation of Diffeent MRI Characteristics of Anterior Disc Dispacement With Reduction and Without Reduction. J Contem Dent Pract. 2005;6(1):26- 36.
30. Kavucun V, Sahin S, Kamanli A,Karan A, Aksov C. The role of systemic hypermobility and condylar hypermobility in the temporomandibular joint dysfunction syndrome. Reumato Int. 2006; 26(3): 257-60.
31. Shorey CW, Campbell JH. Dislocation of the temporomandibular joint. Oral Surg Oral Med Oral Pathol Oral Radiol Endod. 2000; 89:662-8.

ANALYSIS OF CONCORDANCE BETWEEN CLINICAL AND RADIOGRAPHICAL DEPTH OF OCCLUSAL CARIES LESIONS – A PILOT STUDY

Bajsman A.*[1], Haračić A.[2], Vuković A.[1], Zukić S.[1]

[1] Department for Dental Morphology, Dental Anthropology and Forensic Dentistry, Faculty of Dentistry, University of Sarajevo, Sarajevo, Bosnia and Hercegovina
[2] Public Health Care Center, Kakanj, Bosnia and Herzegovina

***Corresponding author**

Anita Bajsman, Ph.D
Faculty of Dentistry
Bolnička 4a
71000 Sarajevo
Bosnia and Herzegovina
Tel: +387 33 214 249 (239)
e-mail: abajsman@sf.unsa.ba

ABSTRACT

Aim: The aim of the study was to investigate the influence of complexity of occlusive morphology on radiographic detection of occlusive caries lesions, and to analyze the reliability of radiography in dentistry.

Material and methods: A sample of this study consisted of 40 teeth (20 molars and premolars 20), shown in 33 digital retrocoronal radio-graphs. Carious lesion depth was known for each tooth, measured clinically, using graduated probe, and after cavity opening and removal of carious masses. Lesion depth measurements on digital radio-graphs were performed using ImageJ software. Obtained values (clinical and software) were correlated and analyzed by Microsoft Office Excell 2007 and IBM SPSS Statistics 20.0.0.

Results: Analysis of obtained results shows that clinical depth value is higher compared to measurements of radiolucent zone on digital radiographs, in most cases. There are very few matched results of clinical and software measurements. Measurements on molars of total sample show concordance in 15% of cases. Measurements on premolars of total sample show concordance in 25% of cases. Discrepancies of measurements results are not large, but are present in 80% of the sample.

Conclusion: The complexity of the occlusive morphology is one of the main reasons for difficult radiological diagnosis of occlusive caries lesions. Different occlusive relief, rich and various fissure systems, the presence of filling materials, the superposition of lip and lingual enamel represent reasons why radiography is not able to clearly demonstrate the existence and exact boundaries of propagation of carious lesions.

Key words: occlusal morphology, caries diagnosis, digital radiography.

Introduction

Epidemiological studies recorded a decline prevalence of smooth surfaces dental caries since the early 1970's. The main contribution to the decrease smooth surface caries has been given by the increased use of fluoride in the last 40 years. Occlusive cavitations currently create the majority of new lesions in dental younger "post - fluoride" generation. Today, clinicians believe that the use of fluoride slowed up the progress of occlusive carious lesions, and at the same time "strengthened" the enamel so that the sound of probing of the occlusive surface may obscure relatively large carious lesions in dentin. There are many terms used in literature to describe this phenomenon, such as "occult", "hidden", "secret" caries or even "fluoride syndrome" [1].

With the reduction of smooth surface dental caries there has been increase in the number of primary carious lesions in pits and fissures. The prevalence of caries in premolars and molars depend on the occlusal morphology. Due to the existence of prominent and depressed parts forming such a complex occlusive relief, there are numerous micro-spaces that represent an ideal "hidden" habitat for pathogens where they are protected from mechanical removal and possibility of being washed off by saliva [2, 3].

The diagnosis of early caries lesion is of great importance because it enables timely action towards stopping the progression of existing lesions and encourages the process of remineralization. Today, in daily practice, caries diagnosis is most commonly performed using visual - tactile method and radiography. This is why it is important to evaluate the reliability of this diagnosis method.

There are wide areas of indication for dental x-ray, for purpose of getting new diagnostic or therapeutic information. Despite the existence of many benefits of radiological methods in dentistry, there are certain disadvantages. Radiography is unable to conclusively distinguish occlusive lesions with and without cavitations. In practice, only one-third of the initial occlusive caries lesions are correctly diagnosed radiologicaly, until the lesions that progressed in dentin minimally are properly recognized in two thirds of cases. The reasons for difficult radiographic diagnosis of occlusive caries lesions could be found in the complex occlusive morphology and frequent presence of filling materials. Also, due to the superposition of the lips and lingual enamel, caries lesions of occlusive enamel are not clearly visible and the beginning of dentinal decay is difficult to determine [4, 5, 6, 7].

Radiography underestimates lesion depth. In vitro experiments have shown that when the occlusive lesion is clearly visible on the radiograph, demineralization reached up to or beyond the middle third of dentin. The effectiveness of radiological diagnosis of caries lesions depends on good quality of image. Radio-graphs are not always able to show caries in its earliest stages, and besides that they have additional restrictions, with the risk of false positive and false negative diagnosis. Variations among observers in the interpretation of images are also a limitation [6].

In recent times, due to widespread use of digital radiography, every effort is made in order to improve this diagnostic method. There are numerous advantages of digital systems over conventional radiography, and among the most important are: reduced dose of ionizing radiation; the shorter time between exposure and display of the image on a PC monitor; presumed smaller number of repeated recordings and mistakes (errors on conventional radiographs are considered to be due to wet film processing); wider dynamic range; facilitating the provision of information to the patient, because the patient is able to see the image on the monitor - that helps the understanding of the treatment plan; and save images in computer files which saves space and allows you to transfer recordings electronically. Also, the possibility of image post-processing, offered by digital systems, is of great importance. Pixel value can be changed by applying mathematical operations thus changing certain characteristics of the image with possibility to displaying it clearer and allowing the practitioner to easier identification of details. Software is available to enable the practitioner such processing [8].

Evidence suggests, although this is far from making a final conclusion, that some digital radiographic methods allow better sensitivity, compared to conventional radiography, both on proximal and occlusive surfaces [9].

Pereira et al [10] consider that there is no difference in the accuracy of post processed digital radiographic images with manipulated contrast and brightness, and those on which post-processing was not done. In addition, dentists are able to use post-processing of digital images very differently. If post-processing is not used properly, it can reduce

diagnostic accuracy, and additional research is needed in this regard. Results of Pereira et al indicate that digital radiographic techniques are accurate in detecting occlusive caries lesions as much as conventional techniques.

Rapid technological progress is in favor of developing and improving diagnostic systems in dentistry, with the ultimate goal of achieving possibilities of computer diagnosis to be correct and accurate.

Materials and methods

This study was approved by the Ethical Committee of Faculty of Dentistry, University of Sarajevo, decision number 09-545-4/11.

The study involved patients who applied to the Department of Dental Pathology and Endodontics, Faculty of Dentistry, University of Sarajevo. The inclusive criteria were the presence of at least one fully erupted molar and / or premolar in the dental arch, with occlusive surfaces with different degrees of primary caries lesion, without the presence of restorations and materials for fissure sealing. Teeth with lesions in the oral, vestibular and proximal surfaces were excluded, as well as teeth with set orthodontic rings, developmental anomalies, teeth with pathological abrasion and other structural defects, teeth with any intrinsic or extrinsic discoloration. Research procedure is described in detail to every examine, and each respondent gave written informed consent.

For all teeth that fulfilled the inclusion criteria, clinical examination has been performed, as well as laser fluorescence examination, and digital retrocoronal radiographs were made. If two of the three diagnostic methods confirmed the presence of caries lesion, the cavity was opened and the carious masses were removed. After that, clinical depth of caries lesion was measured by graduated probe, and obtained data were recorded in research chart.

The study sample consisted of 40 teeth, 20 molars and premolars 20, shown at 33 digital radio-graphs. Clinical depth of caries propagation was known for each tooth, expressed in millimeters.

Digital radiography

For exposure, analysis and processing of images X-ray machine De Götzen xgenus® digital (De Götzen S. r. l. Via Roma, 45 – 21057 Olgate Olona (VA) – Italy, software version 1.30.113) was used. Xgenus® digital system uses CCD sensor. For radiovisiographic recording in this study sensor size 1 was used, and the recording was performed in low resolution (LR) mode.

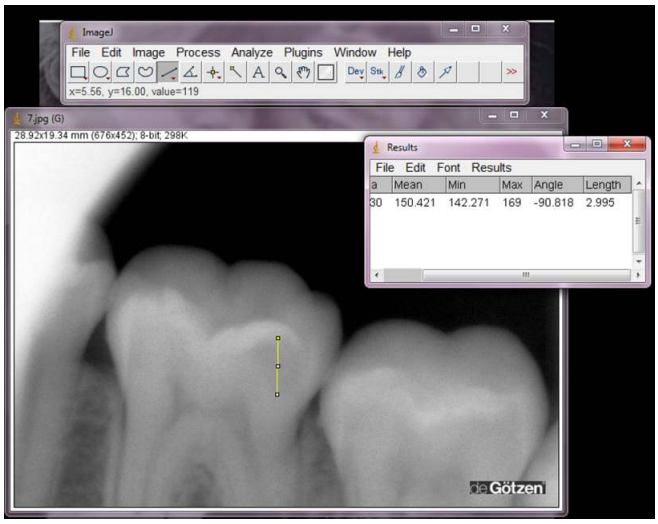

Picture 1. Measurement in ImageJ software

All digital radio-graphs were analyzed as native and post-processed. Different software tools were used optionally, and most frequently the ones enable the improvement of the contrast and brightness of the image. Post-processing procedure facilitates the identification and measurement of small depth carious lesions to a large extent.

ImageJ software

Measurements of the depth of caries lesions on the occlusive surfaces of the teeth, or measurement radiolucent zone in the radio-graphs were performed using ImageJ software (NIH, Maryland, USA), after calibration, and expressed in millimeters (**Picture 1**.)

Results

Considering the entire sample of 40 teeth, concordance in results in both variables existed in 20%of cases, whilst discrepancies existed in 80% of cases. Two cases of 0 value in radiographic measurement were included in discrepancies – lesions were not noticable on radiographs. The existence of these

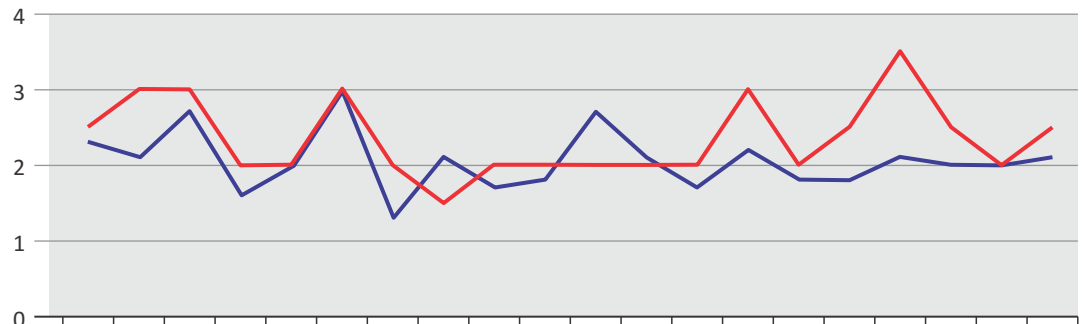

	1	2	3	4	5	6	7	8	9	10	11	12	13	14	15	16	17	18	19	20
Radiographic measurement	2,3	2,1	2,7	1,6	2	3	1,3	2,1	1,7	1,8	2,7	2,1	1,7	2,2	1,8	1,8	2,1	2	2	2,1
Clinical measurement	2,5	3	3	2	2	3	2	1,5	2	2	2	2	2	3	2	2,5	3,5	2,5	2	2,5

Figure 1 The values of clinical depth of caries lesion measured by graduated probe, and the values obtained by measuring the area of radiolucent zone corresponding to the carious lesion on radiographs using ImageJ, in molars of total sample

lesions was clinically observed, and their depth, in both cases, was 1 mm. Possible reasons for the inability to observe these lesions could be the existence of errors in the exposition, which resulted in imprecise recording, small depth of lesions, which are still in the enamel, or subjectivity of interpreter of radiograph.

Figure 1. clearly illustrates noticeably higher values of clinical measurements compared to radiographic measurement in molars of total sample. Concordance of results is present in only 15% of cases. Also, higher valuse of radiographic measurements, compared to clinical measurements were recorded in 15% of cases. The remaining 70% of cases recorded higher values of clinical measurements.

Figure 2. presents evidently higer values of clinical measurements, compared to radiographic measurements in premolars of total sample. However, the difference between variables in premolars is lower than in molars. In 25% of cases there is a concordance of results of clinical and radiographic measurements, i.e. 10% higher than in molars. Higher values of clinical measurements were ob-

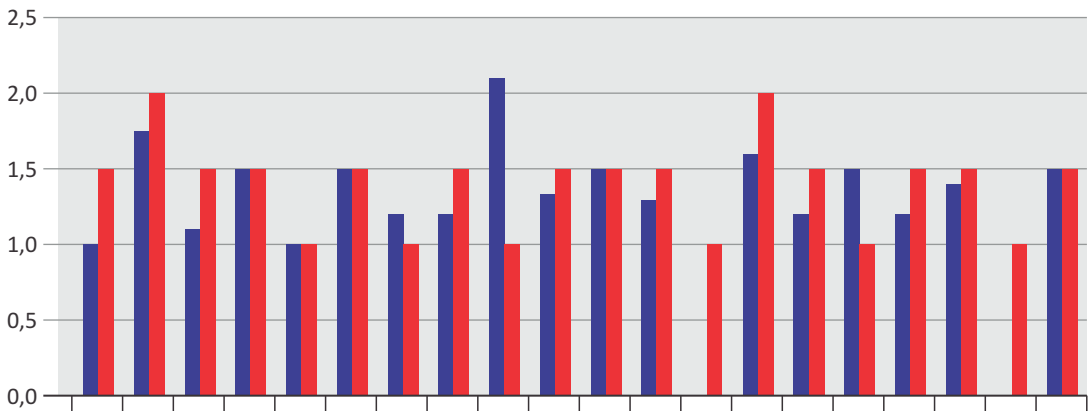

	1	2	3	4	5	6	7	8	9	10	11	12	13	14	15	16	17	18	19	20
Radiographic measurement	1	1,7	1,1	1,5	1	1,5	1,2	1,2	2,1	1,3	1,5	1,3	0	1,6	1,2	1,5	1,2	1,4	0	1,5
Clinical measurement	1,5	2	1,5	1,5	1	1,5	1	1,5	1	1,5	1,5	1,5	1	2	1,5	1	1,5	1,5	1	1,5

Figure 2. The values of clinical depth of caries lesion measured by graduated probe, and the values obtained by measuring t he area of radiolucent zone corresponding to the carious lesion on radiographs using ImageJ, in premolars of total sample

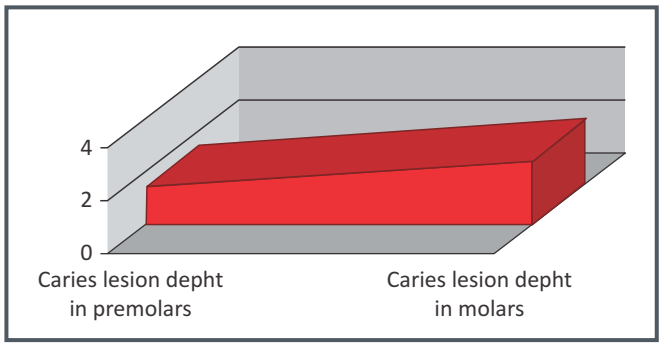

Figure 3. The depth of carious lesions in premolars and in molars of total sample

			Clinical measurement
Spearman's rho	Clinical measurement	Correlation coefficient	1.000
		Sig. (2-tailed)	.
		N	40
	Radiographic measurement	Correlation coefficient	.492**
		Sig. (2-tailed)	.001
		N	40

** Correlation is significant at the 0.01 level (2-tailed).

Table 1. Spearman's correlation coefficient

served in 55% of cases. Higher values of radiographic measurements were recorded in 10% of cases, while in 10% of cases false negative result occurred, i.e. lesions were not seen on radiographs and measured result was 0, but the existence of lesions was proven clinically, and measured depths are equal (1mm).

Figure 3. clearly shows that the lesion depth is higher in molars compared to premolars. Deeper carious lesions facilitated the assessment of the same on the radio-graphs. When evaluating the results, it was noted that in all radio-graphs, molar lesions were visible and it was possible to perform measurement, contrary to specific cases of lesions in premolars that are clinically recorded (at the level of the enamel) and that could not be seen on the radio-graphs even after post-processing. The cases of non recording enamel lesions are mostly influenced by the complexity of occlusal morphology, and due to the superposition of enamel, smaller depth lesions failed to be seen clearly in radio-graphs.

Table 1. shows the Spearman correlation coefficient at the confidence level of $p < 0.01$ for the tested variables. This value shows a weak correlation between clinical and radiographic value of caries lesion depth in tested sample.

T - Test (**Table 2.)** showed that there is no statistically significant correlation between clinical and radiographic value of caries lesion depth in tested sample, at the level of significance $p \leqslant 0.05$

Independent Samples Test		Levene's Test for Equality of Variances		T-test for Equality of Means						
		F	Sig.	t	df	Sig. (2-tailed)	Mean Difference	Std. Error Difference	95% Confidence Interval of the Difference	
									Lower	
RVG Values	Equal variances assumed	6.356	.023	-3.158	16	.006	-.8667	.2744	-1.4484	
	Equal variances not assumed			-2.437	5.880	.052	-.8667	.3557	-1.7412	

Table 2. T - test of total sample

Discussion

The morphology of the occlusive surfaces or three-dimensional appearance of the fissure system affects the formation of occlusive caries. Salman [11] in his research of the impact of occlusive morphology on the severity of occlusive caries points out that there is a statistically significant correlation at the level $p \leqslant 0.001$.

Valera et al [2] state that there is no statistically significant difference between the premolars and molars related to the presence or absence of pits and fissures. Both in premolars and molars caries prevalence depends on the occlusive morphometry, with a higher prevalence when the pits and fissures are present. Analyzing the results of the study we can conclude that the occlusive surfaces of molars are largely destroyed with caries lesions than it is the case with premolars. A complex occlusive surface of molars enables retaining debris. Due to the presence cusps and fissures, food remains are harder removal mechanically, which favors the metabolic processes in the biofilm. However, premolars are in a slightly better position in the dental arch in relation to the molars. Their position allows easier implementation of oral hygiene, preventive measures and self-cleaning tooth surfaces compared to molars, which prevents longer retention of biofilm and development of caries lesion.

According to several studies (Carvalho et al 1989, Ekstrand et al 1995) caries lesion usually begins in the central fissure. On the other hand, following a series of studies, carious lesions were mainly detected in the pits and fissures (Gustafson, Nagano i König) [2].

However, both groups of researchers agree that the beginning and progression of carious lesion is in connection with macro morphology of occlusive surface.

There is no doubt that the complexity of the occlusive surface favors the development of carious lesions and also constitutes an aggravating circumstance for adequate and timely diagnosis. Reviewing the literature and analyzing the results of various studies [12], we found statements that are proven in this study. It is concluded that the efficacy of clinical method is similar to radiographic methods, with clinical methods having a lower number of false - negative results compared to the radiographic method.

Da Silva et al [13] compared the accuracy of direct digital radiography with conventional radiography in the analysis of occlusive caries in primary molars. Taking into account the sensitivity and specificity, the study showed that direct digital radiography has a similar level of accuracy as conventional radiography. Visual inspection showed greater accuracy of both radiographic methods when it comes to occlusive caries lesions in the enamel, and digital radiography had a similar effect as conventional radiography and visual inspection for dentinal lesions. These results correlate with the results of this study. We had several clinically diagnosed and measured lesions (enamel lesions) which were not visible, or were hardly visible on radio-graphs, after post-processing. When it comes to lesions in dentin, they are clearly observed on radio-graphs, and there is less discrepancy in values of clinical and radiographic depth.

The results of this study show that radiovisiographs underestimate the depth of carious lesions. It is evident that in most cases the values of clinical measurements of carious lesions are higher compared to the measurements of radiolucent zone in radiographs. There are very few matching values obtained by clinical measurement and measurement on digital radiographs. Discrepancies in measurements could be explained by subjective observation during measurement. There is also the possibility of error due to post-processing of digital radiographs. Discrepancies of the measurement results are not large, but they are present in 80% of the sample.

There are cases in this study where it was not possible to observe lesions on digital radiographs. The existence of these lesions was clinically proven and they were measured using graduated probe, and recorded depth in both cases was 1 mm. The reason for the inability to observe these lesions may be the possible existence of errors in the exposition, which resulted in imprecise recording, small depth of lesions, which are still in the enamel, or subjectivity in interpreting digital radiographs.

In a study that compares two digital radiography systems and conventional radiography in the diagnosis of occlusive and proximal caries, Da Rocha et al [14] point out that there is no significant difference between the digital systems (Digora® i DenOptix®) and conventional films in diagnosis of occlusive caries. It is also concluded that there are significant variations between examiners. In this study, a group of examiners was made up of students, and slight

variations have been reported within this group, with levels of 0.43 to 0.55. However, comparing the values obtained by the students with another group of examiners made up of radiologists, significant variations were observed, with levels of 0.28 to 0.54. This outcome supports the statement that, in the interpretation of images, significant factor is the subjectivity of each examiner.

Conclusions

The depth of occlusive caries lesion is noticeably higher in molars comparing to premolars. Larger depth of caries lesion facilitates its coping and assessment in digital radio-graphs. Digital radio-graphs underestimate the depth of carious lesions. There are very few matches of clinical measurements of caries lesion depth using graduated probe, and measurements on digital radio-graphs, using ImageJ software. Discrepancies of results are not large, but are present in 80% of cases. Difficult radiological diagnosis of occlusive caries lesions is justified by rich relief of occlusive surface, with various elements superimposed on radio-graphs, as well as possible presence of filling materials. Radiography is a valuable diagnostic tool. Although there is still no perfect way to diagnose using radiography, it is believed that, due to the rapid and unstoppable progress of technology in medicine, we are on the right track towards finding the ideal radiographic diagnostic system.

Declaration of interest

Authors declare no conflict of interest.

References

1. Burrow MF, Burrow JF, Makinson OF. Pits and fissures: etch resistance in prismless enamel walls. Australian Dental Journal. 2001;46(4):258 – 262.
2. Valera F et al. Morphometric analysis of the occlusal surface: the influence on the prevalence of carious lesions. Salusvita 2005;24:301-308.
3. McComb D, Tam LE. Diagnosis of Occlusal Caries: Part I. Conventional Methods. Journal of Canadian Dental Association 2001;67(8):454 – 457.
4. Bloemendal E, de Vet HCW, Bouter LM. The value of bitewing radiographs in epidemiological caries research: a systematic review of the literature. Journal of Dentistry.2004;32:255 – 264.
5. Wenzel A. Bitewing and digital bitewing radiography for detection caries lesions. Journal of Dental Research 2004;83(Spec Iss):C72 – 75
6. Forner Navarro L, Llena Puy MC, Garcia Godoy F. Diagnostic performance of radiovisiography in combination with a diagnosis assisting program versus conventional radiography and radiovisiography in basic mode and with magnification. Med Oral Pathol Oral Cir Bucal 2008;13(4):261 – 265.
7. American Dental Association Council on Scientific Affairs. The Use of Dental radiographs; Update and recommendations. Journal of American Dental Association 2006;137:1304 – 1312.
8. Gormez O, Yilmaz HH. Image Post – Processing in Dental Practice. European Journal of Dentistry 2009;3:343 – 347.
9. Bader JD, Shugars DA, Bonito AJ. Systematic reviews of selected dental caries diagnostic and management methods. Journal of Dental Education 2001;10:960-968.
10. Pereira AC, Eggertsson F, Moustafa A, Zero DT, Eckert GJ, Mialhe FJ. Evaluation of three radiographic methosd for detecting occlusal caries lesions. Brazilian Journal of Oral Sciences 2009;2:67-70.
11. Salman FD. The effect of fissure morphology on caries severity of adults in north Iraq. Al – Taqani 2011;24:29-37.

12. Mestriner SF, Vinha D, Mestriner WJ. Comparison of different methods for the occlusal dentine caries diagnosis. Journal of Applied Oral Science 2005;13:28-34.

13. Dias da Silva PR, Martins Marques M, Steagall W, Medeiros Mendes F, Lascala CA. Accuracy of direct digital radiography for detecting occlusal caries in primary teeth compared with conventional radiography and visual inspection: an in vitro study. Dentomaxillofacial Radiology 2010;39:362–367.

14. Da Rocha ASP, de Almeida SM, Boscolo FN, Haiter Neto F. Interexaminer agreement in caries radiographic diagnosis by conventional and digital radiographs. Journal of Applied Oral Science 2005;13:329 – 333.

DISCOLORATION OF DECIDUOUS AND PERMANENT TEETH: CLASSIFICATION, ETIOLOGY AND TREATMENT OPTIONS

Selimović-Dragaš M.*[1], Kovačević N.[2]

[1] Department of Preventive and Pediatric Dentistry, Faculty of Dentistry, University of Sarajevo, Sarajevo, Bosnia and Herzegovina
[2] Public Health Center Lukavac, Department for Dental Health Care, Kakanj, Bosnia and Herzegovina

***Corresponding author**

Mediha Selimović-Dragaš, PhD
Faculty of Dentistry
Bolnička 4a
71000 Sarajevo
Bosnia and Herzegovina
Phone: +387 33 214-249 (ext.338)
e-mail address:
mselimovic96@gmail.com

ABSTRACT

The aim of this review is to present various causes of deciduous and permanent teeth discoloration, their classification and treatment options. Having in mind the differences but also the similarities in clinical features of different types of tooth staining, it is very important to know and understand the mechanisms behind tooth discolorations. That's why this review offers a new classification based on etiological background and a clinical appearance of tooth discoloration, considering it more suitable for the proper selection of a treatment. Color and the shape of the teeth are integrated part of facial aesthetics which plays a very important role in the complex social, cultural and psychological interaction of every person. Therefore, it is important that doctors of dental medicine understand the background of different tooth discolorations so, in cases with aesthetic problems, they are able to offer proper information for the patients with the aim to include them in the treatment planning.

Key words: tooth discoloration, extrinsic discoloration, intrinsic discoloration, internalized discoloration.

Introduction

The tooth can be described as an anatomic and functional complex of different tissues: enamel, dentin, pulp and cementum. Any changes of these structures will change its light transmitting and reflecting properties which will result as an alteration in the outward appearance of the tooth [1]. Tooth color represents a range of colors with the visible gradation, from the gingival margin to the incisal edge. Due to the proximity of dentin, the tooth is darker in the gingival area, canines are darker than the central and lateral incisors, and younger people, especially in the primary dentition, characteristically have lighter teeth [1]. The color of the teeth is determined by the yellowish color of dentin, modified by the thickness and degree of mineralization of semitransparent enamel [2].

Less mineralized and thus less transparent enamel make the color of deciduous teeth bluish–white comparing to the yellowish-white color of permanent teeth caused by the better mineralized and better light-permeable enamel of permanent teeth [2].

Any change in tooth color, different from the usual, can be marked as a discoloration of teeth. Having in mind the large number of variations in discoloration of teeth, correct diagnosis of the cause of discoloration is very important for the plan and the result of therapy.

The aim of this review is to present a various causes of deciduous and permanent teeth discoloration, based on contemporary achievements in the process of diagnosis of their etiology, their classification and treatment options.

Materials and methods

An extensive search of PubMed data base for clinical and in vitro studies in English, published between 1969. and 2015. was performed, using different combination of key words: tooth discoloration, extrinsic discoloration, intrinsic discoloration and internalized discoloration. Aside from the time frame and English dental literature, inclusive criteria for papers were: online full-text available, detailed information on study methodology and relevance for dental clinical practice. Included studies were: clinical trials, critical reviews, longitudinal studies and case reports. Clinical trials and recent reviews were considered with highest quality value and in the cases where was limited literature to find on a topic, case reports were used. Independent screening of 63 unique titles identified 40 studies that met the eligibility criteria.

Review of current literature and discussion

Tooth discoloration may be divided into three main types, intrinsic, extrinsic and internalized.

The discolorations on the tooth surface or in the acquired pellicle, caused by exogenous pigments were defined as an extrinsic discoloration [1, 3]. Based on cause, extrinsic discoloration can be divided into direct and indirect tooth discoloration [3] (**Table 1**.).

The stain, in direct staining, is a result of the basic color of the chromogen caused by compounds incorporated into the pellicle layer. Direct staining has multi-factorial etiology, mainly caused by the chromogens derived either from the diet or substances habitually placed in the mouth. Accumulation of bacterial plaque is also classified as this type of dental staining.

Indirect staining is caused by a chemical interaction on the tooth surface usually associated with local or systemic usage of different medicaments [3]. Indirect staining can be a result of occupational metal intoxication or environmental metal intoxication.

Gorlin and Goldman (1971.) classified extrinsic tooth discoloration according to its origin, as metallic or non-metallic [1]. In1997. Nathoo proposed classification of extrinsic tooth discoloration as a three categories: Nathoo tip I, Nathoo tip II, i Nathoo tip III [4].

Intrinsic tooth discoloration was caused by chromogens which have endogenous or exogenous origin and it can be defined as a staining incorporated in tooth structures during odontogenesis (pre-eruptive) or after odontogenesis (post-eruptive) [5]. (**Table 2**.)

Internalized discolorations are tooth discoloration formed during the tooth development, when extrinsic stain is incorporated within the tooth substance [1,3].

In literature, internalized discoloration was described as a *developmental* internalized discoloration when extrinsic stain was incorporate within the tooth substance following dental development or *acquired* internalized discoloration where changes on teeth or surrounding tissues, during the life, directly or indirectly affect the change of tooth color [1].(**Table 3.**)

For a dental practitioner knowing and understanding the etiology of tooth discoloration is of great importance because the correct diagnosis for the cause of discoloration has a profound effect on treatment outcomes. From the other side, it is important to explain to the parents the origin of dental discoloration in order to enable the appropriate treatment to be carried out.

Intrinsic, extrinsic and internalized discoloration clinically can be presented in eleven colors: white, black, blue, brown, green, grey, yellow, orange, pink, red and purple.

White tooth staining

Materia alba is a soft, mushy accumulation of bacteria, desquamated epithelial cells and salivary proteins on the outer surface of the tooth. White in color, it can be removed with a powerful jet of water [6].

Active early caries lesion is chalky-white with matte surface. Two or three weeks old incipient lesions can be visible only after the enamel is dry, while older lesions are seen on wet enamel. In this stage of early caries lesion discrete porosity on enamel surface also can be seen [7].

Clasification	*Etiological factors*	*Causes*	*Color*
DIRECT	DENTAL DEPOSITS	Materia alba	White
		Dental plaque/biofilm	Yellow
		Dental calculus	White, yellow, brown
	CHROMOGENIC MICROORGANISMS	Chromogenic fungi	Green
		Chromogenic bacteria	Brown, black, orange, blue, green
	DIETARY HABITS	Chromogens, acidic food. Intake of coffee, red vine and tea The color is due to tannin.	Brown, black
		Chlorophyll-Rich Diet	Greenish
	SUBSTANCES HABITUALLY PLACED IN THE MOUTH	Tobacco smoking/chewing tobacco	Dark brown, black
		Chewing of pan (a combination of betel nut of the areca palm, betel leaf, and lime)	Red-brown stain
		Chewing of Khat leaves (Catha edulis)	Yellowish-brown
		Chewing of nuts of Cola plant (Cola nitida)	Dark brown stains
INDIRECT	LOCAL USAGE OF MEDICAMENTS	Cationic antiseptics (chlorhexidine)	Yellowish-brown
		Essential oils / phenol solutions	Yellow
		Mouth rinses containing Copper salts	Green
		Potassium permanganate	Violet to black
		Silver nitrate	Grey, black
		Stannous fluoride	Yellow-brown
	ORAL ADMINISTRATION OF DRUGS	Iron containing oral solutions	Black
		Co-amoxiclav	Yellow-brown
		Doxycycline	Yellow-brown
		Linezolid	Brown
	OCCUPATION AND ENVIRONMENTAL FACTORS	Iron , Silver and manganese dust	Black stain
		Mercury and lead dust	Blue-green
		Copper and Nickel	Green stain
		Chromic acid,fumes	Deep orange stain

Table1.
Extrinsic discoloration, causes and types of stains

Enamel defects are white colored but with the adherence of pigments they become yellow or yellow-brown and they always show a sharp demarcation between sound and affected enamel. Enamel defects on a single tooth or only a few teeth suggest a local etiological factor. A systemic factor (both short and longer term) may affect all the teeth that are developing during the time of the insult and lead to what is described as a chronological defect [1]. The prevalence of developmental defects of enamel (DDE) at 12 years of age in Bosnia and Herzegovina was 32, 80%, with significantly more DDE in Banja Luka [8].

Dental fluorosis is a structural disturbance of dental enamel, caused by successive exposures to high concentrations of fluoride during tooth development, leading to enamel with lower mineral content and increased porosity. The clinical appearance may vary based on the severity from areas of white, opaque dots or stripes that occur on homologous teeth to diffuse opaque mottling superimposed on chalky white or dark brown/black areas. Opaque areas of enamel are porous (hypomineralized), and the degree of porosity depends on the concentration of fluoride in the body fluids during tooth development [9].

Amelogenesis imperfecta (AI) is a group of hereditary disorders, clinically and genetically heterogeneous, characterized by abnormal amelogenesis, affecting both primary and permanent dentitions [10]. Witkop in1988 presented the most widely used

Clasification	*Etiological factors*	*Causes*	*Color*
PREERUPTIVE	NON-GENETIC DISTURBANCE OF TOOTH GERM	Hypomineralization of enamel (demarcated and diffuse opacities)	White, yellow, brown, yellowish-brown
		Hypoplasia of enamel (generalized and localized)	
		Molar Incisor Hypomineralization (MIH)	
	GENETIC DISORDER	Amelogenesis imperfecta (AI)	White, yellow, brown, yellowish-brown
		Dentinogenesis imperfecta (DI)	Yellowish-brown, blue-grey
		Dysplasia dentinum (DD)	Yellow, brown, grey
	METABOLIC DISORDERS	Osteogenesis imperfecta (OI)	Yellowish-brown, blue-grey
		Epidermolysis bullosa	Yellow
		Cystic fibrosis (CF)	Yellow-grey, dark brown
		Congenital erythropoietin porphyria (CEP)	Red, reddish-brown
		Alkaptonuria (AKU)	Brown
	CONGENITAL HYPERBILIRUB INAEMIA	The breakdown products of haemolysis will lead to deposition of bile pigments in the calcifying dental hard tissues, particularly at the neonatal line.	Yellow, green, yellow-green, brown
	MEDICAMENTS	Tetracycline	Yellow, grey-brown
		Minocycline	Blue-grey
		Ciprofloxacin	Green
	CHRONIC FLUORIDE INTOXICATION	Dental fluorosis	Chalky-white, brown, black
POSTERUPTIVE	CHANGES IN THE DENTAL HARD TISSUES	Physiological involution of tooth	Yellow
		Cervical root resorption	Pink
	PULPAL CAUSES	Pulpal hemorrhage	Pink
		Necrosis of dental pulp	Grey, brown
		Obliteration of dental pulp	Yellow, yellowish-brown
		Internal root resorption	Pink
	MEDICAMENTS	Minocycline	Blue-grey

Table 2.
Classification of intrinsic tooth discoloration, causes and types of stains

classification system. Based on phenotypes and the inheritance patterns AI is divided into four main types and then into 15 subtypes that was clinically described by Ng and Messer 2009. [11]. Amelogenesis imperfecta type II and type IV, clinically can be manifested as white colored enamel [12].

Black tooth staining

Theilade at al.(1973.) put forward the view that external discoloration depend on oral hygiene, according to which black coloration was associated with children with good oral hygiene and low caries risk [13].

Bandon at al. claimed that actinomyces, porphyromonas gingivalis and prevotella melaninogenicus presents the microorganisms which are predominant in black tooth discolorations [14]., while Saba at al. found that actinomyces species were dominant comparing with other microorganisms [15]. Staining was result of presence of ferric sulphate made by reaction between hydrogen sulphide, which is a bacterial product and iron present in saliva and gingival fluid [16].

There is a positive correlation between the external discolorations and presence of trace elements, particularly iron in water [3]. Exposure to iron, manganese and silver can cause black external discoloration of the teeth [3]..

Hard inactive caries lesion and dental fluorosis can be black due to adherence of the pigment from the environment [3].

Epoxy resin-based sealers such as the AH26 can cause black discoloration of the teeth, after a few years of placement [17].

Medications, such as minocycline, aside from the characteristic blue-gray color, can stain root of the tooth, during its formation, in black color [18].

Blue, blue-green, blue-brown and blue-grey tooth staining

Blue tooth staining can be found in children with Syndroma Wast [19]. According to one case report, this staining was extrinsic caused by chromogenic bacteria pseudomonas aeruginosa [19]. Rarely, blue tooth staining can be found at patients with Parkinson's disease and cyanotic congenital heart diseases [18].

Mercury intoxication and intoxication with lead dust was a main cause of blue-green extrinsic discoloration of teeth, mainly as a result of bad oral hygie-

Clasification	*Etiological factors*	*Causes*	*Color*
DEVELOPMENTAL	PRE-ERUPTIVE CAUSES OF INTERNALIZED TOOTH DISCOLORATION	Pre-eruptive incorporation of extrinsic stain within the tooth substance following dental development. It occurs in enamel defects like hypomineralization and hypoplasia and in the porous surface of exposed dentine. The enamel defects can vary from white to yellow to brownish areas and they always show a sharp demarcation between sound and affected enamel.	
ACQUIRED	CHANGES OF THE DENTAL HARD TISSUES	Progressive loss of enamel and dentin due to attrition, abrasion and erosion	Yellow
		Dental caries	Chalky-white, yellow-brown, dark brown, black
		Physiological involution of tooth	Yellow
	PERIODONTAL CHANGES	Gingival recession	Yellow
	DENTAL MATERIALS	Amalgam	Blue-gray
		Composite/GIC	Yelow-brown
		Intracanal medicaments	Yellow, grey, brown
		Root canal sealers and obturating material	Grey, brown, black, pink
	IATROGENIC FACTORS	Incomplete removal of pulpal reminiscent during root canal treatment	Grey-brown

Table 3.
Classification of internalized discoloration according to origin of the stains

ne [3], while blue-green intrinsic discoloration was result of hemolytic disease of the newborn [20].

Minocycline is a semi-synthetic derivative of tetracycline. Its prolonged ingestion can lead to green-gray or blue-gray intrinsic staining of the teeth during and after the complete formation and eruption of teeth [3].

Crowns of teeth with dentinogenesis imperfecta usually have a normal size. In the cervical portion of the tooth there is a constriction that gives the crown a characteristic bulbous appearance. Teeth with dentinogenesis imperfecta show a variety of colors, most often a blue-gray or bluish brown, which demonstrate opalescence on transillumination [3, 18].

Longstanding amalgam restorations can generate stannous corrosion products, which migrates into the dentinal tubules leaving a blue-gray, dark grey to black color of dentine, especially in large cavity preparations with undermined enamel [3, 21].

Intracanal medicaments, as triple antibiotic paste (TAP), which contains ciprofloxacin, metronidazole and minocycline according to case report can, cause a blue-gray tooth discoloration [22].

Brown tooth staining

Chromogenic bacteria considered being a cause of brown extrinsic stains, placed typically at the gingival margin of the tooth, in children with good oral hygiene and low caries experience [13].

Intake of coffee and tea can cause brown extrinsic tooth discoloration due to tannin. The color seen on the tooth is thought to be derived from polyphenolic compounds that provide the color in food [3].

Some systemic medications are also shown to cause brown extrinsic staining. One case report show that linezolid 600 mg. of dose, which was ordinate two times a day during four weeks, caused brown extrinsic staining in a 11 year old girl [3].

Dark brown extrinsic stains, located on cervical third or even one half of tooth surface can be the result of tobacco from cigarettes, cigars, pipes, and chewing tobacco. This pigmentation is the result of the tar taken up by the pellicle, whose amount depends not on the amount of smoking but on the amount of present plaque, and during the time it penetrates into the enamel [16].

Brown stains on the surface of the teeth also could be due to the deposition of caffeine, tannins or theobromine that is result of daily chewing of nuts of Cola plant [16].

Incomplete metabolism of tyrosine and phenylalanine at the patients with alkaptonuria, results with the excessive amount of homogentisic acid that are deposited in the body and the teeth. This affects the permanent dentition by causing a brown discoloration [1].

Dark brown tooth discoloration observed in patients with cystic fibrosis (CF), autosomal recessive disorder, can be related to ingestion of tetracycline during tooth formation or to the metabolic effects of the disease itself [23].

Pigmentation of the primary dentition may result from hemolytic anemia of the fetus or newborn. Hemosiderin, a degradation product of hemoglobin, is deposited in forming dentin and enamel, causing brown color of the teeth [2].

Arrested carious lesion is manifested as destruction of both enamel and dentin with the color that ranges from light brown, to dark brown or almost black and the nature of this discoloration is not known yet. It is suggested that this color is exogenous in origin deriving from chromogenic bacteria and dietary habits. [3].

The brown/black discoloration of enamel, which can be seen at dental fluorosis, enamel hypoplasia and molar-incisor hypomineralization (MIH) is post-eruptive and probably caused by the internalization of extrinsic stain into the porous enamel [3].

Yellow and yellow-brown tooth discoloration

The most common yellowish tooth discoloration is a result of precipitation of dietary chromogens onto tooth surface deposits such as acquired pellicle or the plaque. Dental plaque formed on tooth surfaces is a complex ecosystem composed of diverse oral bacteria and salivary components. If it is in the form of acquired pellicle it can be seen after application of various kind of disclosure agents or by the probe. Excessive amount of dental plaque can be seen by naked eye as a yellowish stain on tooth surface [6].

Dental calculus is calcified dental plaque, composed primarily of calcium phosphate mineral salts deposited between and within remnants of formerly viable microorganisms. Supragingival dental calculus formation is placed next to ginigival margin mostly at tooth surfaces adjacent to the salivary ducts, colored yellow or yellow-brown [6].

Bad habits like smoking and chewing tobacco or chewing of Khat leaves, associated with bad oral

hygiene can cause yellowish-brown extrinsic tooth discoloration [16]

Some genetic defects in enamel or dentin formation including amelogenesis imperfecta, dentinogenesis imperfecta, dentinal dysplasia , molar incisor hypomineralization (MIH), osteogenesis imperfecta (OI) and hypoplasia of enamel can be associated with yellow to yellow-brown tooth discoloration.

Amelogenesis imperfecta, hereditary condition with thin, hard enamel with more severe hereditary hypoplasia has a yellow to yellow-brown appearance With prevalence of 1:700 children in Europe to 1:14000 children in America, it can be seen alone or as a symptom in some sindroms like Syndroma Tricho-dento-osseus, Syndroma Kohlshütter-Tönz, Syndroma McGibbon and Syndroma Jalili [24, 5, 2].

Dentinogenesis imperfecta (DI), autosomal dominant genetic conditions is characterised by abnormal dentine structure affecting either the primary or both the primary and secondary dentitions. According to the most current classification adopted by the Mendelian Inheritance in Man (MIM) dentinogenesis imperfecta type I or dentinogenesis imperfecta type II (classification system formulated by Shields) reported to have an incidence of 1 in 6,000 to 1 in 8,000 newborn children and can be connected with a yellow-brown tooth discoloration [25,26].

According to current MIM classification DI-I can be considered as a variable feature of Osteogenesis imperfecta (OI), Syndroma Ehles-Danlos, Syndroma Goldbatt, Syndroma Brachio-Skeletal-Genitalium and Schimke immuno-osseous dysplasia [26].

Dentine dysplasia type II (Shields classification), is an autosomal dominant genetic conditions which has different clinical features depending on dentition [3]. While permenent dentition can have a brown discoloration of the teeth, primary dentition is usually yellow to yellow-brown or has amber translucency like the one at dentinogenesis imperfecta [2].

Molar-incisor hypomineralization (MIH] is an idiopathic condition characterized by severe hypomineralized enamel affecting incisors and permanent first molars. Clinical features of enamel defects can vary from white to yellow to brownish areas and they always show a sharp demarcation between sound and affected enamel [3].

The prevalence of MIH in 12-year-olds in Bosnia and Herzegovina was 12, 3%, and study from 2009 showed that the prevalence of MIH in children from Sarajevo, aged 12 was 11,5% [8, 27].

Enamel hypoplasia (EH) is defined as a deficiency of enamel formation. A variety of environmental and genetic factors have been shown to contribute to the formation of these defects, including malnourishment, mechanical trauma or inflammation. Enamel hypoplasia can be localized or generalized and its colour varies from white, yellow to brownish [8].

Epidermolysis bullosa (EB) is a rare group of inherited disorders that manifests as blistering or erosion of the skin and, in some cases, the epithelial lining of other organs, in response to little or no apparent trauma. Patients with epidermolysis bullosa can have a pitting of the enamel possibly caused by vesiculation of the ameloblast layer which demonstrates a yellow tooth discoloration [3].

Mouth washes such as chlorhexidine can cause a yellow–brown extrinsic tooth discoloration. Having in mind that those mouth washes are cationic antiseptics most evidence indicates that the cause of staining is the precipitation of anionic dietary chromogens onto the adsorbed cations [16]. Mouthwash that contains stannous fluoride will often stain teeth in gold-yellow color [3].

Essential oils or phenol solutions, if used, also can be considered as a cause of yellow extrinsic tooth discoloration [3].

Tetracycline, oxytetracycline and demethylchlortetracycline are known to cause intrinsic discoloration when prescribed during tooth development. Teeth affected by tetracycline may have a yellowish appearance that fluoresces under ultraviolet light, giving off a bright yellow color [23].

Some cases presented in literature confirmed that yellow-brown extrinsic tooth discoloration can be found as a complication after a long-term usage of doxycycline 200mg/ day. Poor oral hygiene and intense sunlight exposure may be exacerbating factors in prominent staining of permanent dentition caused by doxycycline [28].

Several intracanal medicaments based on phenols or iodoform, sealed in the root canal are in direct contact with dentin. Penetration and oxidation of the materials in dentinal tubules will result with yellow or yellow –brown tooth discoloration [22].

A study by Mjor and Toffenetti reported that yellow-brown margin discoloration suggests inadequate acid-etching of the enamel prior to placing the bond agent, inadequate handling of the material (placing, concentration, adaptation) and problems associated with polymerization shrinkage [29].

Pulp canal obliteration occurs commonly following traumatic injuries to teeth. Radiographically pulpal obliteration is characterized by the apparent loss of the pulp space and yellow to yellow-brown crown discolouration is a common clinical finding in teeth with pulp canal obliteration [12].

As a result of progressive loss of enamel and dentin due to attrition, abrasion and erosion, enamel thins and the tooth becomes darker as the color of the dentin becomes more apparent. At that stage tooth has yellow to dark yellow color. Once the dentin is exposed, the potential for chromogens to enter the body of the tooth increases and tooth color becomes darker [3].

During the process of ageing, the enamel undergoes both thinning and textural change with the change in its light transmission properties. The natural darkening and the yellowing of the teeth, which occur with age, can be due to the combination of the factors involving both enamel and dentin. Depositions of secondary and tertiary dentin and pulp stones are the factors that contribute to the darkening of the teeth as a result of aging [3].

Yellow-green tooth discoloration

A yellow-green tooth discoloration can be seen at the cases of Congenital hyperbilirubinaemia when the level of bilirubin in blood exceeds 30mg/100ml. This will lead to deposition of bile pigments in the calcifying dental hard tissues, particularly at the neonatal line [30].

Green tooth discoloration

According to Theilade and associates [13] green extrinsic discoloration in children are usually associated with poor oral hygiene. Chromogenic bacteria have also been suggested as an etiological factor in the production of this kind of stains that are more common in boys and have a tendency to reappear after complete removal [16].

Chromogenic bacteria as penicillium and chromogenic fungi as aspergillus species that grow up only on light are considered as a cause of green tooth discoloration on vestibular surfaces of maxillary teeth [16].

Green enamel discoloration can bee found after the consumption of food rich in chlorophyll [18]. Intoxication by copper and nickel, as well as mouthwash copper salts may cause a greenish extrinsic discoloration [3]. Some medications are also known to cause intrinsic discoloration when prescribed during tooth development.

As an example can be cited one case report from 1991. in which ciprofloxacin, second-generation of fluoroquinolone synthetic antibiotic, has been associated with greenish intrinsic discoloration of the teeth [3].

Orange and orange-red tooth discoloration

Orange extrinsic discolorations as well as green extrinsic discoloration in children are usually associated with poor oral hygiene. Comparing with green tooth discoloration, orange extrinsic discolorations are not so common, and they are easier to remove with tooth brush. Chromogenic bacteria, namely serratia marcescens and flavobacterium lutescens have been cited as possible etiological agents of those discolorations typically at the gingival margin of labial surfaces of mandibular and maxillary anterior teeth [16].

Occupational intoxication with chromic acid fumes may cause deep orange stain [3].

Also, red-orange tooth discoloration can be found after the root canal therapy as an effect of eugenol and phenolic compounds [31].

Pink tooth discoloration

It has been shown that the pinkish hue seen initially after trauma may disappear in 2 to 3 months if the tooth becomes revascularized [12].

Cervical root resorption is a specific kind of external resorption often presents a pink spot lesion at the cemento-enamel junction in an otherwise symptomless tooth. Internal root resorption always begins from the pulpal side of the root surface, where hyperplastic, vascular pulp tissue fills in the resorbed areas. The first evidence of the lesion may be the appearance of a pink-hued area on the crown of the tooth. This condition is referred to as the "pink tooth of Mummery" [32, 33]. Also, pink discoloration can bee seen after the usage of some sealers like Roth Elite Grade 801 that contain ingredients that will discolor over time even without tubule penetration [34].

Purple-pink post-mortem tooth discolorations have been well documented in the literature. Some authors have suggested that causes of death such as

carbon monoxide poisoning and drowning have an influence on this kind of discoloration [35].

Red, Reddish brown, red-purple tooth discoloration

In a single case report in the literature Rendall and McDougall, (1976) described the phenomenon of red discoloration of the upper central incisor teeth associated with periapical granuloma in Lepromatous Leprosy. The authors suggested that the upper incisor area is relatively cool, which can be a factor which may be of critical importance for the lodgement and multiplication of this bacillus, as it is in other body sites in Lepromatous Leprosy [36].

Congenital erythropoietin porphyria (Günther's disease) is a rare, autosomal recessive disorder of porphyrin metabolism, resulting in an increase in the formation and excretion of porphyrins. The porphyrin pigments are incorporated into teeth during dental formation resulting with a characteristic reddish-brown discoloration of teeth, called erythrodontia. The affected tooth shows a red fluorescence under ultra-violet light [23].

Tay et al. (2006] reported red-purple staining of light-exposed, root-treated dentin when root canals were rinsed with 1.3% NaOCl as initial rinse followed by the use of BioPure MTAD as final rinse. This intrinsic dentin staining occurred irrespective of whether the root canals were filled, and could be observed even in crown dentin when the latter was sequentially immersed in NaOCl and MTAD [37].

Grey, brown-gray and yellow-grey tooth discoloration

Systemic administration of the tetracycline, during pregnancy and during the mineralization of the crowns of the teeth, results with a tetracycline staining. Teeth affected by Chlortetracycline have a brown-gray appearance that is worse on eruption and diminishes with time. The affected teeth also fluoresce under ultraviolet light, giving off a bright yellow color [23].

Also, tetracycline intracanal medicament as Ledermix paste (triamcinolone acetonide and demethylchlortetracycline), used for endodontic therapy may cause dark gray-brown discoloration [3].

Some root canal sealers like Sealapex, can be the cause of grey tooth discoloration [34].

Incomplete removal of obturating material and sealer remnants in the pulp chamber, mainly those containing metallic components, often result in grey and grey-brown discoloration [3].

Necrosis of dental pulp, which occurs several weeks or months after acute trauma, can change a tooth color to grey-brown. This discoloration is a result of hemolysis of the red blood cells that release the hema group. Later, hema group combines with the putrefying pulp tissue and form black iron sulfide that changes a tooth color to grey-brown. Periapical changes, as an additional sign of necrosis, can be seen at the earliest three weeks after the trauma, and often need to take up to a few months [12].

Also, the gray-yellow tooth discoloration can be seen in cystic fibrosis [23].

Treatment planning and recommendations for the therapy

For the planning of proper treatment of tooth discoloration in children is important to know and understand the etiology, appearance, composition, location, severity and degree of adherence of dental stains. In order to make a correct diagnosis and enable the appropriate treatment to be carried out it is necessary to provide a detailed patient's history of tooth discoloration and clinical examination. The scratch test is usually used to distinguish between extrinsic and intrinsic discoloration [3]. Light scratching with a dental instrument is used to assess surface texture. Intrinsic discoloration cannot be removed by using the scratch test and distribution is either generalized to all teeth or localized to certain teeth or tooth surfaces when a single tooth is discolored.

In many cases of tooth discoloration in order to determine the definitive diagnosis it is necessary to perform additional tests, and some cases also require a multidisciplinary approach.

After precise definition of the cause of tooth discoloration it is necessary to select a proper treatment, which is different for external, internal and internalized discoloration.

According to the American Academy of Pediatric Dentistry (AAPD), "toothbrush prophylaxis" is effective treatment for the removing of dental plaque but in a case of dental calculus and extrinsic discoloration tooth brushing is not enough [38]. "Rubber cup prophylaxis" is more effective in removal of bacterial biofilm and extrinsic discoloration on tooth surfaces,

but it cannot remove dental calculus [38]. Therefore ultrasonic and sonic scaling is the recommended treatment for removal of dental calculus [38]. The small, quick vibrations in combination with a water flow are proved to be very effective in removal of deposits on the tooth surface. The benefits of ultrasonic scaling include increased efficiency of calculus removal and less need for hand scaling. Treatment of discolored dental fissures include air-jet polishing with an abrasive powder but it has to be kept in mind that this method can lead to enamel removal, so its frequent use is not advised [7]. Also, gaseous ozone can be used for elimination of the microorganisms from unreachable places, what will lead to change the conditions necessary for the growth and development of microorganisms responsible for the tooth discoloration and demineralization [7].

Treatment of internal tooth discoloration depends primarily on the age of the patient and their dentition and should be planned from simpler to more complex procedures. Treatment of discoloration of deciduous teeth caused by blood pigments, porphyrins or tetracycline is not recommended, which means that most treatment refers to the treatment of permanent dentition [23].

According to most of the authors treatment of tooth discoloration should be started with tooth whitening [23, 39]. Depending of the vitality of the tooth, recommended treatment is bleaching with carbamide peroxide for vital teeth and bleaching with sodium perborate (tetrahydrate) with 3% hydrogen peroxide or water for non-vital teeth, considering that AAPD do not recommend bleaching of vital teeth in mixed dentition stage [39]. In cases where the results of tooth whitening are not satisfied, next recommended treatment will be veneers, composite one for school children, and porcelain veneers for high school children and grown ups. Recommended treatment for tooth discoloration of deciduous and permanent teeth, which were result of hypoplasia, is tooth restoration [40] preparing by GIC or composites [12] or prosthetic one [40] using stainless steel crowns [12]. Depending of the severity of the problem, treatment of tooth discoloration of frontal permanent teeth like enamel opacities, MIH, mild and moderate dental fluorosis, according to Dean index, includes microabrasion techniques alone or in combination with vital bleaching techniques [12].

Conclusion

This review summarizes the literature findings of different etiological factors of tooth discoloration. Having in mind that tooth staining influences the treatment options and may have an effect on the outcome of treatment, new comprehensive classification of tooth discoloration based on etiological background and consequently staining are considered to be more understandable for dental practitioners. An understanding of the mechanism behind the discoloration is of high relevance to the dental practitioner as it can be valuable in the decision-making process when considering how to treat different kinds of tooth discoloration.

Declaration of interest

The authors have no conflict of interest to declare.

References

1. Watts A, Addy M. Tooth discolouration and staining: a review of the literature. Br Dent J 2001; 190(6): 309-316.
2. Beloica D, Vulović M, Gajić M, Stevanović R, Carević M, Ivanović M, i sar. Dečja stomatologija. Beograd: Elit Medica; 2000.
3. Manuel ST, Abhishek P, Kundabala M. Etiology of tooth discoloration: a review. Nig Dent J. 2010; 18(2): 56-63.
4. *Nathoo SA*. The chemistry and mechanisms of extrinsic and intrinsic discoloration. J Am Dent Assoc. 1997; 128(Suppl): 6S-10S.
5. Plotino G, Buono L, Grande NM, Pameijer CH, Somma F. Nonvital tooth bleaching: a review of the literature and clinical procedures. J Endod. 2008; 34(4): 394-407.
6. Topić B. Parodontologija: Biologija – Imunopatogeneza - Praksa. Sarajevo – Zagreb, Stomatološki fakultet - Medicinska naklada; 2005.
7. Kobašlija S, Jurić H, Vulićević ZR, Anić I, Čuković-Bagić I, Pavelić B, i sar. Minimalno invazivna terapija. Sarajevo: Dobra knjiga; 2012.

8. Muratbegović A. Istraživanje razvojnih defekata cakleni i molarno-incizivnih hipomineralizacija kod dvanaestogodišnjaka [Magistarski rad]. Sarajevo: Univerzitet u Sarajevu, Stomatološki fakultet; 2005.
9. Kobašlija S, Huseinbegović A, Selimović-Dragaš M, Berhamović E. Karijes zuba - primarna prevencija i kontrola. Sarajevo: Stomatološki fakultet Univerziteta u Sarajevu; 2010.
10. Cherkaoui Jaouad I, El Alloussi M, Chafai El Alaoui S, Laarabi FZ, Lyahyai J, Sefiani A. Further evidence for causal FAM20A mutations and first case of amelogensis imperfecta and gingival hyperplasia syndrome in Morocco: a case report. BMC Oral Healt. 2015;15:14. doi:10.1186/1472-6831-15-14.
11. Ng FK, Messer LB. Dental management of amelogenesis imperfecta patients: a primer on genotype-phenotype correlations. Pediatr Dent. 2009; 31(1): 20-30.
12. Koch G, Poulsen S. Pediatric dentistry: a clinical approach. 2 nd ed. Oxford: Blackwell Publishing Ltd; 2009.
13. Theilade J, Slots J, Fejerskov O. The ultrasound of black stain on human primary teeth. Scand J Dent Res. 1973; 81(7): 528–32.
14. Bandon D, Chabane-Lembobub A, Le Gall M. Exogenous tooth discoloration in childeren: black stain. Arch Pediatr. 2011; 18(12): 1348-52. doi: 10.1016/j.arcped.2011.07.014. Epub 2011 Sep 6.
15. Saba C, Solidani M, Berlutti F, Vestri A, Ottolenghi L, Polimeni A. Black stains in the mixed dentition: a PCR microbiological study of the etiopathogenic bacteria. J Clin Pediatr Dent. 2006; 30(3):219–24.
16. Hattab FN, Qudeimat MA, Al-Rimawi HS. Dental discoloration: an overview. J Esthet Dent. 1999; 11(6): 291-310.
17. Thomson AD, Athanassiadis B, Kahler B, Walsh L. Tooth discoloration: staining effects of various sealers and medicaments. Aust Endod J. 2012; 38 (1):2-9. doi: 10.1111/j.1747-4477.2011.00339.x.
18. Neville BW, Damm DD, Allen CM, Bouquot JE. Oral and Maxillofacial Pathology. 3rd ed. St. Louis, Mo: Saunders Elsevier; 2009.
19. Bussell RM, Deery C. Case report: Blue chromogenic dental staing in child with West syndrome. Eur Arch Paediatr Dent. 2010; 11(6): 298-300.
20. Barta JE, King DL, Jorgensen RL. ABO blood group incompatibility and primary tooth discoloration. Pediatr Dent. 1989; 11(4): 316-318.
21. Wei SHY, Ingram MJ. Analyses of the Amalgam-Tooth Interface Using the Electron Microprobe. J Dent Res. 1969; 48(2): 317- 320.
22. Kim JH, Kim Y, Shin SJ, Park JW, Jung IY. Tooth discoloration of immature permanent incisor associated with triple antibiotic therapy: a case report. J Endod. 2010; 36(6): 1086-91. doi: 10.1016/j.joen.2010.03.031.
23. Dean JA, Avery DR, McDonald RE. McDonald and Avery's Dentistry for the Child and Adolescent. 9th ed. Maryland Heights, Mo: Mosby Elsevier; 2011.
24. Neto NL, Paschoal MA, Kobayashi TY, Rios D, Silva SM. Early oral rehabilitation of a child with amelogenesis imperfecta. J Health Sci Inst. 2010; 28:246–8.
25. Rajendran R. Developmental disturbances of oral and paraoral structures. In: Sivapathasundharam B, Rajendran R, editors. Shafer'S Textbook of Oral Pathology. 6th ed. Noida: Elsevier (A Division of Reed Elsevier India Pvt. Ltd.); 2009.
26. Barron MJ, McDonnell ST, MacKie I, Dixon MJ. Hereditary dentine disorders: dentinogenesis imperfecta and dentine dysplasia. Orphanet J Rare Dis. 2008; 3:31. doi:10.1186/1750-1172-3-31.
27. Arslanagić-Muratbegović A. Evaluacija kliničkih parametara molarno incizivnih hipomineralizacija u predikciji posteruptivnog loma cakline [Doktorska disertacija]. Sarajevo: Univerzitet u Sarajevu, Stomatološki fakultet; 2011.
28. Ayaslioglu E, Erlek E, Oba AA, Cebecioĝlu E. Doxycycline induced staing of permanent adult dentition. Aust Dent J. 2005; 50(4): 273-275.
29. Mjör IA, Toffenetti F. Placement and replacement of resinbased composite restorations in Italy. Oper Dent. 1992; 17(3): 82-5.
30. Amaral TH, Guerra Cde S, Bombonato-Prado KF, Garcia de Paula E Silva FW, de Queiroz AM. Tooth pigmentation caused by bilirubin: a case report and histological evaluation. Spec Care Dentist. 2008; 28(6): 254-257. doi: 10.1111/j.1754-4505.2008.00048.x.

31. Van der Burgt TP, Eronat C, Plasschaert AJM. Staining patterns in teeth discolored by endodontic sealers. J Endod. 1986; 12(5): 187-91.

32. Thomas P, Krishna Pillai R, Pushparajan Ramakrishnan B, Palani J. An Insight into Internal Resorption. ISRN Dentistry. 2014; 2014:759326. doi: 10. 1155 /2014 /759326.

33. Fuss Z, Tsesis I, Lin S. Root resorption-diagnosis, classification and treatment choices based on stimulation factors. Dent Traumatol. 2003; 19(4): 175-82.

34. Davis MC, Walton RE, Rivera EM.Sealer distribution in coronal dentin. J Endod. 2002;28:464-6

35. Gowda BC, Sivapathasundharam B, Chatterji A, Chatterji BL. Histological appearance of postmortem pink teeth: Report of two cases. J Forensic Dent Sci. 2015; 7(2): 168-70. doi: 10.4103/0975-1475.156200.

36. Rendall JR, McDougall AC. Reddening of the upper central inciscors associated with periapical granuloma in lepromatous leprosy. Br J Oral Surg. 1976; 13(3): 271-7.

37. Tay FR, Mazzoni A, Pashley DH, Day TE, Ngoh EC, Breschi L. Potential iatrogenic tetracycline staining of endodontically treated teeth via NaOCl/MTAD irrigation: a preliminary report. J Endod. 2006; 32(4):354-8.

38. American Academy of Pediatric Dentistry. Policy on the role of dental prophylaxis in pediatric dentistry; 2012. Available at: http: //www.aapd.org/media /Policies _ Guidelines /P_ Prophylaxis.pdf. Accessed April 2, 2015.

39. American Academy of Pediatric Dentistry. Policy on the Use of Dental Bleaching for Child and Adolescent Patients; 2014. Available at: http://www.aapd.org/media/ policies_guidelines / p_bleaching.pdf. Accessed November 12, 2015.

40. Welbury RR, Duggal MS, Hosey MT. Paediatric dentristry. 3 rd ed. New York: Oxford University Press; 2005.

CLINICAL EVALUATION OF THE EFFECTS FROM SURGICAL REGENERATIVE PERIODONTAL THERAPY WITH THE USE OF BIO-MATERIALS

Todoroska S.*[1], Atanasovska-Stojanovska A.[1], Popovska M.[1], Ivanovski K.[1]

[1] Department of Periodontology and Oral Pathology University Dental Clinical Center "St.Pantelejmon" Faculty of Dentistry, University "Ss. Cyril and Methodius" Skopje, Republic of Macedonia

***Corresponding author**

Sashka Todoroska
Department of Periodontology and Oral Pathology
University Dental Clinical Center "St.Pantelejmon" Faculty of Dentistry
University "Ss. Cyril and Methodius" Skopje
Mother Tereza 17, 1000 Skopje
Republic of Macedonia
Phone: +389(02)3299041
E mail: saska_todoroska@yahoo.com

ABSTRACT

Background: Conventional treatment of destructive periodontal disease can arrest the disease, but does not lead to restoration of connective tissues and bone support. Regenerative periodontal therapy should result in formation of a new cement, connective tissue attachment and alveolar bone.

Objective:The purpose of this study was to compare clinical and radiological outcomes of regenerative surgical treatment using either enamel matrix proteins (EMP) combined with bovineporous bone mineral (BPBM) or with BPBM alone in the treatment of periodontal intrabony defects in human patients.

Methods: Six paired intrabony defects were surgically treated using a split-mouth design. Defects were treated with EMP(Emdogain®) +BPBM (Bio-Oss®) in one group, and with BPBM in the second group. Clinical and radiological evaluation was performed at 6 months.

Results: Preoperative probing depths, attachment levels were similar for both groups. Post-surgical measurements taken at 6months revealed significantly greater reduction in recession level in the first group (EMP +BPBM). Improvement in all clinical parameters for both methods were registered. But there was no significant difference between the two methods for resolution of teeth mobility.

Conclusion: The results of this study showed that surgical treatment with the use of bio-materials in combination or alone ensures better bone filling and that clinical attachment gains when compared to preoperative measurements. Significant reduction in the degree of dental luxation was present in both groups. However, there were significant lower values for soft tissue recession in the group with EMP+BPBM.

Key words: regeneration, periodontal surgery, bio-materials, Bio-Oss®, Emdogain®

Introduction

Periodontal disease is an infectious disease caused by bacteria of the dental plaque. It is characterized by destruction of the periodontal tissues. In order to help patients affected by periodontal disease to acquire and maintain good oral health, function and aesthetics, various therapeutic approaches have been developed, depending on the degree and severity of the disease [1-3]. Durability of the tooth depends on the pulp and periodontal health status, periapical region and presence to the extent of reconstructions. Choosing between periodontal regeneration to allow the preservation of the tooth, and tooth extraction, is the most questionable decision in dental clinical practice. It affects treatment plan and refers to the future life style of the patient [4]. Prior to regenerative therapy, treatment begins with initial, hygienic phase which includes: patient education, plaque control, scaling and root planning, antibacterial therapy and elimination of plaque retentive factors. When these methods fail to prevent bone loss, further steps are necessary leading to surgical and regenerative therapy [5].

While repair is healing of a wound with tissue that doesn't restore architecture and function of the lost parts, regeneration is a reconstitution of injured or lost parts. Periodontal regeneration refers to regeneration of the tooth supporting tissues: cementum, periodontal ligament and alveolar bone on previously diseased root surface. New attachment comprises union of connective tissue with root surface and it may be epithelial adhesion or connective tissue adaptation and it may include new cementum. New attachment differs from reattachment which comprises of the reunion of epithelial and connective tissue with a root surface. Bone fill comprises of clinical restoration of bone tissue in a treated periodontal defect [6,7].

Objectives of the regenerative periodontal therapy are: Restoration of the complete apparatus attached to the tooth with bone, cement and periodontal ligament; Prevention of long attached epithelium migration as a risk factor for recurrence of periodontitis; Long time retention of the teeth and acceptable esthetics. Regenerative therapy has an advantage over the extraction of the tooth. It was proven that periodontal is compromised but treated teeth and have survival rates equivalent to survival rates of implants in well-maintained patients [8].

Bone substitute BPBM(Bio-Oss®), or porous bone mineral of beef origin is used in periodontology and in oral and maxillofacial surgery. Experiments showed that it is slowly absorbed and integrated into the natural bone. Crystal structure of the mineral is quite similar to human bone and easily fits into the natural processes of bone modeling and remodeling. Slow absorption of the particles enables long-term preservation of volume, the body accepts these particles and they fully integrate into living tissue [9,10].

During embryonic development, amelogenins - enamel matrix protein derivatives EMD, regulate initiation, propagation, setting and final maturation of hydroxyl-apatite crystallites of the enamel. Enamel matrix proteins are temporarily deposited on the surface of the dental root and provide initial and essential step in the formation of cellular cement [11]. When used in periodontal lesions EMD mimic the development of the supporting apparatus of teeth during their formation [12 - 14]. The origin of EMD (Emdogain® -Straumann Basel, Switzerland) is from dental rudiments from developing piglets six months old. Since EMD has pork origin, it has the potential to stimulate the defense reactions in humans. However derivatives of enamel matrix are very similar in all mammals and rarely act antigenic applied to the root surface during the surgical procedure. Emdogain® allows the layer of insoluble matrix to attract mesenchymal cells able to add new matrix components and growth factors participating in obtaining dental attachment [13]. Results from previous clinical trials show that Emdogain® upgrades clinical attachment and bone in 93% of cases. Studies also indicate that patients with deep periodontal pockets (over 6mm) with a 1-and 2-wall infra-bone defects, can expect a significant progress for alveolar bone and bone filling up to 60-70%[15].

Case description

A 41 year old female patient reported to Clinic for Oral Pathology and Periodontology complaining to bleeding when brushing teeth, increased teeth mobility and discomfort from the teeth in general. Patient's dental history gave information about previous non-regular periodontal treatments for the past 10 to 11 years. Surgical or regenerative treat-

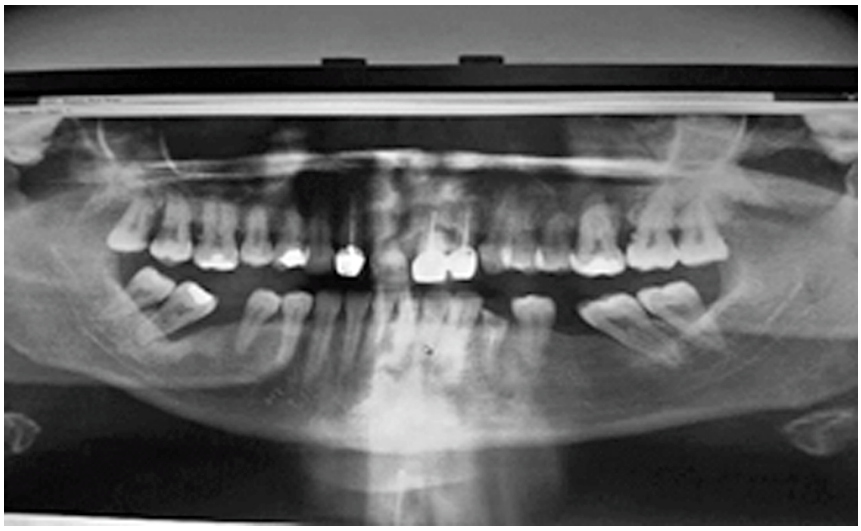

Figure1.
Panoramic radio-graph image before treatment showing generalized horizontal bone destruction and vertical bone loss around teeth: 17, 14, 26, 25 and 47.

ment for the periodontal disease was never done before. Medical history was not corrspondent to the periodontal status. Patient smokes 2-3 cigarettes per day not taking any other medications [4, 5]. Clinical periodontal examination showed generalized gingival inflammation according Bleeding Papilla Index (BPI Saxer i Mùhlemann, 1975) - grade 3. Unsatisfying oral hygiene according to Approximate Plaque Index (API; Lange, 1986) of - 40% plaque was present. In the upper jaw, recorded teeth mobility was at mean 2.46, gingival recession at 4,85 mm, probing depth at 5.8 mm, loss of clinical attachment level at 10,85 mm respectively and furcation involvement of I grade according to the Glickman´s classification. Panoramic radio-graph image (**Figure 1.**) showed a great, general, horizontal loss of dental alveolar bone with vertical bone destruction around teeth: 17, 14, 26, 25 and 47.

On the basis of clinical and para clinical findings diagnosis of a chronic generalized,advanced periodontitis was determined [2, 3].

Treatment procedure

Whole mouth treatment with detail scaling and root planning was done at the first visit [5]. Explanation and directions for meticulous oral hygiene practice were presented as well, and recommendation for complete smoking cessation. One week later, API was <20% and operative treatment was scheduled 3 days later. (**Figure 2.**)

Figure 2.
Clinical appearance of the upper right side before the operative treatment.

Figure 3.
After reflection of the flap, detail scaling and root planning.

Figure 4.
Placement of Bio-Oss® in vertical bone defects.

Figure 5.
Closure of soft tissue flap with interrupted suturing technique.

Figure 6.
10 days after operation

Figure 7.
Six weeks after operation

Day before the operation, antibiotic was prescribed: tablets of Amoxiclave 1000mg, twice a day and continued for the next five days. Within the operative treatment, disinfection of the operative ground with Betadine 10% and infiltration anesthetic injection of 2% Lidocaine with adrenaline were applied. Starting with intra-crevicular incision at the labial site, full thickness flap was raised from tooth -18 ending with tooth -11. Complete scaling and root planning was done on labial and palatal side. Bone defects were filled with bovine-derived hydroxyapatite xenograft - Bio-Oss®[14,16] (**Figures 3 and 4**).

After flaps reposition and adaptation, single suture technique (with non-reabsorb able Silk USP 5/0 EP1 Braided black 75cm 3/8circ.reverse cutting – 16mm) was done to fix the soft tissue in the place (**Figure 5.**).

Sutures were removed 10 days after the surgery (**Figure 6.**). Patient was scheduled for control visits two, four and six weeks after followed by monthly recall visits. Rinse of the oral cavity with 0, 2% chlorhexidine solution (Curaprox) twice daily during next six weeks was introduced. Oral analgesics (ibuprofen 800mg every 8 hours if necessary) were prescribed. Four weeks after the procedure patient started gentle tooth cleaning using the roll technique.

Six months later, second panoramic radio-graph image was taken before the second operation on the contra-lateral side, and for the control of the result from previous surgery (**Figure 8.**).

After the disinfection of the operative ground with Betadine 10% and applying of anesthetic injection of 2% Lidocaine with adrenaline, incisions in the

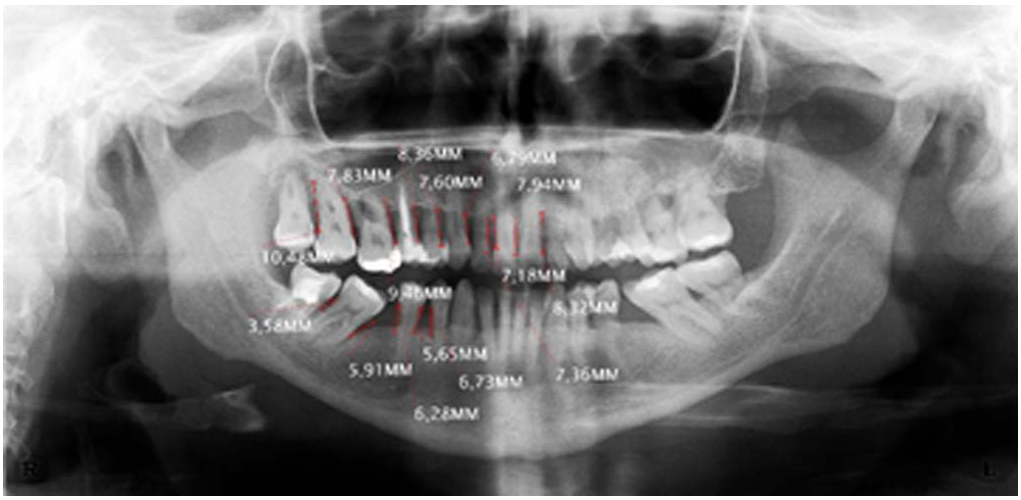

Figure 8.
Control panoramic radiography after six months

gingival pockets were performed and mucoperiosteal flaps were raised on vestibular and palatal side (**Figures 9. and 10.**).

All granulation tissue was removed from the bone defects and root surface was washed with physiological saline (**Figure11.**).

Treatment of the defects with EMP was performed following manufacturer´s instructions. Root surfaces adjacent to the defects were treated with Pref gel® (24%EDTA) for 2minutes. The area was then rinsed with sterile saline solution. Emdogain® was then mixed with Bio-Oss® and applied into the defects [17, 18]. The graft material was packed in the defects

Figure 9.
Six months later, second operation

Figure10.
Raised full thickness flap

Figure11.
After debridement of the granulation tissue

Figure12.
Pref gel® conditioning

Figure13.
Emdogain® +Bio-Oss®application

Figures14. and 15.
Ten days after operation

using amalgam condensers to the level of the bony walls (**Figures 12. and 13.**).

Flaps were repositioned and sutured using interrupted suturing technique with non-reabsorb able Silk USP 5/0 EP1 Braided black 75cm 3/8circ.reverse cutting – 16mm.

Patient was instructed to rinsing the oral cavity with 0, 2 % chlorhexidine solution (Curaprox) twice daily. Oral analgesics (ibuprofen 800mg every 8 hours if necessary) were prescribed. Ten days postoperative, sutures were removed. Surgical wounds were cleaned with iodine solution [20,21]. Two weeks after the procedure patient started gentle tooth cleaning using the roll technique (**Figures14. and 15.).**

Patient was examined weekly up to 1 month after the operation and then at 3 and 6 months. Postoperative care included reinforcement of oral hygiene and mechanical plaque removal.

Discussion

The results from our study confirm previous findings for the improvement of clinical parameters achieved with EMP and EMP combined with BPBM [17,19,22]. At the baseline clinical periodontal examination showed generalized periodontal inflammation. After the improvement of the values for the plaque index and PBI before the surgical treatment, results have sustained during the next six months.

Results for the upper right side – control group, showed significant improvement for the teeth mobility from mean 2,37 to 1; GR mean from 4,25 mm

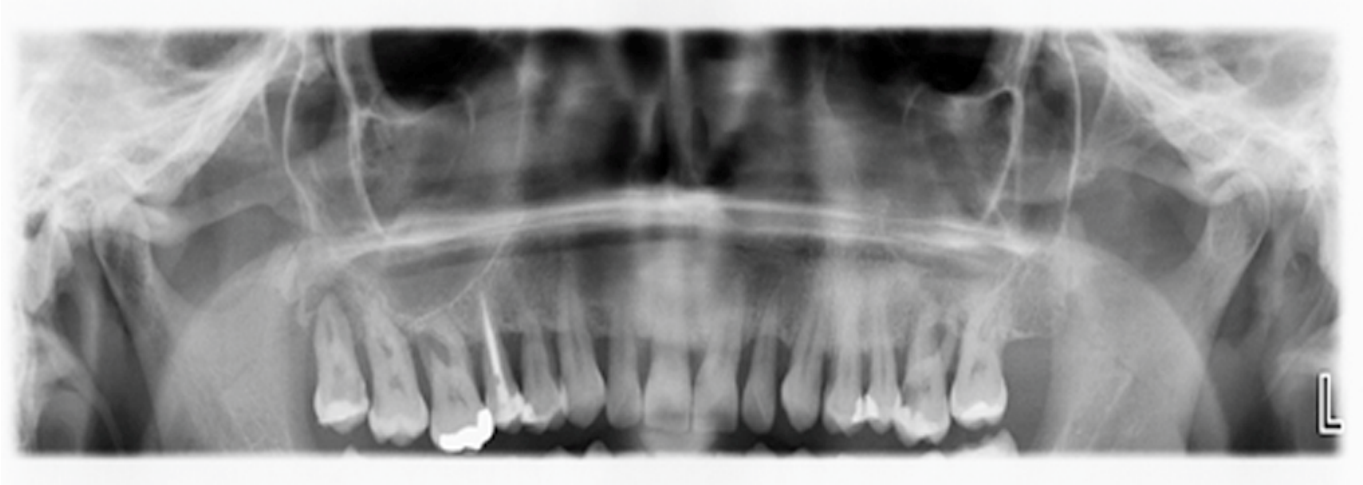

Figure16.
Radiography 12 months after the first and 6 months after the second treatment

to 3,87 mm; PD mean from 5,87 mm to 5,25 mm; CAL mean from 10,12 mm to 9,12. (**Figure16.**)

1 = Teeth mobility
2 = Gingival recession(mm)
3 = Probing depth(mm)
4 = Clinical attachment level(mm)

In the upper left side – test group, results showed significant improvement for the clinical parameters. TM mean from 2,14 to 0,28; GR mean from 4,14 mm to3 mm; PD mean from 5,71 mm to 2,42 mm; CAL mean from 9,85 mm to 5,42 mm (**Figure18.**).

In human, studies assessing histological quality of the regenerated tissues and type of attachment are limited because the block sections are necessary to be examined. Even with the limitation of this study, results indicate that we have gained better success with the second treatment (EMP+BPBM) in stabilizing teeth mobility, improving gingival recession,

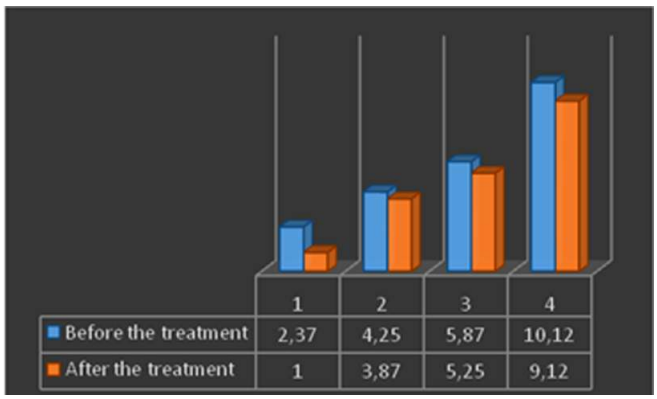

Figure17.
Clinical findings before the regenerative treatment (baseline) and six months after the regenerative periodontal therapy with the use of Bio-Oss®.

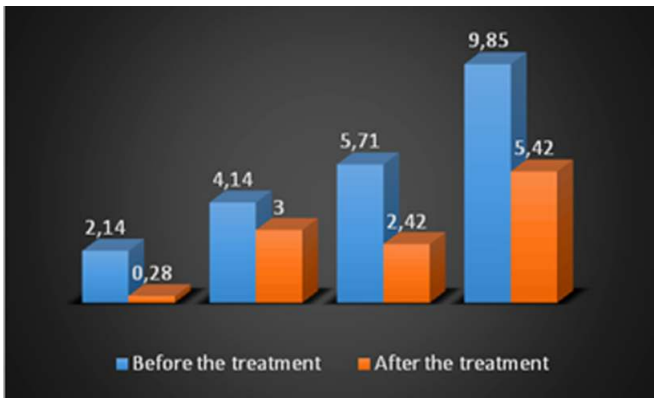

Figure18.
Results presented at baseline and six months after regenerative periodontal therapy with the use of Bio-Oss®and Emdogain®

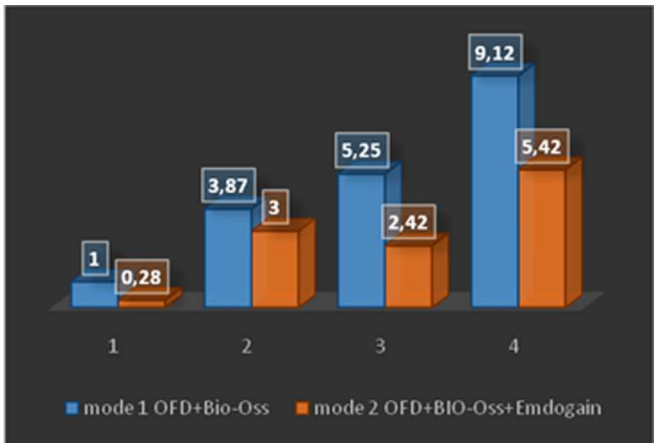

Figure 19.
Difference between the results from two treatment modalities.

improving probing depth values and significant lower clinical attachment level loss than with the first treatment (BPBM) in comparison to the values before the surgical treatment (baseline). In the test group we found 16% improvements for the GR, 40% improvements for the PD and 30% improvements for CAL. In the control group results show 4% improvements for GR, 6% improvements for PD and 6% improvements for CAL. It takes longer period of result tracking to make the final assessment and to bring conclusion over the treatment efficacy [23].

Conclusion

Minimally invasive surgical technique ensures minimal intraoperative and postoperative pain and morbidity. Additionally, use of bio-materials: BPBM (in our case Bio-Oss®) and enamel matrix proteins (Emdogain®) in treating bone defects, ensures better bone filling, greater clinical attachment levels and lower values for soft tissue recession. It brings a significant reduction in the degree of dental luxation. We found even better results when combining the two materials but we will continue to follow these case for the future period in order to record long-term outcome.

Declaration of interest

The authors declare no conflict of interest. This study was not sponsored by any external organization.

References

1. Lindhe J, et al,; Clinical Periodontology and Implant Dentistry. Blackwell Munksgaard. Fourth Edition 2003.
2. Newman MG, et al, Carranza's Clinical Periodontology. Elsevier.
3. Rateitschak EM, Wolf HF: Farbatlanten der Zahnmedizin.Band1: Parodontologie. Thieme
4. Andrew Dentino, Seokwoo Lee, Jason Mailhot and Arthur F. Hefti. (2013) Principles of periodontology. *Periodontology 2000* 61, 16-53.
5. (2011) Comprehensive Periodontal Therapy: A Statement by the American Academy of Periodontology. *Journal of Periodontology* 82:7, 943-949.
6. Caton JG, Greenstein G. Factors related to periodontal regeneration.Periodontol 2000 1993:1:9-15.
7. Dieter D. Bosshardt and Anton Sculean. Does periodontal tissue regeneration really work? *Periodontology 2000* 51:10.1111/prd.2009.51.issue-1, 208-219.
8. Cortellini P, Tonetti MS. Clinical performance of a regenerative strategy for intrabony defects: scientific evidence and clinical experience. J Periodontol 2005; 76:341-350
9. Camelo M, Nevins ML, Lynch SE, Schenk RK, Simion M, Nevins M. Periodontal regeneration with an autogenous bone- Bio-Oss composite graft and a Bio-Gide membrane. Int J Periodontics Restorative Dent 2001:21:109-119.
10. Camelo M, Nevins ML, Schenk RK, Simion M, Rasperini G, Lynch SE, Nevins M. Clinical, radiographic, and histologic evaluation of human periodontal defects treated with Bio-Oss and Bio-Gide. Int J Periodontics Restorative Dent 1998:18:321-331
11. Bosshardt DD. Biological mediators and periodontal regeneration: a review of enamel matrix proteins at the cellular and molecular levels. Journal of Clinical Periodontology.2008; 35 (suplement8):87-105. [PubMed]
12. Esposito M, Grusovin MG, Coulthard P, Worthington HV(2008)Enamel matrix derivative (Emdogain®) for periodontal tissue regeneration in intrabony defects. The Cochrane Library [online serial].Issue1:1-34(Accessed March3, 2008)
13. Hammarström L (1997) Enamel matrix, cementum development and regeneration. J Clin Periodontol24:658-668
14. Bosshardt DD, Sculean A, Windisch P, Pjeturrson BE, Lang NP. Effects of enamel matrix proteins on tissue formation along the roots of human teeth. J Periodontal Res 2005:40:158-167

15. Rathe, F; Junker, R; Chesnutt, B.M.; Jansen J. A2009 The effect of enamel matrix derivative (Emdogain) on bone formation

16. Kasaj A, Willershausen B, Reichert C, Röhrig B, Smeets R, Schmidt M. Ability of nanocrystalline hydroxyapatite paste to promote human periodontal ligament cell proliferation. Journal of Oral Science. 2008; 50(3):279-285. [PubMed]

17. Ivanovic A, Nikou G, Miron RJ, Nikolidakis D, Sculean A. Which biomaterials may promote periodontal regeneration in intrabony periodontal defects? A systematic review of pre-clinical studies. Quintessence Int 2014:45:385-395.

18. Trombelli L, Heitz-Mayfield LJA, Needleman I, Moles D, Scabbia A. A systematic review of graft materials and biological agents for periodontal intraosseous defects. Journal of Clinical Periodontology.2002; 29(supplement3):117-135.[PubMed]

19. Silvestri M, Rasperini G, Milani S. 120 infrabony defects treated with regenerative therapy: long-term results. J Periodontol 2011:82:668-675.

20. Cortellini P, Tonetti MS. A minimally invasive surgical technique with an enamel matrix derivative in the regenerative treatment of intra-bony defects: a novel approach to limit morbidity. J ClinPeriodontol 2007; 34:87-93.

21. Cortellini P, Nieri M, Prato GP, Tonetti MS. Single minimally invasive surgical technique with an enamel matrix derivative to treat multiple adjacent inttra-bony defects: clinical outcomes and patient morbidity. J ClinPeriodontol 2008; 35:605-613.

22. Simone Domenico Aspriello, Luigi Ferrante, Corrado Rubini and Matteo Piemontese. (2011) Comparative study of DFDBA in combination with enamel matrix derivative versus DFDBA alone for treatment of periodontal intrabony defects at 12 months post-surgery. *Clinical Oral Investigations* 15, 225-232.

23. Tonetti MS, Fourmousis I, Suvan J, Cortellini P, Bragger U, Lang NP.Healing, postoperative morbidity and patient perception of outcomes following regenerative therapy of deep intrabony defects. J ClinPeriodontol 2004; 31:1092-1098.

TITLE: **Basics of Gnathology**

AUTHORS: **Muhamed Ajanović, Sanela Strujić-Porović, Azijada Šuljak-Lončarević, Almira Hadžović Džuvo, Lejla Kazazić, Selma Tosum, Lejla Berhamović, Adis Hamzić, Amela Đonlagić, Eldan Kapur**

PUBLISHER: **Faculty of Dentistry with Clinics, University of Sarajevo, Sarajevo, Bosnia and Herzegovina**

LANGUAGE: **Bosnian**

PAGES: **314**

DATE OF ISSUE: **2015**

ISBN: **978-9958-9051-6-2**

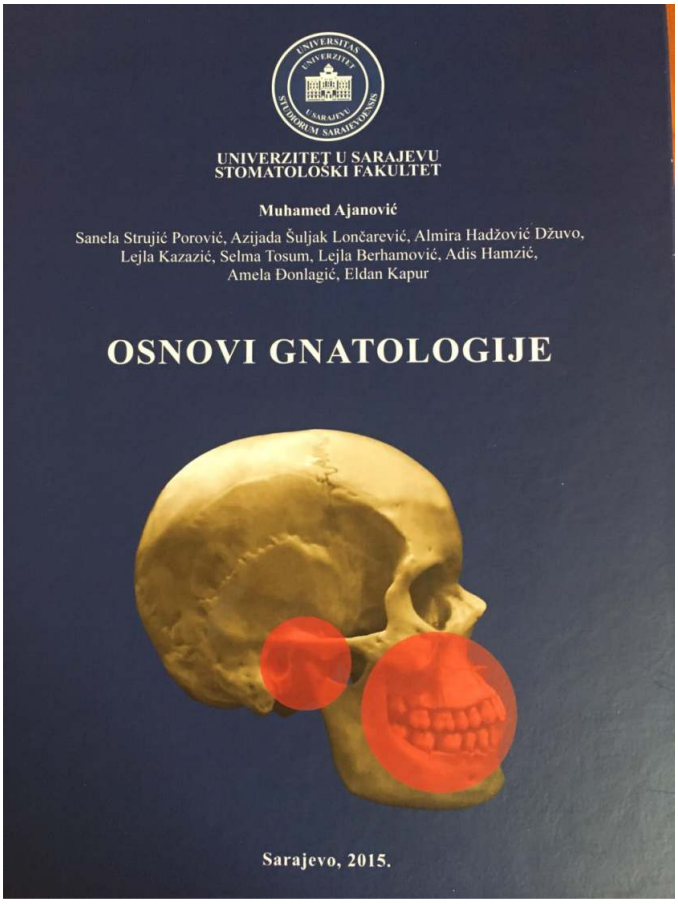

The book Basics of Gnathology deals with issues of occlusion and planned reconstruction of the same. Taking into consideration its topic and as well as high demands connected to function and restoration of occlusion expected from therapist, this book represents an inevitable reference for every doctor of dental medicine.

The book is written in very legible and simple manner, methodologically adjusted to the field it deals with. It is systematically divided into 14 chapters, subsequently elaborated according to unique pattern, providing visibility and better perception for memorizing.

The chapter titled "Stomatognathic System" clearly describes anatomic and morphologic details not only for bones but also of muscles of the system including very clear picture of temporomandibular joint. The following chapters are dealing with movements in temporomandibular joint and central regulation and control of the same.

Further on, one can find chapters about other determinants of the jaw movements, anthropomorphic model and position of head in space. Consequently, the authors direct our attention to the characteristics of optimal occlusion and importance of articulators and facebow as inevitable diagnostic parts of rehabilitation of occlusion.

Such analytic approach to book writing speaks in favor of high appreciation of the knowledge of authors regarding the theme and also of long lasting clinical and lecturing experience. That, in great extent, contributes to overall originality of this text.

List of literature indicates that the book was written according to the newest knowledge in this field. Such systematical book, with chapters mentioned above, will be of a great use for students, specialists and doctors of dental medicine in Bosnia and Herzegovina as well as in the region, taking into consideration insufficiency of domestic literature dealing with the subject.

INSTRUCTIONS FOR THE AUTHORS

made in accordance with the recommendations of the International Committee of Medical Journal based on "Uniform Requirements for Manuscripts Submitted to Biomedical Journals" (http://www.icmje.org/).

Submissions of manuscripts are made through the submission form available at web page of the Journal (www.stomatoloskivjesnik.ba) or by sending the email to Editorial office at radovi@stomatoloski vjesnik.ba

E-mail must be composed of:

A) **Covering letter, in which authors explain the importance of their study** (Explanation why we should publish your manuscript ie. what is new and what is important about your manuscript, etc).

B) **Title of the manuscript**

C) **Authors' names and email addresses** (mark corresponding author with *)

D) **Abstract**

E) **Attached file of the Copyright assignment form and**

F) **Manuscript.**

Authors should NOT in addition post a hard copy of the manuscript and submission letter, unless they are supplying artwork, letters or files that cannot be submitted electronically, or have been instructed to do so by the editorial office.

Please read Instructions carefully to improve yours paper's chances for acceptance for publishing.

Thank you for your interest in submitting an article to Stomatološki vjesnik.

Type of papers suitable for publishing in Stomatološki vijesnik (Journal in following text):

Original Articles, Case Reports, Letters to the Editors, Current Perspectives, Editorials, and Fast-Track Articles are suitable for publishing in Stomatološki vjesnik. Papers must be fully written in English with at least title, abstract and key words bilingual in Bosnian/Croatian/Serbian language (B/C/S) and English language.

Editorial process:

All submitted manuscripts are initially evaluated by at least two scientific and academic members of editorial board. An initial decision is usually reached within 3–7 days.

Submitted manuscripts may be rejected without detailed comments after initial review by editorial board if the manuscripts are considered inappropriate or of insufficient scientific priority for publication in Stomatološki vjesnik.

If sent for review, each manuscript is reviewed by scientists in the relevant field. Decisions on reviewed manuscripts are usually reached within one month. When submission of a revised manuscript is invited following review, the revision must be received in short time of the decision date.

Criteria for acceptance:

Submitted manuscripts may be rejected without detailed comments after initial review by editorial board if the manuscripts are considered inappropriate or of insufficient scientific priority for publication in the Journal. All other manuscripts undergo a complete review by reviewers or other selected experts. Criteria for acceptance include originality, validity of data, clarity of writing, strength of the conclusions, and potential importance of the work to the field of dentistry and similar bio-medical sciences. Submitted manuscripts will not be reviewed if they do not meet the Instructions for authors, which are based on "Uniform Requirements for Manuscripts Submitted to Biomedical Journals" (http://www.icmje.org/).

Authorship:

All authors have to sign the copyright assignment form. We ask all authors to confirm that: they have met the criteria for authorship as established by the International Committee of Medical Journal Editors; they believe that the paper represents honest work, and are able to verify the validity of the results reported.

Redundant or duplicate publication:

We ask the authors to confirm in the copyright assignment form that the paper has not been published in its current form or a substantially similar form (in print or electronically, including on a web site), that it has not been accepted for publication elsewhere, and that it is not under consideration by another publication. The International Committee of Medical Journal Editors has provided details of what is and what is not duplicate or redundant publication (http://www.icmje.org). In the submission letter to the editors, authors are asked to draw attention to any published work that concerns the same patients or subjects as the present paper.

Author Contributions:

Authors are required to include a statement to verify the contributions of each co-author in the copyright assignment form (available at www.stomatoloskivjes nik.ba).

Patient consent forms:

The protection of a patient's right to privacy is essential. The authors may be asked by the editorial board to send copy of patient consent forms on which patients or other subjects of the experiments clearly grant permission for the publication of photographs or other material that might identify them. If the consent form for the research did not specifically include this, authors should obtain it or remove the identifying material.

Ethics committee approval:

The authors must state clearly in the submission letter and in the Methods section that the conducted studies on human participants are with the approval of an appro-priate named ethics committee. Please also look at the latest version of the Declaration of Helsinki (http:// www.wma.net/e/policy/b3.htm). Similarly, the authors must confirm that experiments involving animals adhered to ethical standards and must state the care of animal and licensing guidelines under which the study was perfor-med. The editorial board may ask author(s) for copy of ethical committee approval.

Declaration of Interest:

We ask the authors to state all potential financial support received for the work. This applies to all papers including editorials and letters to the editor (see below). If you are sure that there is no conflict of interest, please state that.

Copyright:

Copyright assignment form contains authors' statement that all the copyrights are transferred to the publisher if and when the manuscript is accepted for publishing.

Subscribers may reproduce tables of contents or prepare lists of articles including abstracts for internal circulation within their institutions. Permission of the Publisher is required for resale or distribution outside the institution and for all other derivative works, including compilations and translations. If excerpts from other copyrighted works are included, the author(s) must obtain written permission from the publisher and credit the source(s) in the article.

Formatting requirements:

Manuscript should be written in Times New Roman 12, Normal, double spacing.

Include the following sections, each starting on a separate page: Title Page, Abstract and Keywords, Text, Acknowledgements, Declaration of interest, References, Individual tables and figures with captions.

Margins should be not less than 3 cm. Pages should be numbered consecutively, beginning with the Title Page, and the page number should be placed in the bottom right hand corner of each page.

Abbreviations should be defined on their first appearance in the text; those not accepted by inter-

national bodies should be avoided. Use only standard abbreviations. Avoid abbreviations in the title and abstract. The full term for which an abbreviation stands should precede its first use in the text unless it is a standard unit of measure-ment.

The Title Page should carry the full title of the paper and a short title to be used as a 'running head' (and which should be so identified). The first name, middle initial and last name of each author should appear marked with superscript numbers or/and symbols corresponding to their affiliation or/and note. Affiliations of the authors should be written below authors name list. Full name, address, phone and fax number and e-mail of the author responsible for correspondence should appear on the Title Page. Please include the word count of the abstract and word count of text on the title page.

The second page should carry a structured **abstract** of no more than 250 words. The abstract should state the Objective(s) of the study or investigation, basic Methods (selection of study subjects or laboratory animals; obser-vational and analytical methods), main Results (giving specific data and their statistical significance, if possible), and the principal Conclusions. It should emphasize new and important aspects of the study or observations.

The abstract should be followed by a list of 3–10 **keywords** or short phrases which will assist the cross-indexing of the article and which may be published. When possible, the terms used should be from the Medical Subject Headings list of the National Library of Medicine (http://www.nlm.nih.gov/mesh/meshhome.html).

Body of the manuscript text of an experimental or observational nature may be divided into sections headed Introduction, Materials and Methods (including ethical and statistical information), Results, Discussion and Conclusion, although reviews may require a different format.

Original Articles: original experimental and clinical studies should not exceed 4400 words (up to 15 pages) including tables and references.

With Case Reports: presentation of a clinical case which may suggest novel working hypotheses, with a short discussion on the pertinent literature. The text should not exceed 2400 words (up to 8 pages).

Letters to the Editors should not exceed 500 words, should not be signed by more than three authors and should not have more than 5 references. Preferably, letters should be in reference to a Journal article published within the last 3 months or to novel hypotheses so as to stimulate comments on issues of common interest. Authors of the letters accepted for publication will receive the galley proofs. The Editors will generally solicit replies. The Editors reserve the right to modify the text.

Current Perspectives: invited articles by recognized authorities, to include position papers, reviews, and special topics of general interest. Independent submission will also be considered.

Editorials: invited articles or brief editorial comments that represent opinions of recognized leaders in biomedical research.

Fast-Track Articles: short articles on laboratory or clinical findings, representing important new insights or major advances, produced with established methods or new applications of an established or new method. The text should not exceed 2400 words.

Acknowledgements: One or more statements should specify (a) contributions that need acknowledging but do not justify authorship, such as general support by a department chairman; (b) acknowledgements of technical help; (c) acknowledgements of financial and material support, specifying the nature of the support. Persons who have contributed intellectually to the paper but whose contributions do not justify authorship may be named and their function or contribution described – for example, 'scientific adviser', 'critical review of study proposal', 'data collection', 'participation in clinical trial'. Such persons must have given their permission to be named. Authors are responsible for obtaining written permission from persons acknowledged by name because readers may infer their endorsement of the data and conclusions.

Declaration of Interest

A statement must be provided listing all financial support received for the work and, for all authors, any

financial involvement (including employment, fees, share ownership) or affiliation with any organization whose financial interests may be affected by material in the manuscript, or which might potentially bias it. This applies to all papers including editorials and letters to the editor. If you are sure that there is no conflict of interest, please state this.

References

References should be numbered consecutively in the order in which they first appear in the text. They should be assigned Arabic numerals, which should be given in brackets, e.g. [17]. References should include the names of all authors when six or fewer; when seven or more, list only the first six names and add et al. References should also include full title and source information (Vancouver style).

Journal names should be abbreviated as in MEDLINE (http://www.medscape.com/Home/Search/ IndexMedicus/IndexMedicus.html).

Examples of citation:

Standard journal article:

Tashiro H, Shimokawa H, Sadamatu K, Yamamoto K. Prognostic significance of plasma concentrations of transforming growth factor-ß. Coron Artery Dis 2002; 13(3):139-143.

More than six authors:

Yetkin E, Senen K, Ileri M, Atak R, Tandogan I, Yetkin Ö, et al. Comparison of low-dose dobutamine stress echocardiography and echocardiography during glucose-insulin-potassium infusion for detection of myocardial viability after anterior myocardial infarction. Coron Artery Dis 2002; 13(3):145-149.

Books:

Heger JW, Niemann JT, Criley JM. Cardiology, 5th ed. Philadelphia: Lippincott, Williams & Wilkins; 2003.

Chapter in a book:

Braunwald E, Perloff JK. Physical examination of the heart and circulation. In; Braunwald E, Zipes DP, Libby P (eds). Heart disease; a textbook of cardiovascular medicine, 6th edn. Philadelphia: WB Saunders; 2001, pp. 45-81.

Personal communications and unpublished work should not feature in the reference list but should appear in parentheses in the text. Unpublished work accepted for publication but not yet released should be included in the reference list with the words 'in press' in parentheses beside the name of the journal concerned. References must be verified by the author(s) against the original documents.

Tables

- Provide each table on a separate page of the manuscript after the references.
- Each table should be typed on a separate sheet in double spacing.
- Number the table according to their sequence in the text. The text should include references to all tables. Each table should be assigned an Arabic numeral, e.g. (Table 3).
- Include a brief and self-explanatory title with explanations essential to the understanding of the table at the bottom of the table.
- Identify statistical measures of variations, such as standard deviation and standard error of the mean or other where appropriate.

Figures

- Provide each figure on a separate page of the manuscript after the references. Number the figures according to their sequence in the text. The text should include references to all figures.
- Graphs and figures should be in black/white or greyscale format. Colour illustrations are acceptable but not guaranteed. Minimal quality 300dpi, figures should be filed in suitable format (*.JPG, *.PNG, .*TIFF)
- If figures are not original provide source and permition.
- All figures should be 100% of a suitable final size and have the printing resolution of 300dpi and be cropped to include the figure only (no blank space).

Units of measurement

Measurements of length, height, weight, and volume should be reported in metric units (meter, kilogram, or liter) or their decimal multiples. All hematologic and clinical chemistry measurements should be reported in the metric system in terms of the International System of Units (SI).

Post acceptance

All correspondence concerning the copy, editing and production of accepted manuscripts should be addressed to Stomatološki vjesnik.

Charges

Authors will not be charged fees in a first year of publishing Stomatološki vjesnik. Optional charges for colour reproduction of figures may apply. Authors will be informed about this when the poof is supplied to them. The charges must be completed before the article is released.