

BRONJ IN DENTAL PRACTICE, CURRENT PERSPECTIVES

Slobodan Trninić^{1*}, Anela Hardaga-Muzurović¹,
Faruk Ljaljević¹

¹ Clinic for Oral Surgery, Faculty of Dentistry with Clinics,
University of Sarajevo, Bolnička 4a Street, 71000 Sarajevo

***Corresponding author**

Slobodan Trninić, DDS, MSc
Oral Surgery Specialist
Clinic for Oral Surgery
Faculty of Dentistry with Clinics
University of Sarajevo
Bolnička 4a Street, 71000 Sarajevo
Bosnia and Herzegovina
Email : drstrninic@gmail.com

ABSTRACT

Mechanism of the bisphosphonates action, especially side effects and complications these medicines can cause in oral cavity, is of great importance to dental medicine doctors in their everyday practice. Unfamiliarity of dental medicine doctors with consequences of bisphosphonate therapy in patients undergoing intensive dental procedures, such as tooth extraction, apicotomia, dental implant placement and periodontal surgery, can cause serious health problems and ultimately damage their health.

Most common complication is Bisphosphonate Related Osteonecrosis of the Jaw (BRONJ).

Osteonecrosis of the jaw is atrophy of the bone matrix with symptoms like pain, tooth mobility and surfaces of bare bones of the jaw, followed by symptoms of infection, both local and systemic.

The purpose of this article is to point out to mostly common complications in everyday dental practice such as consequences of multiple effects of bisphosphonates and to present generally accepted guidelines for prevention, diagnostics and therapy in osteonecrosis of the jaw, being the of bisphosphonate therapy use.

Prevention and early detection are crucial to prevent appearance and frequency of osteonecrosis of the jaw induced by bisphosphonate therapy.

Decision on dental procedures in patients using bisphosphonate therapy must be made in a multidisciplinary way based on the assessment of dental medicine doctor and attending oncologist in order to evaluate whether the planned dental procedure will be more beneficial for the patient than the potential risk or it will additionally endanger already damaged patient's health.

Key words: bisphosphonates, osteonecrosis, tooth extraction, dental practice

Introduction

Bisphosphonates are drugs that are nowadays commonly prescribed, thus increasing the number of patients in everyday dental practice. Faced with the fact that these drugs can cause dangerous complications on the patients' jawbone if exposed to invasive dental procedures, we decided to point at such complications.

Bisphosphonates are drugs used to treat and prevent osteoporosis, Paget's disease of bones (*osteitis deformans*), bone cancer metastasis, metastatic lung cancer, metastatic breast cancer, metastatic prostate cancer, multiple myeloma and malignant hypercalcaemia [1]. It is rather important for the doctors to accept the fact that the bisphosphonate therapy is one of the most common cause of osteonecrosis of the jaw. This type of osteonecrosis is called bisphosphonate-related osteonecrosis of the jaw or bisphosphonate-induced osteonecrosis of the jaws (BION) [2].

Osteonecrosis of the jaw appearing after an invasive dental treatment, such as mostly tooth extraction, at patients using some of the bisphosphonates is usually an irreversible condition heavily influencing the quality of everyday life (feeding, speaking and the ability to maintain dental hygiene become rather difficult) and requiring long-term treatment. Bisphosphonates were firstly mentioned in medicine in the 1960s in the context of metabolic bone disorder [3]. Only in 2003, the world's oral and maxillofacial surgeons recognised and reported about the cases of open bone lesions in maxillofacial region of patients treated with intravenous bisphosphonates which could not be healed [4]. Bisphosphonates are drugs slowing down the activity of osteoclast. Since the dynamic of bone mineralization is conditioned by the balance of osteoblast and osteoclast activities, and by blocking the osteoclast activities, the osteoblast activity which forms the bone becomes dominant, therefore the bone matrix becomes more formed rather than degraded. Due to their physical and chemical properties, they tend to accumulate highly in the bone matrix having very long half-life (longer than ten years) [5, 6]. There are two different kinds of bisphosphonates according to their chemical composition and impact on osteoclasts: nitrogenous and non-nitrogenous bisphosphonates. Non-nitrogenous bisphosphonates urge osteoclasts to initiate apoptosis [3]. The group of non-nitrogenous bisphosphonates is made of etidronate and tiludronate. They are to be taken orally and are mostly used for treating osteoporosis. It has not been noted yet that these bisphosphonates induce bisphosphonate osteonecrosis of the jaws [5]. The group of nitrogenous bisphosphonates is made from pamidronate, alendronate, and zoledronate considered to be the most potent bisphospho-

nates. They are to be taken intravenously and in high doses if disease is malignant. Bisphosphonates that are taken parenterally are usually prescribed to oncological patients and are considered highly potent bisphosphonates that mostly cause BION. Patients that are on parenteral bisphosphonates therapy and undergoing some of the invasive dental procedures have seven times greater risk of getting BION than those not undergoing the treatment [10]. The risk of complications in oral cavity is significantly less if the drug is taken orally, nevertheless, it is necessary to be cautious during the invasive dental procedures.

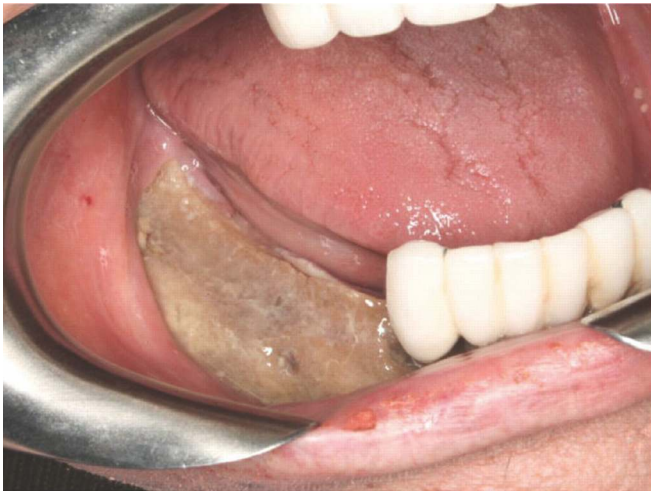
Besides the manner of drug consumption, the length of the therapy, drug doses and type of disease also affect development of osteonecrosis of the jaw significantly [12]. In 37.8 % cases the osteonecrosis of the jaw could be related to previous tooth extraction [7]. It has been proved that taking preventive measures can decrease osteonecrosis of the jaw up to 85% per year [8].

Diagnosis of the osteonecrosis of the jaw is set in the cases when the patient is currently or has recently been using the bisphosphonate therapy, if the clinical intraoral examination shows that the bone is exposed longer than eight weeks, and if there are no anamnestic data on jaw radiotherapy. BION can be asymptomatic, or followed by pain, swelling, tooth loss, or disturbed sensation.

It is necessary to **diagnostically differentiate** between the bisphosphonate osteonecrosis and the following conditions: alveolar osteitis, gingivitis, periodontal disease, fibrous dysplasia, chronic sclerosing osteomyelitis, and bone metastases [13].

Clinical image of the osteonecrosis of the jaw begins with a pathological flow of the post-extraction wound healing process including pain, swelling of soft tissues, and consequently appear ulcers exposing jaw bone (**Picture 1, 2**), extra-oral fistulae (**Picture 3**) and subsequent tooth loss. In more serious cases, pathological fractures of jaw bone are possible (**Picture 4**) [3]. As the disease progresses the above-mentioned symptoms can also be followed by lower lip paraesthesia [9].

Lesions usually appear on mandibula rather than on maxilla, in 2:1 ratio. Most often they appear in places with thinner mucous membrane, bony prominence, such as: torus, exostosis, and mylohyoid line [10]. Besides the local changes, the osteonecrosis of the jaw caused by bisphosphonates can also cause disorder in its function, such as difficulties with chewing, speaking and halitosis [5]. X – ray (retro alveolar image, orthopantomogram, and CBCT) is of significant help when it comes to diagnostics and differential diagnostics of bisphosphonate osteonecrosis.



Picture 1.

Exposed, necrotic bone in the right side of the lower jaw in a breast cancer patient with history of monthly use of bisphosphonate intravenously.

(Taken from: <http://www.nature.com/bonekey/knowledgeenvironment/2011/1103/bonekey20110500/full/bonekey20110500.html?foxtrotcallback=true>; Matthew R Allen, Salvatore L Ruggiero. Osteonecrosis of the jaw: Recent clinical and preclinical advances; *IBMS BONEKey*(2011)8,141-153 (2011); Published online March 2011)

Osteonecrosis of the jaw therapy lasts long, and its success is questionable. There are three treatment methods described in literature: conservative, surgical, and the third one as the combination therapy treatment that can be combined with the conservative or surgical method.

The conservative method implies:

- Mouth rinsing with antibacterial solution, such as: 0.12% chlorhexidine, antibiotics (penicillin and metronidazole combined, or clindamycin in the case of penicillin allergies), antifungal therapy.

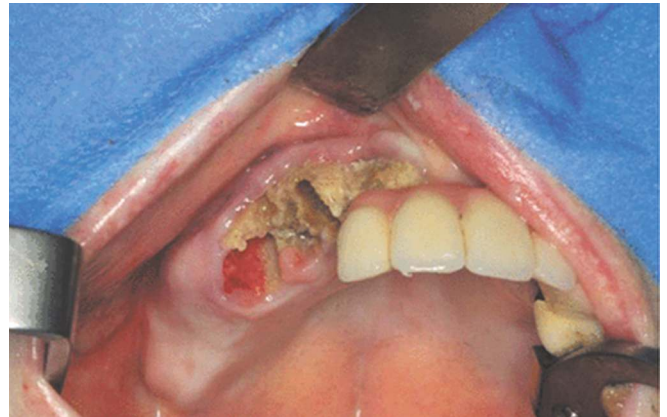The surgical method implies:

- Surgical debridement, sequestration, antrostomy (surgical removal of pathological content from sinuses), extraction of the tooth with the bone affected by osteonecrosis, bone resection, reconstructive surgery.

The additional methods of therapy imply:

- Hyperbaric oxygen therapy, ozone therapy, laser therapy, PRF (platelet-rich fibrin), mesenchymal stem cell therapy [14].

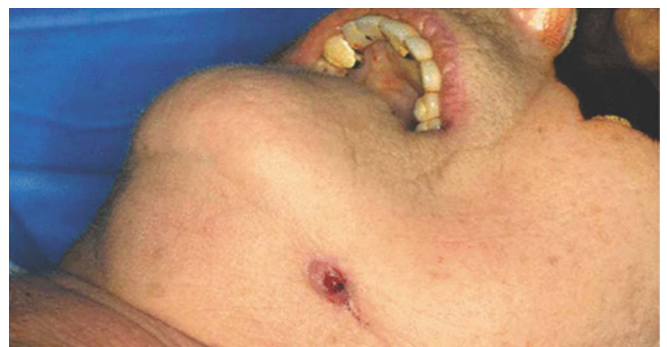The therapy protocol of BION treatment is recommended by The American Association of Oral and Maxillofacial Surgeons (AAOMS) [11].



Picture 2.

Exposed necrotic bone in the right maxilla in a patient who received zoledronate therapy over a period of 23 months. Exposed bone initiated teeth removal.

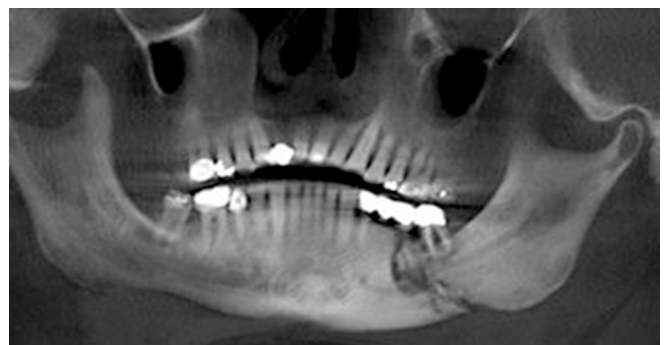
(Taken from: <http://ar.iijournals.org/content/33/9/3917/F1.expansion.html>, Incidence of bisphosphonate-related Osteonecrosis of the Jaw in Consideration of Primary Disease and Comorbid Therapies)



Picture 3.

Extraoral fistula resulting from a necrotic bone lesion of the left mandible in a patient who received pamidronate (Aredia) therapy over a period of 19 months.

(Taken from: <http://ar.iijournals.org/content/33/9/3917/F4.expansion.html>, Incidence of bisphosphonate-related Osteonecrosis of the Jaw in Consideration of Primary Disease and Comorbid Therapies)



Picture 4.

(Taken from: <http://www.rdhmag.com/articles/print/volume-34/issue-7/columns/drug-induced-osteonecrosis-of-the-jaws.html>, Drug-induced osteonecrosis of the Jaws, by Lynne Slim, July 17, 2014)

Table 1. The recommended BION treatment therapy protocol

STAGE 0	STAGE 1	STAGE 2	STAGE 03
Patients without clinical evidence of exposed necrotic bone, but with specific symptoms, in which case the therapy could be recommended.	Asymptomatic patients and patients who have no presence of infection.	Patient with clinical image of the presence of exposed bone followed by an infection, pain, swelling, and skin redness in the region of the exposed bone and with or without pus discharge.	Patient with the exposed bone followed by pain, infection and pathological fracture or extraoral fistula.
	Th : antibacterial mouthwash, clinical examination every three months, patient education, and consideration of the indications for the bisphosphonates therapy.	Th : symptomatic treatment with oral antibiotics, rinsing with antibacterial mouthwash, pain control, surface debridement for eliminating soft tissue irritation.	Th : antibiotics treatment, pain control, rinsing with antibacterial mouthwash, surgical debridement/ resection for long-lasting palliation and pain infection.

Conclusion

The role of dentist managing the treatment of patients on bisphosphonates therapy is utterly important. Anamnesis is the key imperative in working with this group of patients. The dentist should recognize all pathological conditions in the oral cavity that could lead to osteonecrosis of the jaw during the bisphosphonates therapy and determine the therapy plan for every patient based on their professional clinical opinion. If the patient reaches the dentist with already developed clinical image of the osteonecrosis of the jaw, the dentist must recognize and diagnose it and refer the patient to the appropriate specialist institution.

Biological efficiency is significantly weaker in the case of bisphosphonates taken *per os* and percentage of probability for the osteonecrosis of the jaw is quite lower with these bisphosphonates rather than parenteral bisphosphonates.

In our opinion, the cooperation between medical doctor and oncology, dental medicine doctor and dental surgery specialists is crucial for the patient's benefit through offering the patient undergoing the invasive dental procedure, such as tooth extraction, information

about the bisphosphonates therapy. Invasive dental procedures should be planned at least one month prior to starting the bisphosphonates therapy. If the situation, i.e. the current condition of the patient, does not allow therapy interruption, the respective precautions should be taken, such as:

- Preoperative antibiotic prophylaxis, thorough operational technique, primary wound closure, detailed instructions on dental hygiene.

In the beginning, regular examinations should be as frequent as possible, and later on, in the case of improvement of the condition, examinations are recommended every three months.

There is no data indicating that the interruption of treatment lowers the risk of osteonecrosis of the jaw development, because some bisphosphonates have long half-life (Zometa, 11 years), i.e. one of their pharmacokinetic properties is long retention in the bone. For the patients orally taking the bisphosphonates therapy lasting less than three years it is not necessary to postpone the invasive dental procedures. However, the procedures should be taken with caution.

References:

1. Ruggiero SL, Dodson TB, Assael LA, Linderberg R, Marx RE. American Association of Oral and Maxillofacial Surgeons. Position Paper on Bisphosphonate-Related Osteonecrosis of the Jaws – 2009;67:2-12.
2. Marx RE. Pamidronate (Aredia) and Zoledronate (Zometa) induced avascular necrosis of the jaw: a growing epidemic. *J Oral Maxillofac Surg.* 2009; 61:1115-7.
3. Robert E Marx. Oral and Intravenous Bisphosphonate Induced Osteonecrosis of the Jaws : History, Etiology, Prevention and Treatment. Chicago: Quintessence Publishing Co. Inc; 2007:150.
4. A time for perspective on bisphosphonates. (Editorial) *Journal of Oral and Maxillofacial surgery.* 2006;64:877-9
5. Badel T, Keros J, Krapac L, Savić Pavićin J. Povezanost osteonekroze vilica i terapije bisfosfonatima. 2010;61:371-380.
6. [http:// farmaceuti.com/tekstovi/farmakologija/-preparati-za-liječenje-bolesti-kostiju/](http://farmaceuti.com/tekstovi/farmakologija/-preparati-za-liječenje-bolesti-kostiju/)
7. Abu- Id MH, Warnke PH, Gottschalk J, Springer I, Wiltfang J, Acil Y. Bis-phosphy jaws - high and low risk factors for bisphosphonate induced osteonecrosis of the jaws – I Craniomaxillofacial surgery 2008;36:95-103.
8. Ripamonti C, Maniezzo M, Cistaghi E, et al. Application of preventive measures minimize the occurrence of the osteonecrosis of the Jaw in solid tumors patients with bone metastases treated with Bisphosphonate: a single institution series. Presented at 28th Annual San Antonio Breast Cancer Symposium. December 2005.
9. Yaeom N, Lazarević TS, Elad S. Oral Bisphosphonate – related jaw necrosis- severe complication in Maxillofacial surgery. *Comon Treat Rev* 2007;33:58-63.
10. Šebečić V, Brajdić D. Što bi stomatolog trebao znati o bisfosfonatima. *Sonda.* 2008;16:48-51.
11. American Association of Oral and Maxillofacial Surge. Position paper on bisphosphonate related osteonecrosis of the jaws. Accessed Juni 2010.
12. Silverman SL, Landerberg R. Osteonecrosis of the jaws and the role of bisphosphonates: a critical review *Journal Med* 2009;122:533-545
13. Sididiqi A, Payne AG, Zafar S. Bisphosphonate-induced osteonecrosis of the jaw: a medical enigma? *Oral Surg Oral Med Oral Pathol Oral Radiol Endod.* 2009 Sep; 108(3):e1-8.
14. Rollason V, Laverrière A, MacDonald LCI, Walsh T, Tramèr MR, Vogt-Ferrier NB. Interventions for treating bisphosphonate-related osteonecrosis of the jaw (BRONJ). *Cochrane Database of Systematic Reviews* 2016, Issue 2. Art. No.: CD008455.