

Stomatološki vjesnik

Stomatological review



Stomatološki vjesnik 2025; 14 (2)

STOMATOLOŠKI VJESNIK / STOMATOLOGICAL REVIEW

ISSN 2233-1794 (online) UDK 616.31

Izdavač / Publisher:

Stomatološki fakultet sa Klinikama Univerziteta u Sarajevu / Faculty of Dentistry with Clinics, University of Sarajevo
Udruženje stomatologa u Federaciji BiH/ Association of Dentists in the Federation of BiH

ČLANOVI UREĐIVAČKOG ODBORA / EDITORIAL BOARD:

Glavni urednik / Editor in chief: Mirjana Gojkov Vukelić

Sekretar uređivačkog odbora / Secretary of editorial board: Selma Zukić

Članovi / Members: Muhamed Ajanović, Mediha Selimović Dragaš, Selma Zukić, Vildana Džemidžić, Sanela Strujić Porović, Alma Konjhodžić, Sanja Hadžić, Sadeta Šečić, Lejla Kazazić, Sedin Kobašlija, Verica Pavlić, Nikola Stojanović.

MEĐUNARODNI UREĐIVAČKI ODBOR / INTERNATIONAL EDITORIAL BOARD: Anwar Barakat Bataineh (Irbid, Jordan), Jasenka Živko-Babić (Zagreb, Hrvatska), Andrija Petar Bošnjak (Rijeka, Hrvatska), Hrvoje Brkić (Zagreb, Hrvatska), Dolores Biočina Lukenda (Split, Hrvatska), Davor Katanec (Zagreb, Hrvatska), Šahza Hatibović Koffman (London Ontario Kanada), Mladen Kuftinec (USA), Darko Macan (Zagreb, Hrvatska), Berislav Perić (Zagreb, Hrvatska), Tore Solheim (Oslo, Norveška), Dragoslav Stamenković (Beograd, Srbija), Marin Vodanović (Zagreb, Hrvatska), Dobrila Lazareva (Skoplje, Makedonija)

Lektor za engleski jezik / English language editor: Nermana Bičakčić

Tehničko uređenje / Technical editor: Branislav Trogranić

Dizajn naslovnice / Cover page design: Lana Malić

KONTAKT / CONTACT:

Stomatološki vjesnik
Stomatološki fakultet sa klinikama
Bolnička 4a, 71000 Sarajevo
Bosna i Hercegovina

Telefon: + 387(33)443269
e-mail: glavni_urednik@stomatoloskivjesnik.ba
Web: www.stomatoloskivjesnik.ba

TRANSAKCIJSKI RACUN / TRANSFER ACCOUNT:

33386902296551066 UniCredit Bank dd

Printed on acid free paper



Svrha i cilj:

Stomatološki vjesnik je neprofitni naučno-stručni časopis koji publicira originalne naučne radove, prikaze slučajeva, pisma uredniku, savremene perspektive, editorijale, preliminarne komunikacije u oblasti stomatologije i drugih biomedicinskih nauka. Radovi su na engleskom jeziku. Radovi se mogu koristiti u edukacijske svrhe bez predhodnog odobrenja, a uz obavezno navođenje izvora. Korištenje cijelih ili dijelova članaka u komercijalne svrhe nije dozvoljeno bez predhodnog pismenog odobrenja izdavača.

Časopis je "open access", što znači da je kompletan sadržaj dostupan bez posebnog plaćanja svim korisnicima ili njihovim institucijama. Korisnicima je dozvoljeno da čitaju, preuzimaju, kopiraju, ispisuju, pretražuju ili povezuju cijele tekstove članaka objavljenih u časopisu bez traženja prethodne saglasnosti izdavača. Autorska prava posjeduje izdavač.

Aim and Scope:

Stomatološki vjesnik / Stomatological review is a non-profit scientific journal that publishes original articles, case reports, letters to the editors, current perspectives, editorials, fast-track articles in a field of dentistry and other bio-medical sciences. Papers are in English. All manuscripts undergo the peer review process before can be accepted for publishing in Stomatološki vjesnik/ Stomatological review. Papers can be used for educational purposes without prior consent only with adequate citation of the sources. Using whole or parts of articles for commercial purposes is not permitted without prior written permission of the publisher.

This is an open access journal which means that all content is freely available without charge to the user or his/her institution. Users are allowed to read, download, copy, distribute, print, search, or link to the full texts of the articles in this journal without asking prior permission from the publisher or the author. This is in accordance with the BOAI definition of open access. Copyright owns the publisher.

Časopis Stomatološki vjesnik je oslobođen poreza na promet prema mišljenju Federalnog ministarstva obrazovanja, nauke, kulture i sporta br: 04-15-661/2002.

Journal Stomatological review is tax exempt according to the opinion of the Federal Ministry of Education Science Culture and Sports no: 04-15-661/2002.

Indexed in: ICV 2021 = 72.91 ICV 2022 = 77.14 (Index Copernicus International), DOAJ (Directory of Open Access Journal), EZB (Elektronische Zeitschriftenbibliothek), SJIF (Scientific Journal Impact Factor Value 7.669)

Stomatološki vjesnik

CONTENTS

ORIGINAL SCIENTIFIC ARTICLES

ASSESSMENT OF ORAL HYGIENE IN THE PREVENTION OF GINGIVITIS AMONG STUDENTS OF THE FACULTY OF DENTISTRY AND OTHER FACULTIES OF THE UNIVERSITY OF SARAJEVO

Ema Jakubović, Azra Prcanović, Sanja Hadžić, Mirjana Gojkov Vukelić, Enes Pašić, Arma Muharemović, Indira Mujić Jahić 2

CBCT ANALYSIS OF MORPHOLOGICAL AND ANTHROPOMETRIC PARAMETERS OF THE TEMPOROMANDIBULAR JOINT IN PATIENTS WITH DIFFERENT DENTAL STATUS

Sanela Strujić - Porović, Muhamed Ajanović, Selma Tosum Pošković, Lejla Kazazić, Alma Gavranović Glamoč, Lejla Berhamović, Selma Zukić, Almir Dervišević, Katarina Palac, Alma Kamber 00

REVIEW ARTICLE

GINGIVAL DEPIGMENTATION WITH ER:YAG LASER: WHAT IS NEW?

Verica Pavlic, Koji Mizutani, Risako Mikami, Tijana Adamovic, Smiljka Cicmil, Sasa Dabic, Mirjana Gojkov Vukelić, Akira Aoki 20

CASE REPORT

PERIODONTAL SPLINTING – AN ADJUNCT TO NON-SURGICAL PERIODONTAL THERAPY FOR TEETH WITH INCREASED MOBILITY

Anisa Zoronjić, Sanja Hadžić, Arma Muharemović, Mia Hodžić, Zerina Kučinar, Indira Mujić Jahić 27

FROM HOPELESS TO REGENERATED: SUCCESSFUL PRESERVATION OF A TOOTH WITH MASSIVE PERIAPICAL LESION IN AN ADOLESCENT

Begović Adna, Hasić-Branković Lajla, Korać Samra, Ljaljević Faruk, Pašić Mirna, Halilović Mehinović Madžida 34

NON-SURGICAL ENDODONTIC SUCCESS IN ACUTE APICAL ABSCESS WITH LARGE PERIAPICAL LESION: IS SURGERY ALWAYS NECESSARY?

Konjhodžić Alma, Pašić Mirna, Džanković Aida, Begović Adna, Halilović Mehinović Madžida, Prčić Iman 44

INSTRUCTIONS FOR THE AUTHORS 49

ASSESSMENT OF ORAL HYGIENE IN THE PREVENTION OF GINGIVITIS AMONG STUDENTS OF THE FACULTY OF DENTISTRY AND OTHER FACULTIES OF THE UNIVERSITY OF SARAJEVO

Ema Jakubović¹, Azra Prčanović¹, Sanja Hadžić²,
Mirjana Gojkov Vukelić², Enes Pašić²,
Arma Muharemović², Indira Mujić Jahić*²

¹ Sixth-year students, Faculty of Dentistry, University of Sarajevo

² Department of Oral Medicine and Periodontology, Faculty of Dentistry, University of Sarajevo

DOI 10.69559/issn.2233-1794.2025.14.2.1

*Corresponding author

Indira Mujić Jahić

Bolnička 4a, 7100 Sarajevo

Email: imujic@sf.unsa.ba

Phone: +387(33)214264

ORCID:

<https://orcid.org/0000-0003-1534-9099>

ABSTRACT

InThe aim of this study was to analyze oral hygiene maintenance habits and the correctness of applying oral hygiene methods among students of the Faculty of Dentistry and students of other faculties at the University of Sarajevo, with focus on assessing the importance of oral hygiene in the prevention of gingivitis.

Materials and methods: The study included 30 students from the Faculty of Dentistry and 30 students from other faculties. The age of participants ranged from 21 to 26 years. All participants signed informed consent for voluntary participation prior to the examination. Data were recorded on specially designed forms. Inclusion criteria were systemic health and absence of ongoing therapy. All participants answered questions regarding harmful habits, oral hygiene practices, and regular dental visits. A clinical examination of the gingiva was performed, including the assessment of periodontal indices and diagnostic tests.

Results: Dental students demonstrated better oral hygiene habits and gingival health compared to students from other faculties. Plaque, calculus, and gingival index values were lower among dental students, while signs of gingival inflammation—such as redness, smooth surface, and a positive Pitting test—were more common among students of other faculties. Dental students more frequently used interdental cleaning aids and regularly visited the dentist, indicating a higher level of knowledge and awareness regarding oral health.

Conclusion: The results confirm that education plays a key role in maintaining oral health and highlight the need for preventive and educational programs even among populations not belonging to the dental profession.

Keywords: student, oral hygiene, harmful habits.

Introduction

Gingivitis caused by poor oral hygiene, along with dental caries, is among the most common diseases in school-aged and student populations [1, 2]. Numerous reports from various countries describe studies on oral health, knowledge, and behaviors among dental students [3, 4, 5]. However, few studies have assessed the awareness of dental students regarding gingival health by comparing their clinical parameters and self-assessments with those of students from other faculties [1].

Plaque accumulation along the gingival margin leads to gingival inflammation [6, 7]. This inflammatory condition, known as gingivitis, is characterized by gingival redness, edema, and bleeding on probing, without visible loss of alveolar bone or supporting tooth structures [8, 9]. Based on epidemiological and experimental studies, dentists recommend effective oral hygiene to control dental plaque and maintain optimal oral health [10].

Educating students about their oral health increases awareness of oral hygiene as the most important measure in preventing gingivitis [11]. This research focuses on assessing the level of oral hygiene among students of the Faculty of Dentistry compared to students of other faculties at the University of Sarajevo, with special emphasis on the importance of oral hygiene education in the prevention of gingivitis and further progression of periodontal diseases.

The aim of the study was to analyze oral hygiene maintenance habits and the correctness of applying oral hygiene methods among students of the Faculty of Dentistry and students from other faculties of the University of Sarajevo, with special emphasis on evaluating the importance of oral hygiene in the prevention of gingivitis.

Materials and Methods

The study included 30 students of the Faculty of Dentistry and 30 students from other faculties of the University of Sarajevo. The research was approved by the Ethics Committee of the Faculty of Dentistry with the Dental Clinical Center in Sarajevo, no: 02-3-4-19-2-3/2024, dated 14.02.2024.

The age of participants ranged from 20 to 26 years. All participants signed informed consent for voluntary participation prior to the examination. Data collected during the examination were entered into specially designed forms created for this study, without recording participants' names.

The research was conducted during student practical sessions in the summer semester of the 2023/2024 academic year. Inclusion criteria were:

- > systemic health,
- > no chronic disease therapy,
- > no antibiotic use in the past 6 months,
- > no professional dental cleaning in the past 6 months.

Exclusion criteria were:

- > presence of systemic disease,
- > current use of any therapy,
- > antibiotic use within the past 6 months,
- > professional dental cleaning within the past 6 months.

This study was designed as a cross-sectional study.

All participants answered questions regarding harmful habits, oral hygiene practices, and regular dental visits. A clinical gingival examination was performed, including the assessment of periodontal indices and diagnostic tests.

Statistical Analysis

The data were processed using standard statistical methods with the SPSS statistical software package (Statistical Package for Social Sciences), version 21.0. Results were presented as mean value (\bar{X}) and standard deviation (SD), as well as absolute numbers and percentages. The Shapiro–Wilk test was used to assess deviations from normal distribution. Since numerical variables followed a normal distribution, the results were analyzed using the student's t-test. The chi-square test or Fisher's exact test was used to analyze the relationship between categorical variables. A p-value of <0.05 was considered statistically significant.

Table 1.
Demographic characteristics and oral hygiene in the examined groups

Variable	Group 1 – students from other faculties	Group 2 – students of the faculty of Dentistry	p
Gender			
Male	10 (33,3%)	11 (36,1%)	0,662
Female	20 (66,7%)	19 (61,3%)	
Year of study			
First year	5 (16,7%)	0 (0,0)	–
Second year	4 (13,3%)	0 (0,0)	
Third year	10 (33,3%)	0 (0,0)	
Fourth year	5 (16,7%)	10 (33,3%)	
Fifth year	6 (20,0%)	7 (22,6%)	
Sixth year	0 (0,0)	14 (45,2%)	
Oral hygiene			
Toothbrush and toothpaste	8 (26,7%)	0 (0,0%)	–
Toothbrush, toothpaste, and dental floss	8 (25,8%)	9 (30,0%)	
Toothbrush, toothpaste, and interdental brushes	3 (10,0%)	7 (22,6%)	
Toothbrush, toothpaste, and mouthwash	4 (13,3%)	1 (3,2%)	
All combined	6 (20,0%)	15 (48,4%)	
Frequency of brushing			
1x	1 (3,3%)	1 (3,2%)	–
2x	19 (61,3%)	21 (70,0%)	
3x	6 (20,0%)	9 (29,0%)	
3x	2 (6,7%)	2 (6,6%)	
4 Brushing duration			
Up to 3 minutes	22 (71,0%)	23 (76,7%)	–
From 3 to 5 minutes	5 (20,0%)	8 (25,6%)	
Longer than 5 minutes	1 (3,3%)	1 (3,2%)	
Dental visits			
As needed	7 (23,3%)	4 (12,9%)	0,233
Every 6 months	6 (20,0%)	13 (41,9%)	
Every 3 months	12 (40,0%)	8 (25,8%)	
Once a year	5 (20,0%)	6 (19,4%)	
Smoking			
	12 (40,0%)	9 (29,0%)	0,367

The results are presented as absolute numbers (N) and as percentage values (%).

Table 2.
Plaque index, calculus index, and gingival bleeding index in the examined groups

Variable	Group 1 – students from other faculties	Group 2 – students of the faculty of Dentistry	p
Plaque index	1,40±0,14	0,64±0,09	<0,001
Calculus index	1,40±0,20	0,58±0,09	0,004
Gingival bleeding index	2,03±0,23	1,03±0,17	0,002

The results are presented as mean ± standard deviation ($\bar{X} \pm SD$).

Results

The plaque index in the group of students from other faculties was 1.4 ± 0.14 , which was statistically significantly higher than the plaque index value in the group of dental students, 0.64 ± 0.09 ($p < 0.001$). The calculus index in the group of students from other faculties was 1.40 ± 0.20 , which was statistically

significantly higher than the calculus index value in the group of dental students, 0.58 ± 0.09 ($p = 0.004$).

The gingival bleeding index in the group of students from other faculties was 2.03 ± 0.23 , which was statistically significantly higher than the value recorded in the group of dental students, 1.03 ± 0.17 ($p = 0.002$) (Table 2).

Table 3.
Results of dental examination and oral hygiene assessment

Variable	Group 1 – students from other faculties	Group 2 – students of the faculty of Dentistry	p
Gingival color			
Normal	10 (33,3%)	24 (77,4%)	0,001
Intensely red	5 (16,7%)	0 (0,0%)	
Mildly red	15 (50,0%)	7 (22,6%)	
Gingiva			
Stippled (orange peel)	7 (23,3%)	22 (71,0%)	–
Smooth, shiny	20 (66,7%)	9 (29,0%)	
Enlarged	3 (10,0%)	0 (0,0%)	
Positive Pitting Test	14 (46,7%)	3 (9,7%)	
Student self-assessment			
Excellent	4 (13,3%)	11 (35,5%)	0,001
Good	23 (76,6%)	17 (54,8%)	
Insufficient	3 (10,0%)	2 (6,3%)	
Poor	0 (0,0%)	1 (3,2%)	
Assessment by the dentist			
Excellent	0 (0,0%)	11 (35,5%)	–
Good	14 (46,7%)	19 (61,3%)	
Insufficient	14 (46,7%)	1 (3,2%)	
Poor	2 (6,7%)	0 (0,0%)	

The results are presented as absolute numbers (N) and percentages (%).

Normal gingival color in the group of students from other faculties was recorded in 10 participants (33.3%), while in the group of dental students it was recorded in 24 participants (77.4%).

Intensely red gingival color in the group of students from other faculties was present in 5 participants (16.7%), whereas no such cases were recorded among dental students.

Mildly red gingival color was observed in 15 participants (50.0%) in the group of students from other faculties, compared to 7 participants (22.6%) in the group of dental students. The difference in gingival color between the examined groups was statistically significant ($p = 0.001$).

Stippled (orange peel) gingiva was most commonly recorded in the group of dental students, with a frequency of 22 (71.0%), whereas **smooth, shiny gingiva** was predominant in the group of students from other faculties, recorded in 20 (66.7%).

A **positive Pitting test** was found in 14 participants (46.7%) in the group of students from other faculties, compared to only 3 participants (9.7%) in the group of dental students. The difference in the frequency of positive Pitting test findings between the groups was statistically significant ($p = 0.001$).

Good oral hygiene (self-assessed) was most frequently reported among students from other faculties, recorded in 23 participants (76.6%), whereas in the group of dental students it was reported in 17 participants (54.8%).

Good and insufficient oral hygiene assessed by the dentist was most frequent in the group of students from other faculties, recorded in 14 participants (46.7%).

Good oral hygiene assessed by the dentist was most frequent in the group of dental students, recorded in 19 participants (61.3%).

Discussion

The results of this study showed that students of the Faculty of Dentistry exhibited significantly better oral hygiene parameters and periodontal status compared to students from other faculties. Plaque index, calculus index, and gingival bleeding index values were significantly lower among dental students ($p < 0.001$; $p = 0.004$; $p = 0.002$), indicating a higher level of

awareness regarding the importance of regular oral hygiene and the prevention of periodontal diseases.

These findings are consistent with previous studies demonstrating that dental students, due to their education and professional orientation, pay more attention to oral health and proper hygiene techniques [12, 13].

Rahman and Kawas reported that dental students in the United Arab Emirates had better oral health and a lower prevalence of gingivitis compared to the general population, which was attributed to greater education and knowledge of periodontal disease etiology [5].

Similar results were reported by Khami et al., who noted that dental students develop positive habits and awareness of oral hygiene early in their studies, while students from other faculties often maintain oral hygiene irregularly and without adequate tools [4].

Our findings, showing that almost half of dental students (48.4%) used all available oral hygiene aids (toothbrush, dental floss, interdental brushes, and mouthwash), support this trend.

In contrast, among students from other faculties, the basic form of hygiene—using only a toothbrush and toothpaste—was dominant (26.7%), indicating limited awareness of the importance of interdental cleaning.

This pattern aligns with the findings of AlGhamdi et al., who showed that oral hygiene habits among high school students in Saudi Arabia are generally poor, with a high prevalence of gingivitis and early periodontal disease [12, 13].

Plaque and calculus index values in our study were directly related to poorer hygiene habits and lower levels of knowledge on periodontal diseases, consistent with findings by Baiju et al., who identified low education and irregular brushing as predictors of early periodontal changes in adolescents [11]. These results further confirm the etio-pathogenic role of dental plaque and calculus in the development of gingival inflammation, which has been described in classical studies by Löe et al. (10) and in modern research by Kornman [6] and Trombelli et al. [9]. Clinical analysis of gingival conditions showed that normal gingival color and texture (“orange peel”) were significantly more frequently recorded among dental

students, whereas red and smooth gingiva, as well as positive Pitting test results, were considerably more common in students from other faculties ($p = 0.001$).

These differences indicate the presence of inflammatory changes in individuals with poorer oral hygiene and confirm the association between clinical parameters and plaque and gingival bleeding indices. Similar correlations were reported by Krüger et al., who found that hygiene habits, brushing frequency, and regular dental check-ups are key factors in maintaining gingival health [2].

An important finding of this study is that students from other faculties most often visited the dentist "as needed" (23.3%), while dental students visited the dentist more regularly, every three to six months. This corresponds with findings by Kawamura et al., who showed that cultural and educational factors significantly influence dental habits and behaviors among students in various countries [4].

No significant difference in brushing frequency was observed between the groups, suggesting that frequency alone is not sufficient if technique and additional hygiene aids are not properly used. Baser et al. also emphasized the discrepancy between self-perceived hygiene and objective clinical findings, which our results confirm—students from other faculties most frequently rated their own hygiene as "good," although clinical measurements showed higher levels of plaque, calculus, and gingival bleeding [1].

In a broader context, our findings confirm that education plays a crucial role in the prevention and control of periodontal disease. Regular education, practical training in proper oral hygiene, and motivation for routine dental check-ups should be part of preventive programs even for non-dental students. This could help reduce the prevalence of gingivitis and early periodontal disease in young adults, as previously noted by AlGhamdi et al. and Baiju et al. [11, 12, 13].

Conclusion

The results of this study clearly indicate that students of the Faculty of Dentistry have significantly better oral hygiene and gingival health compared to students from other faculties. Lower plaque, calculus,

and gingival index values among dental students reflect a higher level of knowledge, awareness, and correct implementation of oral hygiene habits. In contrast, students from other faculties showed more pronounced signs of gingival inflammation, greater presence of dental plaque and calculus, and less frequent use of additional hygiene aids such as dental floss and interdental brushes.

The findings confirm that education and professional awareness play a key role in forming proper hygiene habits and preventing periodontal disease. These results highlight the need to introduce preventive and educational oral health programs even among non-dental students to increase awareness about the importance of regular hygiene and timely dental check-ups.

Further studies with a larger sample size and additional parameters—such as knowledge level, attitudes, and motivation toward oral health—could contribute to better understanding of how education and behaviors influence the periodontal status of young adults.

Acknowledgments

We would like to express our sincere gratitude to all the students who participated in this study for their time and cooperation. We also thank the Faculty of Dentistry, University of Sarajevo, for providing the facilities and support necessary to conduct this research. Special thanks go to our colleagues and mentors at the Department of Oral Medicine and Periodontology for their guidance, expertise, and valuable feedback throughout the study. Their contributions were essential for the successful completion of this work.

Declaration of Interest:

The authors declare that there are no conflicts of interest regarding the publication of this paper.

References:

1. Baser U, Germen M, Erdem Y, Issever H, Yalcin F. Evaluation of gingival bleeding awareness by comparison of self-reports and clinical measurements of freshman dental students. *Eur J Dent*. 2014 Jul;8(3):360-365.
2. Krüger MSDM, Casarin RP, Gonçalves LB, Pappen FG, Bello-Correa FO, Romano AR. Periodontal Health Status and Associated Factors: Findings of a Prenatal Oral Health Program in South Brazil. *Int J Dent*. 2017; 2017:3534048.
3. Khami MR, Virtanen JI, Jafarian M, Murtomaa H. Oral health behaviour and its determinants amongst Iranian dental students. *Eur J Dent Educ* 2007; 11:42-7.
4. Kawamura M, Yip HK, Hu DY, Komabayashi T. A cross-cultural comparison of dental health attitudes and behaviour among freshman dental students in Japan, Hong Kong and West China. *Int Dent J* 2001; 51:159-63.
5. Rahman B, Kawas SA. The relationship between dental health behavior, oral hygiene and gingival status of dental students in the United Arab Emirates. *Eur J Dent* 2013; 7:22-7.
6. Kornman KS. Mapping the pathogenesis of periodontitis: a new look. *J Periodontol*. 2008;79(8 Suppl):1560-8.
7. Murakami S, Mealey B, Mariotti A, Chapple L. A new classification scheme for periodontal and peri-implant diseases and conditions – Introduction and key changes from the 1999 classification. *J Clin Periodontol*. 2018;45(Suppl 20):S17–S27.
8. Nagy R, Novak M. Chronic Periodontitis. In: Carranza A, Newman G, Takei H *Clinical Periodontology*. 9th ed. Philadelphia: EB Saunders Co.; 2002. p. 398.
9. Trombelli L, Farina R, Silva C, Tatakis D. Plaque induced gingivitis: Case definition and diagnostic considerations. *J Clin Periodontol*. 2018;45(Suppl 20):S44–S66.
10. Løe H, Anerud A, Boysen H, Morrison E. Natural history of periodontal disease in man. Rapid, moderate and no loss of attachment in Sri Lankan laborers 14 to 46 years of age. *J Clin Periodontol*. 1986; 13:431–45.
11. Baiju RMP, Peter E, Nayar BR, Varughese JM, Varghese NO. Prevalence and predictors of early periodontal disease among adolescents. *J Indian Soc Periodontol*. 2019 Jul-Aug;23(4):356-361.
12. AlGhamdi AS, Almarghlani AA, Alyafi RA, Kayal RA, Al-Zahrani MS. Gingival health and oral hygiene practices among high school children in Saudi Arabia. *Ann Saudi Med*. 2020 Mar-Apr;40(2):126-135.
13. AlGhamdi A, Almarghlani A, Alyafi R, Ibraheem W, Assaggaf M, Howait M, Alsofi L, et al. Prevalence of periodontitis in high school children in Saudi Arabia: a national study. *Ann Saudi Med*. 2020 Jan-Feb;40(1):7-14. Society of India. 2016; 65:164–166.

CBCT ANALYSIS OF MORPHOLOGICAL AND ANTHROPOMETRIC PARAMETERS OF THE TEMPOROMANDIBULAR JOINT IN PATIENTS WITH DIFFERENT DENTAL STATUS

Sanela Strujić - Porović^{1*}, Muhamed Ajanović¹, Selma Tosum Pošković¹, Lejla Kazazić¹, Alma Gavranović Glamoč¹, Lejla Berhamović¹, Selma Zukić³, Almir Dervišević², Katarina Palac¹, Alma Kamber¹

DOI 10.69559/issn.2233-1794.2025.14.2.2

Short title: CBCT TMJ AND DENTAL STATUS

Word count of the abstract: 271

Word count of text: 3225

*Corresponding author

Sanela Strujić - Porović, PhD
University of Sarajevo
- Department of Prosthodontics and Dental Implantology,
Faculty of Dentistry
University of Sarajevo
Bolnička 4a, Sarajevo,
Bosnia and Herzegovina
Phone: + 387 61 144 350
e-mail: sstrujic@sf.unsa.ba

ABSTRACT

Objective: Investigate the relationship between age, gender and dental status with changes in the osseous structures of the TMJ.

Material and Methods: The study included 110 CBCT images of patients. According to age, the CBCT images of patients were divided into three groups: 20-40 years old, 40-60 years old, group over 60 years old. According to dental status, the images of patients were divided according to the Eichner's classification I, II and III. Analysis and measurements, vertical, linear and angular were performed on CBCT images: condylar morphology, medio-lateral and antero-posterior width condyles, height and inclination of the articular eminence and depth of the glenoid fossa.

Results: One-way ANOVA revealed no statistically significant differences in any TMJ measurements across Eichner classes I, II, and III and between the different age groups. Significant difference was observed for antero-posterior condylar width between the age groups ($p = 0.016$). Males showed significantly greater medio-lateral condylar width ($p = 0.0006$), as well as a larger articular eminence height and inclination ($p = 0.003$, $p = 0.006$), and a greater glenoid fossa depth ($p = 0.0036$) compared to females. Coronal morphology was not significantly associated with sex and age. Sagittal condylar morphology showed a trend toward statistical significance in relation to age ($p = 0.055$).

Conclusion: Antero-posterior condylar width was significantly shorter with increasing age. Men showed significantly greater medio-lateral condyle width, articular eminence height and inclination, and greater glenoid fossa depth in relation to women. Dental status classified according to Eichner showed no measurable association with temporomandibular joint morphology in this sample. Only sagittal condylar morphology showed a trend toward statistical significance with respect to age.

Keywords: Tooth loss, Temporomandibular joint, Articular eminence, Condyle morphology, Cone-Beam Computed Tomography

Introduction

The temporomandibular joint (TMJ) is a specific joint of vital importance, as it enables mandibular movements during mastication, swallowing, and speech. Any morphological or functional alteration leads to disruption of normal function. Throughout life, continuous adaptation and remodeling of these structures occur. The process of physiological remodeling represents the TMJ's response to masticatory forces and loading [1, 2]. Furthermore, the process of remodeling of the mandibular condyles and associated osseous changes may be response to degenerative alterations within the temporomandibular joint (TMJ) [3-5].

Cone-Beam Computed Tomography (CBCT) is the method of choice for assessing and diagnosing morphological changes of the TMJ, providing accurate and precise analysis of osseous structures and detailed information on all present pathological processes [6]. Morphological changes of the TMJ associated with excessive loading or tooth loss remain a subject of ongoing research. The articular eminence, as the anterior border of the articular surface of the mandibular fossa influences the kinematics of the joint through its shape and size and determines the inclination of the condylar path. Its morphological change can be associated with dental status [7].

Previous studies have shown that patients with loss of posterior tooth may have changes in terms of the inclination of the articular eminence and the reduction of the depth of the glenoid fossa [8-10]. Changes in the dental status increase the loading on the condyle and articular eminence, resulting in structural changes of the TMJ in terms of functional adaptation or functional disorders [11]. While some studies report a steeper articular eminence and greater depth and height of the mandibular fossa in patients with temporomandibular disorders (TMD), other studies indicate that individuals without TMD present with a steeper articular eminence [12, 13]. Changes in the osseous structures of the temporomandibular joint, anatomical and functional as well as the inclination of the mandibular condyle, may be associated with dislocation of the articular disc [14, 15]. The aim of the study is to investigate the relationship between age, sex and dental status with changes in the osseous structures of the temporomandibular joint.

Subjects and methods

In this retrospective study, the sample consists of CBCT images of patients, who were previously recorded for diagnostics, therapy and treatment planning, archived in the database of the Radiology Department of the Faculty of Dentistry, University of Sarajevo. The Ethical committee of the Faculty of Dentistry University of Sarajevo issued its approval of this research under no: 02-3-4-19-2-2/2023. The study included 110 CBCT images of patients from the Bosnian-Herzegovinian population. According to age, the CBCT images of patients were divided into three groups:

group 20-40 years old, group 40-60 years old and group over 60 years old.

According to dental status, the images of patients were divided according to the Eichner's classification:

- > Class I - antagonistic contact of teeth exists in all four supporting zones,
- > Class II - antagonistic contact of teeth exists in one, two or three supporting zones or only in the area of the frontal teeth
- > Class III - absence of antagonistic occlusal contact in the supporting zones with a few remaining teeth or complete edentulism in one or both jaws.

CBCT images showing fractures or pathological processes on the structures of the temporomandibular joint and mandible, as well as developmental anomalies were excluded from the study. Also, images of patients younger than 20 years were not included due to incomplete growth. The imaging was performed using a Galileos Comfort plus (Sirona Dental Company, Germany). The field of view (FOV) was a spherical volume of 15.4 cm, collimated to 15 × 8.5 cm, with an operating voltage of 98 kV, current of 3-6 mA, exposure time of 14 s, and isotropic voxel size of 0.25/0.125 mm. The recording was performed with the mouth closed. The patient's head was positioned so that the Frankfurt plane was parallel to the floor. CBCT images were placed in the position of multiplanar reconstruction - MPR ensuring that sections were analyzed in accordance with the correctly positioned head of the patient and the area of analysis. CBCT images were analyzed and measured in sagittal, coronal and axial sections. For data analysis

and measurements, Sidexix 4 software for diagnostics and three-dimensional treatment planning was used.

Analysis and measurements, vertical, horizontal linear and angular were performed on CBCT images:

1. Condylar morphology was analyzed in coronal and sagittal sections. The coronal plane was aligned parallel to the long axis of the condyle, and the sagittal plane was oriented perpendicular to the coronal plane. Condyles were classified as convex, round, flat, angular, or irregular in shape in the coronal plane [16, 17]. In the sagittal plane, condyles were classified as round and flat [18].
2. Medio-lateral (ML) width of the right and left condyles was measured in the coronal section from the point of the medial to the point of the lateral pole of the condyle at the widest section of the condyle.
3. Antero-posterior (AP) width of the right and left condyles was measured in the sagittal section from the most anterior to the most posterior point of the widest condylar section. The sagittal section evaluated where the mediolateral width of the condyle was the greatest on the axial section, which represents the reference [19, 20].
4. Height and inclination of the articular eminence were measured in the sagittal section. The axial section where the widest mediolateral diameter of the condyle was used as a reference for the reconstruction of the sagittal section. The height of the articular eminence was measured as the vertical distance between the lines passing through the highest point of the glenoid fossa and the lowest point of the articular eminence. The inclination of the articular eminence was determined as the angle between the plane passing through the highest point of the glenoid fossa and the lowest point of the top of the articular eminence with the Frankfurt horizontal. Measurements were made on the central sagittal section of the condyle [20, 21].
5. Depth of the glenoid fossa was measured as the vertical distance between the highest point of the glenoid fossa and the line passing through the lowest point of the articular eminence and postglenoid process [12].

Statistical methods of data analysis

Descriptive statistics were calculated for all demographic and morphometric variables. To compare the right and left temporomandibular joint (TMJ) measurements paired t-tests were used.

Morphometric differences between age groups were analyzed with a one-way ANOVA. Sex-related differences in TMJ measurements were checked using independent-samples Welch's t-tests, which seemed more appropriate due to some unequal variances. The effect of dental status, classified by the Eichner index (I-III), on TMJ morphology was also examined using one-way ANOVA, and Tukey's post-hoc tests were applied when needed. Associations between categorical variables, including condylar morphology (both coronal and sagittal) and sex, age group, or Eichner class, were evaluated with chi-square tests. Pearson's correlation coefficients were computed to explore linear relationships between selected morphometric variables—specifically AP width with fossa depth, eminence angle with fossa depth, and ML width with the eminence angle. These correlations were checked just to see if they moved together in any meaningful way.

A multiple linear regression model was used to assess the combined influence of sex, age group, Eichner classification, and glenoid fossa depth on the articular eminence angle. Model diagnostics were inspected, though briefly, and explanatory strength was reported using adjusted R^2 . In addition, a multinomial logistic regression was performed to determine whether sex, age group, and Eichner classification predicted the different coronal condylar morphology types, using the round shape as the reference. Odds ratios (ORs) with 95% confidence intervals were presented, but results for the irregular morphology type were interpreted cautiously because it appeared very rarely. A significance level of $p < 0.05$ was considered statistically important for all analyses. All statistical procedures were carried out using R software (version 4.1.2)

Results

In this study, the sample included CBCT images of 110 patients, 220 temporomandibular joints and 1.540 measurements. Of the total, 45 (40.9%) were men and 65 (59.1%) were women. According to age groups, the group of 20-40 years included 22 (20%)

subjects, the group of 40-60 years 66 (60%) and the group over 60 years 22 (20%). According to dental status (Eichner class) group I included 30 (27.3%), group II 45 (40.9%) and group III 35 (31.8%) images.

No statistically significant differences were found between the right and left sides of TMJ for any of the parameters that were analyzed ($p > 0.05$). The distribution of values for each parameter is shown in Figure 1.

One-way ANOVA revealed no statistically significant differences in any temporomandibular joint measurements across Eichner classes I, II, and III (Table 1). Follow-up Tukey post-hoc comparisons confirmed the absence of pairwise differences between any Eichner groups (all adjusted $p > 0.12$) (Table 2). These findings indicate that tooth loss classification according to Eichner did not show measurable association with TMJ morphology in this sample.

The one-way ANOVA showed no statistically significant differences between the different age groups for medio-lateral condylar width, articular eminence height and inclination, or the depth of the glenoid fossa ($p > 0.05$). However, a statistically significant difference was observed for antero-posterior condylar width between the age groups ($F = 4.29$, $p = 0.016$), suggesting that AP condylar dimensions may change with increasing age. The distribution of AP condylar width in relation to age groups is illustrated in Figure 2. Tukey post-hoc analysis revealed that AP condylar width is significantly shorter in age group 60+ compared to 40-60 ($p = 0.014$), while differences between other age groups are not statistically significant.

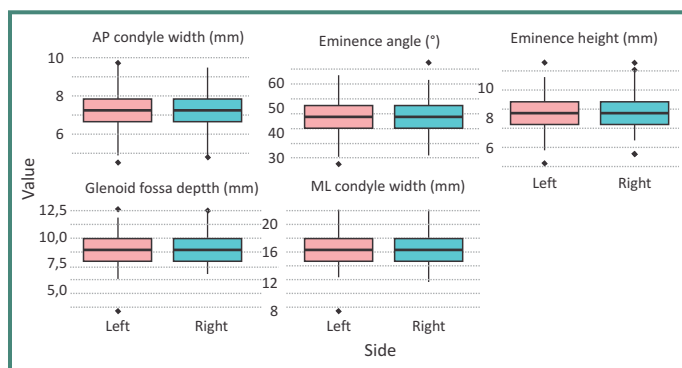
Males showed significantly greater medio-lateral condylar width ($p = 0.0006$), as well as a larger articular eminence height and inclination ($p = 0.003$ and $p = 0.006$, respectively), and also greater glenoid fossa depth ($p = 0.0036$) when compared to females. On the other hand, no statistically significant difference was noted in the antero-posterior condylar width between the two sexes ($p > 0.05$) (Table 3). Boxplot figures of the parameters that showed significant differences between males and females are presented in Figure 3.

The analysis of the distribution of condylar morphology in the coronal plane with different dental status showed in Eichner class I, the most common forms of condyles were round and angular (41.38%, 41.38%) for the right TMJ and left TMJ (40.00%, 33.33%). In class II, the most common shape was

Table 1.
TMJ morphology according to Eichner classification (mean \pm SD, with ANOVA p-values)

Parameter	Eichner I (mean \pm SD)	Eichner II (mean \pm SD)	Eichner III (mean \pm SD)	p
ML width (mm)	16.33 \pm 2.13	16.52 \pm 2.05	16.39 \pm 2.09	0.629
AP width (mm)	7.38 \pm 0.92	7.59 \pm 0.91	7.48 \pm 0.89	0.119
Eminence height (mm)	8.14 \pm 1.12	8.21 \pm 1.11	8.18 \pm 1.12	0.873
Eminence angle ($^{\circ}$)	46.28 \pm 7.01	46.20 \pm 7.18	46.05 \pm 7.18	0.962
Fossa depth (mm)	8.46 \pm 1.22	8.54 \pm 1.22	8.45 \pm 1.21	0.755

Figure 1.
Right and left TMJ (AP condyle width, eminence inclination, eminence height, glenoid fossa depth, ML condyle width)



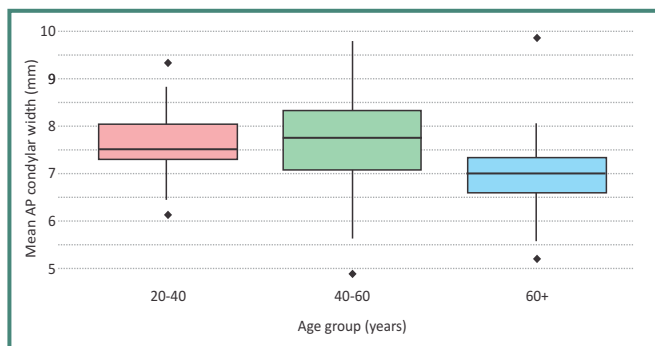
angular on the right condyle (34.09%), followed by round and flat shape equally (27.27%), while on the left side of the TMJ the most common shape was flat condyle (40.00%), followed by round and angular shape equally (26.67%). In Class III, the flat shape of the condyle for the right and left TMJ was dominantly present (44.12% and 41.18%). In the sagittal plane, the dominant shape of the condyles of the right and left TMJ with different dental status was round, class I (83.33%,83.33%), class II (73.33%,71.11%), class III (65.71,62.86%). There was no statistically significant association between coronal and sagittal condylar morphology and Eichner classification ($\chi^2 = 11.68$ $p = 0.166$), ($\chi^2 = 2.59$, $p = 0.274$), ($\chi^2 (2) = 3.37$, $p = 0.186$).

There was no statistically significant association between coronal condylar morphology and sex ($\chi^2 = 5.52$, $p = 0.24$). In a similar way, coronal morphology was also not significantly associated with age group ($\chi^2 = 12.98$, $p = 0.11$). However, sagittal condylar morphology showed a trend toward statistical significance in relation to age ($p = 0.055$). The

Table 2.
Tukey post-hoc comparisons
between Eichner classes for all TMJ parameters

Parameter	Comparison	Mean difference	95% CI	p
ML means	II-I	0.347	-0.826-1.521	0.762
	III-I	0.492	-0.747-1.731	0.614
	III-II	0.145	-0.977-1.267	0.950
AP means	II-I	-0.132	-0.651-0.387	0.818
	III-I	-0.458	-1.006-0.09	0.121
	III-II	-0.325	-0.822-0.171	0.268
Eminence height means	II-I	-0.107	-0.728-0.514	0.912
	III-I	0.009	-0.646-0.665	0.999
	III-II	0.116	-0.478-0.71	0.888
Eminence angle means	II-I	0.464	-3.551-4.479	0.959
	III-I	0.336	-3.902-4.574	0.98
	III-II	-0.127	-3.966-3.712	10.997
Fossa depth means	II-I	-0.219	-0.912-0.474	0.734
	III-I	-0.125	-0.857-0.607	0.913
	III-II	0.094	-0.569-0.757	0.939

Figure 2.
Antero-posterior condylar width according to age group



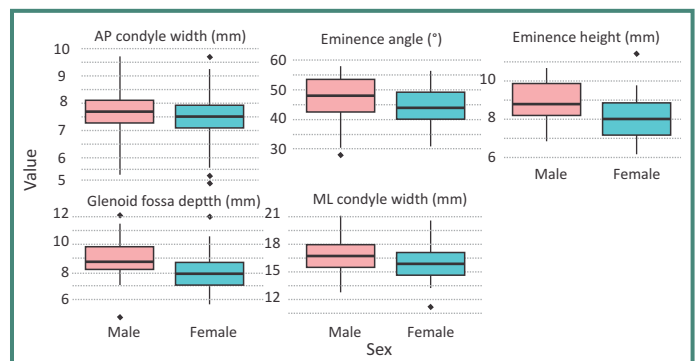
percentage distribution of different condylar shapes according to sex and age groups is shown in Tables 4 and 5.

A moderate positive correlation was found between antero-posterior condylar width and glenoid fossa depth ($r = 0.255, p = 0.007$), as well as between articular eminence inclination and fossa depth ($r = 0.271, p = 0.004$). In addition, a significant positive correlation was also observed between medio-lateral condylar width and articular eminence inclination ($r = 0.254, p = 0.007$). The correlation coefficients and related p-values are presented in Table 6.

Table 3.
Sex differences in temporomandibular joint parameters (ML width, eminence angle, and fossa depth).

Parameter	Male mean \pm SE	Female mean \pm SE	Mean difference	95% CI	p
ML width	17.22 \pm 0.32	115.82 \pm 0.23	1.40	0.61 – 2.18	0.001
AP width	7.60 \pm 0.13	7.38 \pm 0.12	0.22	-0.14 – 0.57	0.231
Eminence height	8.54 \pm 0.164	7.89 \pm 0.128	0.65	0.23 – 1.06	0.003
Eminence angle	48.41 \pm 1.06	44.65 \pm 0.83	3.77	1.08 – 6.45	0.006
Fossa depth	8.89 \pm 0.19	8.19 \pm 0.14	0.70	0.23 – 1.17	0.003

Figure 3.
Sex differences in TMJ



A multiple linear regression model was constructed to evaluate the combined influence of sex, age group, Eichner classification, and glenoid fossa depth on articular eminence inclination. This model excluded medio-lateral and antero-posterior condylar width, in accordance with anatomical considerations indicating that condylar size does not directly determine eminence inclination.

The overall model was statistically significant ($F = 2.32, p = 0.039$), explaining 11.9% of the variance in articulation eminence inclination (adjusted $R^2 = 0.068$). Among the included predictors, only glenoid fossa depth showed a statistically significant effect on articular eminence inclination ($\beta = 1.21, p = 0.033$). A deeper fossa is associated with a steeper articular eminence slope. Sex showed a trend toward significance ($p = 0.054$), with males tending to exhibit slightly steeper eminence inclinations, although this did not reach the conventional 0.05 level. Age group and Eichner classification were not significant predictors (all $p > 0.40$) (Table 7.).

Table 4.
Distribution of coronal condylar morphology according to sex (%)

	Round	Convex	Flat	Angular	Irregular
Male	31.1	2.2	35.6	28.9	2.2
Female	32.7	9.7	22.6	35.5	0.0

Table 5.
Distribution of coronal condylar morphology according to age group (%)

	Round	Convex	Flat	Angular	Irregular
20 - 40	38.1	9.5	14.3	38.1	0.0
40 - 60	35.9	3.1	28.1	32.8	0.0
60+	13.6	13.6	40.9	27.3	4.6

Table 6.
Correlation between selected temporomandibular joint parameters.

Variables	r	P
AP width – Fossa depth	0.255	0.0073
Eminence angle – Fossa depth	0.271	0.0042
ML width – Eminence angle	0.254	0.0074

These findings support the anatomical assumption that vertical skeletal morphology (fossa depth) plays a key role in shaping the articular eminence, whereas condylar width and tooth-loss status do not provide additional explanatory value.

In addition, multinomial logistic regression analysis did not identify any statistically significant predictors for the other coronal shape categories. The irregular shape category was not included in the main interpretation because of unstable estimates caused by its low frequency in the sample. The results for this analysis are presented in Table 8.

Model assumptions were verified through inspection of residual and Q-Q plots. Multicollinearity

Table 7.
Multiple linear regression predicting articular eminence inclination

Predictor	Estimate (β)	Std. Error	T	p-value
Intercept	36.56	5.36	6.82	<0.001
Sex (Female)	-2.76	1.42	-1.95	0.054
Age 40–60 (20-40)	1.38	1.85	0.75	0.455
Age 60+ (20-40)	1.95	2.42	0.81	0.422
Eichner II (I)	0.06	1.75	0.04	0.971
Eichner III (I)	-0.83	1.98	-0.42	0.676
Fossa depth (mm)	1.21	0.56	2.16	0.033

was assessed using variance inflation factors (VIF), which remained below 5 for all predictors. Homoscedasticity and linearity were additionally verified through residual vs fitted plots.

Discussion

In this retrospective study, CBCT images of women were more prevalent than men, aged 40-60 years. According to dental status, the most prevalent subjects were group II classified according to Eichner with preserved support zones, but not in all four zones, followed by subjects with a small number of remaining teeth with loss of support zones of group III, and subjects of control group I with contact of teeth in all four support zones.

No statistically significant differences were found between the right and left sides of TMJ for any of the parameters that were analyzed ($p > 0.05$) (Figure 1.)

These findings indicate that dental status as classified by Eichner showed no measurable association with temporomandibular joint morphology in this sample (Table 1 and Table 2.).

Chen et al. [22] in a study conducted on CBCT images showed that subjects divided according to Kennedy classes with unilateral and bilateral tooth loss and the control group had a larger medio-lateral width of the condyle, a shallower glenoid fossa and a smaller inclination of the articular eminence compared to the results of this study. Also, they proved that there is no

Table 8.
Multinomial logistic regression analysis of factors associated with coronal condylar morphology

Outcome	Predictor	B	SE	OR (95%CI)	p
Convex	(Intercept)	-2.656	1.39	0.07 (0.005-1.07)	0.056
	Female (Male)	1.489	1.185	4.434 (0.435-45.24)	0.209
	40-60 (20-40)	-0.68	1.159	0.507 (0.052-4.918)	0.558
	60+ (20-40)	2.339	1.462	10.375 (0.591-182.03)	0.109
	Eichner II (I)	0.18	1.157	1.198 (0.124-11.562)	0.876
	Eichner III (I)	-1.498	1.631	0.224 (0.009-5.475)	0.359
Flat	(Intercept)	-1.359	0.892	0.257 (0.045-1.474)	0.127
	Female (Male)	-0.293	0.534	0.746 (0.262-2.125)	0.583
	40-60 (20-40)	0.243	0.809	1.276 (0.261-6.233)	0.764
	60+ (20-40)	1.284	1.07	3.609 (0.444-29.366)	0.230
	Eichner II	1.195	0.793	3.303 (0.699-15.614)	0.132
	Eichner III	1.326	0.844	3.766 (0.72-19.699)	0.116
Angular	(Intercept)	-0.153	0.657	0.858 (0.237-3.109)	0.816
	Female (Male)	0.194	0.508	1.214 (0.449-3.284)	0.703
	40-60 (20-40)	0.048	0.628	1.049 (0.306-3.596)	0.939
	60+(20-40)	1.059	0.992	2.882 (0.413-20.131)	0.286
	Eichner II (I)	0.094	0.593	1.099 (0.344-3.512)	0.874
	Eichner III (I)	-0.53	0.717	0.589 (0.144-2.398)	0.460

significant difference in TMJ morphological parameters between the examined groups, which corresponds to the findings of this study, but the depth of the glenoid fossa of the control group was greater than in the group with bilateral and unilateral tooth loss, which is not in accordance with the findings of this study. The inclination of the articular eminence in this study was within the normal value for different dental status. It has been proven that there is a connection between the inclination of the articular eminence and the inclination of the occlusal plane [23]. Articular eminences with inclination values $<30^\circ$ are considered flat, and articular eminence inclination values $>60^\circ$ are considered steep, and may be the cause of TMD [25, 26].

Previous studies have indicated that age and gender can influence the bone morphology of the TMJ [9, 23, 24]. This study showed that antero-posterior condylar width (AP) significantly shorter in the group over 60 years of age. Considering that age group over 60 years old had a dental status without preserved support zones, although a direct association was not proven in

this study due to the small sample, it can be assumed that in addition to age, dental status may also have an influence on the AP parameter (Figure 2.).

Males had a greater medio-lateral (ML) condyle width, higher and steeper articular eminence and deeper glenoid fossa in relation to women but there was no difference in AP width (Table 3. and Figure 3.). Previous studies have shown that men had higher values of height and inclination of the articular eminence compared to women [17, 29]. Other studies have shown that men have higher morphometric values of the condyle and glenoid fossa, but there was no difference in the inclination of the articular eminence between the sexes [30].

A study that included CBCT analysis of 1820 TMJs have shown that the morphology of the condyle in the coronal plane was flat in persons with partial and total edentulism, and convex in persons with a full set of teeth. The flat shape of the condyle was common in men, the round shape in women. The authors found a significant difference between condylar morphology

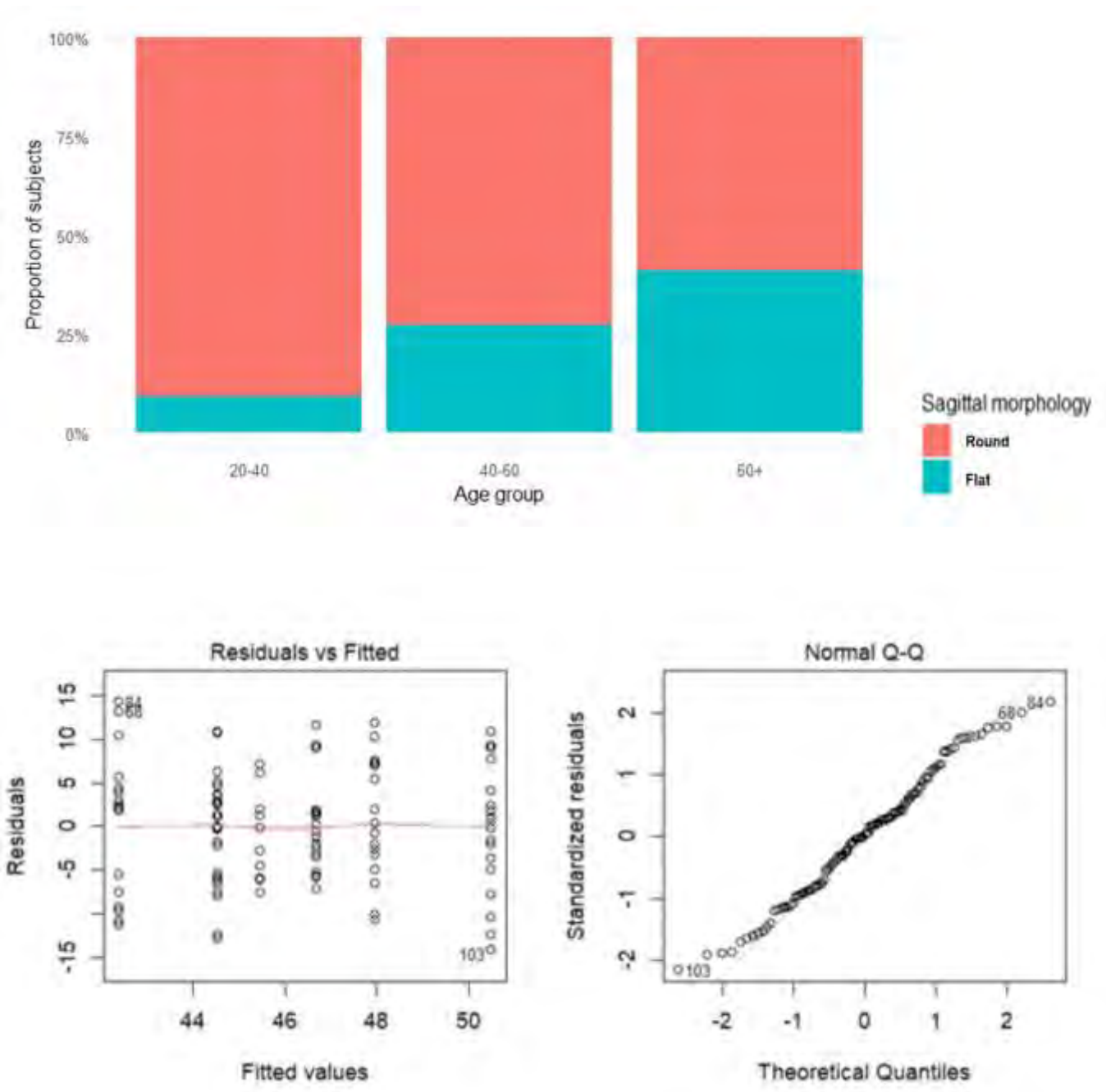


Figure 4. Sagittal condylar morphology by age group

and age. The angular shape was most common between 30-59 years of age compared to people between 18-29 and people over 60 [27]. In this study, the round and angular shape of the condyle were most often represented in Eichner class I, in class II angular on the right TMJ and flat on the left TMJ, and in Eichner class III the flat shape of the condyle was most often present, which corresponds to the findings of the Yalcin and Ararat. In the sagittal plane, the dominantly round shape of the condyle was present in different dental statuses. There was no association between condylar morphology in the coronal and sagittal planes and different dental status according to Eichner. The flat condylar shape was most common in men, and the angular condylar shape in women, but there was no significant association between coronal condylar morphology and gender and age. The round shape was most common in the 20-40 and 40-60 age groups, and the flat shape was most common in those over 60 years of age. However, sagittal condylar morphology showed a trend towards statistical significance with age (Table 4 and 5.).

Correlation between AP width of condyle and depth of glenoid fossa, then inclination of articular eminence and depth of glenoid fossa and ML width of condyle and inclination of articular eminence was proven (Table 6). A multiple linear regression model showed that only glenoid fossa depth had a significant effect on articular eminence inclination. Thus, a deeper glenoid fossa was associated with a steeper articular eminence (Table 7.) Also, a correlation between the inclination of the articular eminence and the depth of the glenoid fossa was demonstrated in a previous study by analyzing MRI of the TMJ [27].

Multinomial logistic regression determined that gender, age and Eichner classification did not predict different types of coronal condylar morphology (Table 8.) Contrary to these findings, Arayapisit et al. [5] proved the relationship of all the mentioned clinical factors with flat condylar morphology.

The limitation of this study is a small sample. Larger sample sizes are needed to investigate these associations.

Conclusion

Antero-posterior condylar width was significantly shorter with increasing age. Men showed significantly greater medio-lateral condyle width, articular eminence height and inclination, and greater glenoid

fossa depth in relation to women. Dental status classified according to Eichner showed no measurable association with temporomandibular joint morphology in this sample. Only sagittal condylar morphology showed a trend toward statistical significance with respect to age.

There is no conflict of interest.

References

1. Cohen A, Sela MC, Verkauf TA, Alterman M, Talisman S, Casap N. The influence of mandibular condyle morphology on TMJ anterior dislocations. *Oral Surg Oral Med Oral Pathol Oral Radiol.* 2021 Oct;132(4):393-397.
2. Abbate V, Audino G, Dell'Aversana Orabona G, Friscia M, Bonavolontà P, Lo Faro C, Committeri U, Cuéllar CN, Iaconetta G, Califano L. Condylar Reshape in Orthognathic Surgery: Morphovolumetric and Densitometric Analysis Based on 3D Imaging and Digital Workflow. *J Maxillofac Oral Surg.* 2022 Jun;21(2):501-509.
3. Aboalnaga AA, Amer NM, Alhammadi MS, Fayed MMS. Positional and dimensional TMJ characteristics in different temporomandibular disorders: A cross-sectional comparative study. *Cranio.* 2022 Jan 21:1-9.
4. Alfaleh W. Relationship between horizontal condylar angle and radiographically detectable morphological changes of the condyle in asymptomatic and symptomatic patients with TMD. *Saudi Dent J.* 2021 Dec;33(8):1154-1159.
5. Arayapisit T, Ngamsom S, Duangthip P, Wongdit S, Wattanachaisiri S, Joonthongvirat Y, Mitrirattanukul S. Understanding the mandibular condyle morphology on panoramic images: A conebeam computed tomography comparison study. *Cranio.* 2020 Dec 9:1-8.
6. Whyte A, Boeddinghaus R, Bartley A, Vijayaendra R. _Imaging of the temporomandibular joint. *Clin Radiol.* 2021 Jan;76(1):76.e21-76.e35.

7. Erzurumlu ZU, Celenk P. A radiological evaluation of the effects of edentulousness on the temporomandibular joint. *J Oral Rehabil.* 2020 Mar;47(3):319-324.
8. Zhang Y, Huang H, Hao P, Zhang G, Wang Y, Chen F, Yang C, Liu Z. The impact of posterior tooth loss on the biomechanics of the temporomandibular joints. *Comput Methods Biomech Biomed Engin.* 2025 Feb 17:1-10.
9. Vîrlan MJR, Păun DL, Bordea EN, Pellegrini A, Spînu AD, Ivaşcu RV, Nimigean V, Nimigean VR. Factors influencing the articular eminence of the temporomandibular joint (Review). *Exp Ther Med.* 2021 Oct;22(4):1084.
10. Chen M, Lin Y, Wei R, Li Y, Yang R, Wang Z, Li P, Sui L. A cone beam computed tomography study on the osseous morphology of temporomandibular joint with free loss of posterior teeth. *Arch Oral Biol.* 2025 Sep; 177:106337.
11. Chen Y, Wang J, Li Y, Li L, Luo N, Wu Y, Dai H, Zhou J. Age-related variations in position and morphology of the temporomandibular joint in individuals with anterior openbite and crossbite: a multi-cross-sectional comparative study. *BMC Oral Health.* 2022 May 23;22(1):200.
12. Paknahad M, Shahidi S, Akhlaghian M, Abolvardi M. Is Mandibular Fossa Morphology and Articular Eminence Inclination Associated with Temporomandibular Dysfunction? *J Dent Shiraz Univ Med Sci.* 2016 June; 17(2): 134-141.
13. Caglayam F, Sümbüllü MA, Akgüül HM. Associations between the articular eminence inclination and condylar bone changes, condylar movements, and condyle and fossa shapes. *Oral Radiol.* 2014; 30: 84-91.
14. Monaco EG, De Stefano AA, Hernandez-Andara A, Galluccio G. Correlation between condylar size on CT and position of the articular disc on MRI of the temporomandibular joint. *Cranio.* 2019;00(00).
15. de Farias JFG, Melo SLS, Bento PM, Oliveira LSAF, Campos PSF, de Melo DP. Correlation between temporomandibular joint morphology and disc displacement by MRI. *Dentomaxillofac. Radiol.* 2015;44(7):1-7.
16. Ejima K, Schulze D, Stippig A, Matsumoto K, Rottke D, Honda K. Relationship between the thickness of the roof of glenoid fossa, condyle morphology and remaining teeth in asymptomatic European patients based on cone beam CT data sets. *Dentomaxillofac. Radiol.* 2013;42(3):90929410.
17. İlgüy D, İlgüy M, Fişekçioğlu E, Dölekoğlu S, Ersan N. Articular eminence inclination, height, and condyle morphology on cone beam computed tomography. *Scientific World Journal.* 2014 Feb 13;2014.
18. Ma RH, Feng JL, Bornstein MM, Li G. Relationship between development of the condylar cortex and the changes in condyle morphology: a cone-beam computed tomography (CBCT) observational study. *Quant Imaging Med Surg.* 2023 Apr 1;13(4):2388-2396
19. Alam MK, Ganji KK, Munisekhar MS, Alanazi NS, Alsharif HN, Iqbal A, Patil S, Jamayet NB, Sghaireen M. A 3D cone beam computed tomography (CBCT) investigation of mandibular condyle morphometry: Gender determination, disparities, asymmetry assessment and relationship with mandibular size. *Saudi Dent J.* 2021 Nov;33(7):687-692.
20. Kim HO, Lee W, Kook YA, Kim Y. Comparison of the condyle-fossa relationship between skeletal class III malocclusion patients with and without asymmetry: a retrospective three-dimensional cone-beam computed tomography study. *Korean J Orthod.* 2013 Oct;43(5):209-17.
21. Shahidi S, Vojdani M, Paknahad M. Correlation between articular eminence steepness measured with cone-beam computed tomography and clinical dysfunction index in patients with temporomandibular joint dysfunction. *Oral Surg Oral Med Oral Pathol Oral Radiol.* 2013 Jul;116(1):91-7.
22. Chen M, Lin Y, Wei R, Li Y, Yang R, Wang Z, Li P, Sui L. A cone beam computed tomography study on the osseous morphology of

- temporomandibular joint with free loss of posterior teeth. *Arch Oral Biol.* 2025 Sep; 177:106337.
23. Camacho-Álvarez FE, Martínez-Contreras SP, Rodríguez-Chávez JA, Martínez-Suárez G, González-Aragón Pineda ÁE, Ramos-Montiel RR, Ramírez-Martínez CM, Sánchez-García S, Cruz-Hervert LP, Jiménez-Corona ME. Characteristics of the Occlusal Plane Associated with Unilateral and Bilateral Articular Eminence Inclination: A Cross-Sectional CBCT Study. *Dent J (Basel).* 2024 Sep 29;12(10):316.
 24. Wu Z, Lin Y, Lin Y. Impact of age on degenerative joint disease of the temporomandibular joint: A systematic review and meta-analysis. *Medicine (Baltimore).* 2025 Apr 25;104(17):e41915.
 25. Ozkan A, Altug HA, Sencimen M, et al. Evaluation of articular eminence morphology and inclination in TMJ internal derangement patients with MRI. *Int J Morphol* 2012; 30:740–744.
 26. Katsavrias EG. Changes in articular eminence inclination during the craniofacial growth period. *Angle Orthod* 2002; 72:258–264.
 27. Yalcin ED, Ararat E. Cone-Beam Computed Tomography Study of Mandibular Condylar Morphology. *J Craniofac Surg.* 2019 Nov-Dec;30(8):2621-2624.
 28. Saeed SS, Al-Falki DA. Detection of the Correlation between Glenoid Fossa and Mandibular Condyle in Closed and Opened Mouth Position by MRI. *Int. J. Med. All Body Health Res.* 2024; 05(04):25-29.
 29. Razi T, Razi S. Association between the morphology and thickness of bony components of the temporomandibular joint and gender, age and remaining teeth on cone-beam CT images. *Dent Med Probl.* 2018 Jul-Sep;55(3):299-304.
 30. Melo DP, Silva DB, Campos PF, Dantas JA. The morphometric measurements of the temporomandibular joint. *Front Oral Maxillofac Med.* 2021;3:(14) 1-11.

GINGIVAL DEPIGMENTATION WITH Er:YAG LASER: WHAT IS NEW?

Verica Pavlić^{*1,2}, Koji Mizutani³, Risako Mikami⁴,
Tijana Adamović², Smiljka Cicmil⁵, Saša Dabić⁶,
Mirjana Gojkov Vukelić⁷, Akira Aoki⁸

¹ Department of Periodontology and Oral medicine, The Republic of Srpska Institute of Dentistry, Banja Luka, Bosnia and Herzegovina

² Department of Periodontology and Oral medicine, Medical faculty University of Banja Luka, Banja Luka, Bosnia and Herzegovina

³ Department of General Dentistry, Graduate School of Medical and Dental Sciences, Tokyo, Japan.

⁴ Department of Advanced Biomaterials, Graduate School of Medical and Dental Sciences, Institute of Science Tokyo, Japan.

⁵ Department of Periodontology and Oral medicine, Medical faculty Foca University of East Sarajevo, Bosnia and Herzegovina

⁶ "Implantodont dr Sasa Dabic" dental clinic, Banja Luka, Bosnia and Herzegovina

⁷ Department of Oral medicine and Periodontology, University of Sarajevo-Faculty of Dentistry

⁸ Department of Periodontology, Graduate School of Medical and Dental Sciences, Institute of Science Tokyo, Tokyo, Japan

*Corresponding author

Verica Pavlic, professor
Department of Periodontology
and Oral Medicine
The RS Institute of Dentistry
Banja Luka
Medical Faculty University of
Banja Luka
Bosnia and Herzegovina
E-mail address:
verica.pavlic@med.unibl.org

DOI 10.69559/issn.2233-1794.2025.14.2.3

ABSTRACT

Gingival melanin or metal tattoo pigmentation is occasionally observed and produces aesthetic problems to the patients while smiling. Among dental lasers, the Er:YAG laser used water spray minimizes the thermal changes of the irradiated soft tissue and safe and effective tool for depigmentation procedure. Microscope-assisted Er:YAG laser surgery can precisely detect and remove melanin pigmentation and metal debris embedded in the connective tissue. When using a laser device in a microsurgery, it is necessary to pay attention to safety. It is essential to wear protective goggles to protect from reflections and scattered light during treatment.

Key words: Laser depigmentation; Er:YAG laser; Melanin hyperpigmentation; Metal tattoo

Introduction

The healthy color of the gingiva plays a vital role in the attractiveness of a smile, particularly in individuals with a high smile line [1]. Under normal physiological conditions, the gingiva appears coral or salmon pink, though this shade may vary depending on several factors, including the degree of vascularization, epithelial thickness, gingival biotype, and the concentration of melanin pigment [1, 2].

Gingival hyperpigmentation may be either physiological or pathological in origin (Figure 1). Physiological pigmentation most commonly appears as visible oral melanin pigmentation, which is most frequently observed on the gingiva among all intraoral tissues. Melanin, the pigment responsible for this coloration, is synthesized and stored within melanosomes produced by melanocytes [1]. These melanocytes are located in the basal cell layer of the epithelium and contribute to the darkened appearance of the gingiva, referred to as melanin hyperpigmentation/MH [1, 2].

To the contrary, iatrogenic pigmentation, such as metal or amalgam tattoos, can occur unintentionally during dental procedures. This type of pigmentation presents as blue-grey discoloration of the gingiva, resulting from the accidental deposition of metallic particles or micro fragments from dental prosthetic materials into the gingival tissue adjacent to treated teeth [1, 2].

Although melanin hyperpigmentation and amalgam tattoos are not associated with medical complications, patient demand for their removal, particularly in cases involving pigmentation of the anterior labial gingiva, continues to rise due to aesthetic concerns. A wide range of treatment modalities have been introduced for MH removal, including bur abrasion, electrosurgery, chemical and cryosurgery, laser therapy, gingivectomy, flap surgery, gingival grafting, and various combinations of these methods [1-4]. Among these, laser surgery has proven to be an effective, safe, comfortable, and reliable technique for gingival depigmentation [5-7].

In recent years, the Er:YAG laser, among other laser types, has gained significant attention for its exceptional efficiency in soft tissue ablation while minimizing thermal damage to surrounding and underlying tissues [5-7]. In vivo studies have shown that the thermally affected layer in gingival connective tissue following Er:YAG laser incision is limited to only 5-20 μm [7, 8]. As a result, Er:YAG laser treatment is widely recognized as a minimally invasive and highly precise approach to gingival depigmentation. Moreover, combining the Er:YAG laser with a surgical microscope enhances the precision, safety, and completeness of the procedure [2, 9]. These technical advantages of Er:YAG laser microsurgery contribute to improved wound healing, reduced postoperative discomfort, and enable delicate or complex interventions that are difficult to perform using conventional methods [2].

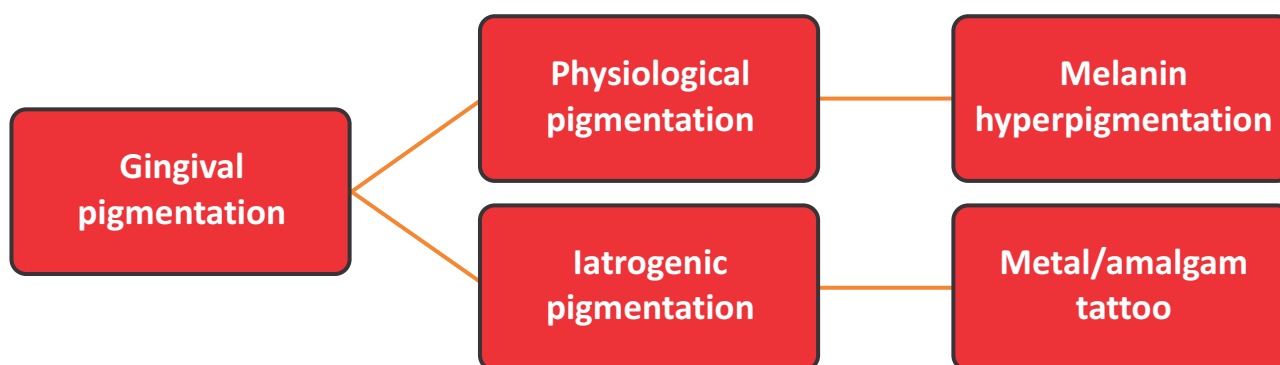


Figure 1. Gingival pigmentation

A critical consideration in ensuring the safety of clinical laser applications is the prevention of accidental eye exposure. The eye possesses the lowest maximum permissible exposure threshold of all body tissues [10]. Because the Er:YAG laser wavelength is absorbed by the surface layers of the eyeball, accidental irradiation can result in thermal injury to the cornea [10]. Therefore, before beginning treatment, it is essential that the patient, operator, and assistant wear protective eyewear (goggles) specifically designed for the laser's wavelength to safeguard against reflected or scattered laser light [10].

Removal of melanin pigmentation

Melanin depigmentation using the Er:YAG laser can be performed under local, topical, or no anesthesia, depending on the severity and extent of pigmentation as well as the patient's comfort and preference [1, 2]. The laser irradiation is typically set at an energy level of 50-80 mJ per pulse on the control panel (corresponding to an actual energy output of 25-40 mJ per pulse), with an energy density of 8.8-14.2 J/cm² per pulse when using a 600 µm diameter contact tip. The procedure is carried out at a repetition rate of 10-30 Hz under continuous water spray, with the laser applied in an oblique contact mode at an angle of approximately 20-30 degrees to the gingival surface [1, 2].

The laser beam is moved using the "brush" or "sweeping motion" technique-entailing slow, continuous movements with overlapping laser spots to ensure uniform ablation. After the initial complete ablation of the pigmented area, any residual pigmentation is meticulously removed under 20-30× magnification by fine-tuning the laser focus, targeting small dotted or occasionally linear pigment deposits, particularly those located at the base of epithelial rete pegs. Immediately after the procedure, spontaneous hemostasis is achieved in a few minutes and no suture is required [2-4].

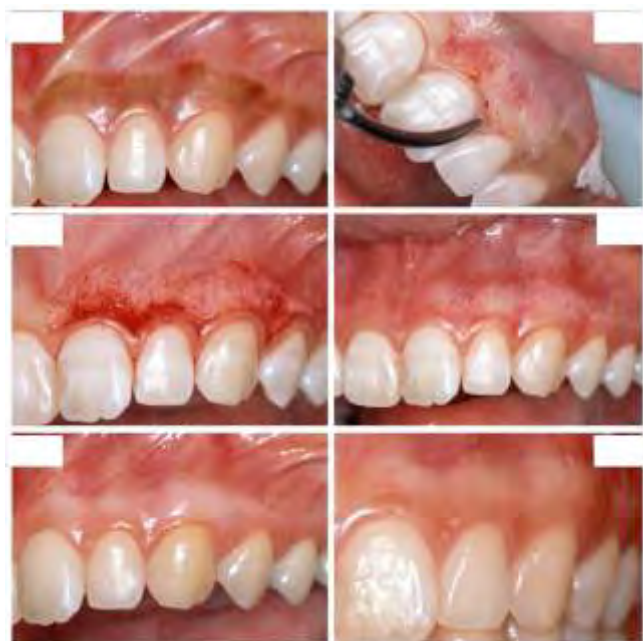

Figure 2. Case presentation of Er:YAG laser melanin depigmentation. a) Female, 19 years old. Generalized severe melanin hyperpigmentation in the upper arch, on the first visit, b) During irradiation with local anesthesia, 40-47 mJ/pulse at tip end (62-72 mJ/pulse on the control panel) and 30 Hz under water spray in oblique contact mode using an 80 degree curved contact tip, c) immediately after Er:YAG laser melanin depigmentation, no severe thermal injuries such as carbonization and severe coagulation of the gingival tissue, d) 9 days postoperatively, ablated gingiva showed fast epithelialization with a healthy appearance, e) 42 days postoperatively, f) 6 months following irradiation complete healing was observed without recurrences or gingival recessions or deformities. [Picture from Ishii S, Aoki A, Kawashima Y, Watanabe H, Ishikawa I. Application of an Er:YAG laser to remove gingival melanin hyperpigmentation-Treatment procedure and clinical evaluation. J Jpn Soc Laser Dent. 2002;13:89-96. © copyright (2002) J Jpn Soc Laser Dent] [9]

Removal of metal tattoo pigmentation

Most treatment sites are located in the maxillary anterior region, followed by the

mandibular anterior and premolar areas. Typically, a small amount of local anesthesia (0.2-0.45 ml) is sufficient for this procedure. In cases of mild pigmentation, treatment can sometimes be performed under topical anesthesia or even without anesthesia, depending on the extent and severity of pigmentation [1-4].

Laser irradiation is generally applied at an energy setting of 50-80 mJ per pulse on the panel (corresponding to an actual energy output of 25-40 mJ) per pulse and an energy density of 8.8-14.2 J/cm² per pulse when using a 600 µm contact tip). The procedure is performed at a repetition rate of 10-30 Hz under continuous water spray, with the laser applied in a vertical or oblique contact mode at an angle between 30° and 90° to the tissue surface. Curved, round-ended contact tips (400 or 600 µm in diameter) are recommended. Each treatment session typically lasts about 20-40 minutes [1-4].

Minimal gingival ablation is performed in the darkly pigmented (black or gray) areas to expose the underlying metal debris deposited within the connective tissue. A magnified visual field (approximately 10–30×) enables precise and safe tissue ablation while minimizing injury to surrounding areas. The metal fragments and adjacent discolored connective tissue are carefully removed, while the papillary edges, free gingival margins, and periodontal tissue attachment to the root surface are preserved to prevent tissue detachment and potential gingival recession caused by excessive or inadvertent irradiation [2-4].

The limited hemostatic effect of the Er:YAG laser is advantageous for wound healing, as postoperative bleeding promotes blood clot formation and subsequent granulation within the ablation site. This process supports favorable healing and helps prevent gingival defects. Care must be taken to minimize tissue injury in order to maintain the integrity of the blood clot and avoid postoperative complications [2, 3].

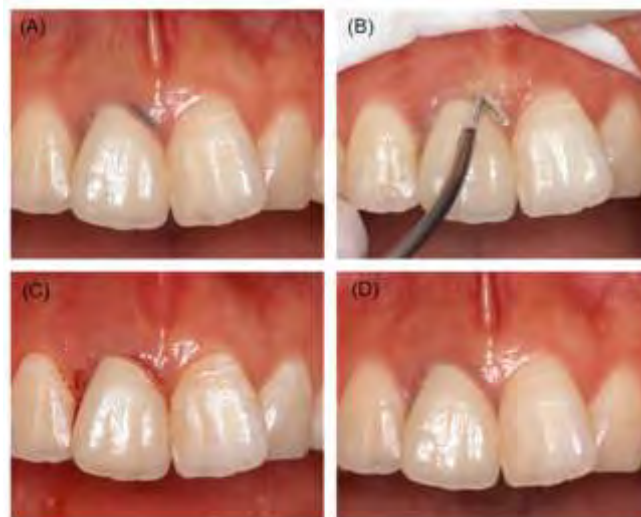

Figure 3. Patient was a 27-years old female who had (A) linear moderate metal tattoo pigmentation in the mesial and distal marginal gingiva of the maxillary right central incisor. (B) The metal tattoo area was vaporized using an Er:YAG laser and topical anesthesia only. (C) The postoperative view immediately after minimally-invasive metal tattoo removal. Slight bleeding followed by spontaneous hemostasis was observed. (D) One week after treatment, epithelialization was complete and the gingival discoloration had disappeared. No gingival recession was observed. [Picture from Mikami R, Mizutani K, Nagai S, Pavlic V, Iwata T, Aoki A. A novel minimally-invasive approach for metal tattoo removal with Er:YAG laser. *J Esthet Restor Dent.* 2021;33(4):550-559, with permission] [3]

Recently, a minimally invasive approach known as Er:YAG Laser Micro-Keyhole Surgery (EL-MIKS) has been introduced [2, 4]. In this microsurgical technique, small “keyholes” are created to enable targeted removal of pigmentation. Initially, a keyhole with a diameter of 1-2 mm is prepared using the Er:YAG laser with a 400 or 600 µm contact tip. The laser is applied vertically at 60-80 mJ per pulse on the panel (actual energy output approximately 30-40 mJ) per pulse; energy density 23.9-31.2 J/cm² per pulse for a 400 µm tip) and a frequency of 20-30 Hz. Deposited metal fragments and surrounding discolored connective tissue are eliminated [4].

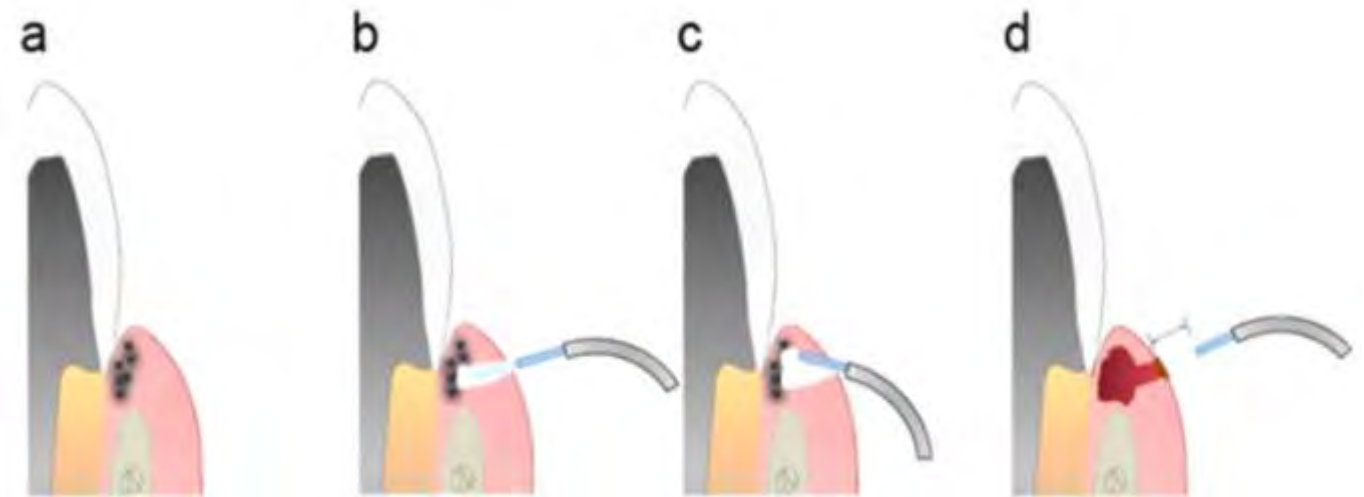
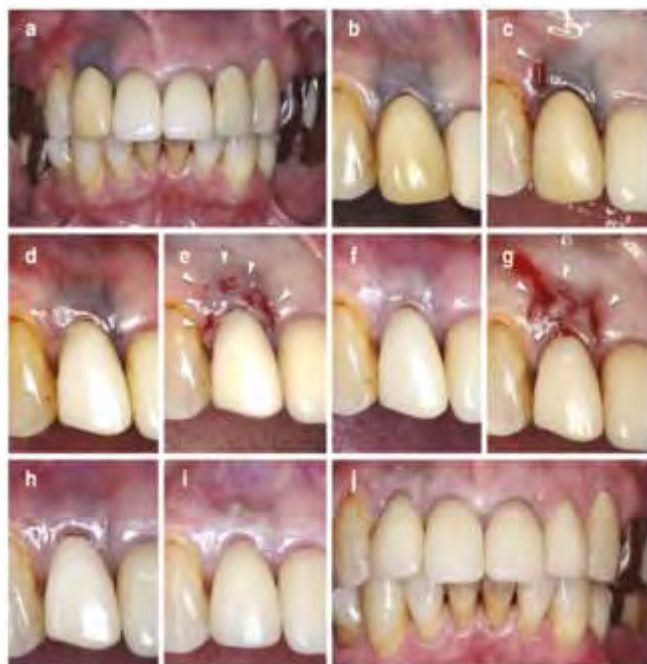

Figure 4. Step-by-step procedure of Er:YAG laser micro-keyhole laser surgery (EL-MIKS) for removing metal tattoos in the gingiva adjacent to prosthetic teeth (a). Making a small keyhole with a diameter of 1-2 mm to access the pigmented gingiva to ablate metal fragments and the surrounding discolored connective tissue using an Er:YAG laser (b). Shifting the laser direction to ablate the metal and surrounding tissue. Eliminate micro-metal fragments as much as possible through the keyhole so as not to expand the size of the keyhole. Carefully preserve the overlying gingiva of the discolored tissue intact (c). After the tissue evaporation, the ablated space fills with blood. Defocus irradiation (10 Hz, 60 mJ) without a water spray to the micro-keyhole entrance with more than 5 mm distance between the laser tip and gingiva (double-headed arrow) was performed. The coagulation of the blood surface is encouraged by a laser-derived heat reaction. The blood clot is stabilized within the evaporated space (d). If the pigmentation is widespread, the area to be treated must be divided into several parts that are treated one by one. Micro keyholes are prepared to access the center of each part. [Picture from Mizutani K, Mikami R, Tsukui A, Nagai S, Pavlic V, Komada W, Iwata T, Aoki A. Novel flapless esthetic procedure for the elimination of extended gingival metal tattoos adjacent to prosthetic teeth: Er:YAG laser micro-keyhole surgery. *J Prosthodont Res.* 2022;66(2):346-352, licensed under CC BY-NC 4.0, Japan Prosthodontic Society]. [4]

Next, the lateral wall of the pigmented area is treated at an inclined angle to evaporate the pigmented tissue while preserving the overlying epithelium and preventing enlargement of the keyhole entrance. Accessible metal particles and pigmented tissue within the undercut area are carefully ablated [2-4]. For better visualization, a laser tip or periodontal probe may be used to gently retract the marginal gingiva. The coaxial water spray accompanying the Er:YAG laser helps flush out residual metal fragments and tissue debris from the keyhole. The irradiation angle is repeatedly adjusted in multiple directions within each micro-keyhole to remove as much pigmented tissue as possible within the accessible range. After blood fills the tissue defect, the surface at the keyhole entrance is coagulated using defocused laser irradiation (60-80 mJ per pulse; 400 or 600 μm contact tip; 10-20 Hz) without water spray [4].

Figure 5. A representative case of Er:YAG laser micro-keyhole laser surgery (EL-MIKS) on a widespread metal tattoo (a). The patient was a 61-year-old female with a prominent metal tattoo in the gingiva of #12 (b). Because the pigmentation was widespread, the area to be treated was divided into several parts (dotted line). Micro-keyholes were prepared to access the center of each part. In this case, the distal part with the most severe discoloration was treated first (c). All procedures were performed with a microscope and Er:YAG



laser under local anesthesia. Immediately after the first session, only the apical part of the distal pigmentation was treated through one micro-keyhole (arrowhead) (d). One month after the first surgery, the area treated in the first session was completely epithelized (e), and treatment of the distal pigmentation of the coronal part and mesial, buccal middle areas were partly performed through five microkeyholes (arrowheads) in the second session (f). One month after the second session (g), the deposited pigments in the deep mesial region were removed through four micro-keyholes (arrowheads) in the second session (h). At one month after the third session, the pigmentation slightly remained (i). Three months after the third session, the gingival pigmentation had completely disappeared. Since the metal fragments causing the pigmentation had been removed, the slightly remained discoloration spontaneously disappeared with the gingival turnover. The recession of the marginal gingiva was generally prevented. Note the crown was replaced (j). Two years after the procedures, the improved gingival color has been maintained, and the patient was esthetically satisfied with the treatment (k). Figure reproduced from Mizutani K, Mikami R, Tsukui A, Nagai S, Pavlic V, Komada W, Iwata T, Aoki A. Novel flapless esthetic procedure for the elimination of extended gingival metal

tattoos adjacent to prosthetic teeth: Er:YAG laser micro-keyhole surgery. *J Prosthodont Res.* 2022;66(2):346-352, licensed under CC BY-NC 4.0, Japan Prosthodontic Society. [4]

Because of the minimally invasive nature of the procedure, postoperative medication is usually unnecessary for small treatment areas [2, 4]. However, analgesics or antibiotics may be prescribed depending on the treatment extent and patient preference. Patients are advised to avoid tooth brushing in the treated area and to use antiseptic mouth rinses for one week following the procedure. Re-epithelialization typically occurs within 4-7 days, depending on the size of the treated region, while complete tissue maturation is generally achieved within approximately two weeks [1-4].

Conclusion

The Er:YAG laser allows for precise and efficient treatment of gingival tissue, enabling controlled ablation through the use of fine contact tips. Its minimal thermal effect offers significant advantages, including improved visibility of the treated surface, enhanced wound healing, and effective pain management during soft tissue procedures. Moreover, when combined with microscopic assistance, Er:YAG laser irradiation permits careful and accurate removal of gingival pigmentation with minimal tissue trauma. This approach simplifies the procedure, reduces postoperative discomfort, and promotes smooth and rapid healing. Notably, the novel minimally invasive technique for metal tattoo removal utilizing the Er:YAG laser under microscopic monitoring has proven to be simpler, more efficient, and far less invasive than conventional periodontal surgical methods.

Literature

1. Pavlic V, Brkic Z, Marin S, Cicmil S, Gojkov-Vukelic M, Aoki A. Gingival melanin depigmentation by Er:YAG laser: A literature review. *J Cosmet Laser Ther.* 2018;20(2):85-90.
2. Aoki A, Mizutani K, Mikami R. Microscope-assisted laser ablation of gingival pigmentation. In: Chan H, Velasquez-Plata D, eds. *Microsurgery in Periodontal and Implant Dentistry-Concepts and Applications*, 1st ed: Springer, 2022.
3. Mikami R, Mizutani K, Nagai S, Pavlic V, Iwata T, Aoki A. A novel minimally-invasive approach for metal tattoo removal with Er:YAG laser. *J Esthet Restor Dent.* 2021;33(4):550-9.
4. Mizutani K, Mikami R, Tsukui A, Nagai S, Pavlic V, Komada W, et al. Novel flapless esthetic procedure for the elimination of extended gingival metal tattoos adjacent to prosthetic teeth: Er:YAG laser micro-keyhole surgery. *J Prosthodont Res.* 2022 Apr 27;66(2):346-352.
5. Mizutani K, Aoki A, Coluzzi D, Yukna R, Wang CY, Pavlic V, et al. Lasers in minimally invasive periodontal and peri-implant therapy. *Periodontol 2000* 2016;71(1):185-212.
6. Mizutani K, Aoki A, Takasaki AA, Kinoshita A, Hayashi C, Oda S, et al. Periodontal tissue healing following flap surgery using an Er:YAG laser in dogs. *Lasers Surg Med* 2006;38(4):314-24.
7. Aoki A, Mizutani K, Schwarz F, Sculean A, Yukna RA, Takasaki AA, et al. Periodontal and peri-implant wound healing following laser therapy. *Periodontol 2000.* 2015;68(1):217-69.
8. Kawamura R, Mizutani K, Lin T, Kakizaki S, Mimata A, Watanabe K, et al. Ex vivo evaluation of gingival ablation with various laser systems and electroscalpel. *Photobiomodul Photomed Laser Surg* 2020; 38:364-73.
9. Ishii S, Aoki A, Kawashima Y, Watanabe H, Ishikawa I. Application of an Er:YAG laser to remove gingival melanin hyperpigmentation-Treatment procedure and clinical evaluation. *J Jpn Soc Laser Dent.* 2002; 13:89-96.
10. Pavlic V, Vujic Aleksic V. Laser safety in dentistry. *Scripta Medica* 2016;47(1):63-8.

PERIODONTAL SPLINTING – AN ADJUNCT TO NON-SURGICAL PERIODONTAL THERAPY FOR TEETH WITH INCREASED MOBILITY

Anisa Zoronjić^{1*}, Sanja Hadžić¹, Arma Muharemović¹, Mia Hodžić², Zerina Kučinar³, Indira Mujić Jahić¹

¹ Department of Oral Medicine and Periodontology, Faculty of Dentistry, University of Sarajevo

² Clinic of Oral Medicine and Periodontology, Dental Clinical Center, University of Sarajevo

³ Department of Pediatric Dentistry, Faculty of Dentistry, University of Sarajevo

*Corresponding author

Ass. dr. Anisa Zoronjić
Department of Oral Medicine
and Periodontology,
Faculty of Dentistry,
University of Sarajevo
Email: zoronjicanisa@gmail.com
Phone: +387 62 664 587

DOI 10.69559/issn.2233-1794.2025.14.2.4

ABSTRACT

Introduction: Periodontitis is a chronic inflammatory disease leading to the loss of the supporting apparatus of the tooth, and tooth mobility is a common complication of advanced stages of the disease. Splinting is a therapeutic measure stabilizing mobile teeth and improves function in the patient.

Aim: To present the clinical procedure and therapeutic outcome of splinting of mobile lower incisors in a patient with stage 3, class B periodontitis.

Methods: A case of a 40-year-old patient with pronounced gingival recessions, moderate plaque index, subgingival calculus and mobility of the lower frontal teeth is presented. After initial non-surgical therapy and subgingival curettage, splinting of the lower incisors was performed using Ribbond fibers. The procedure included etching, adhesive preparation, adaptation of the fibers to the contour of the tooth and finishing with composite material, with occlusion check and polishing. Clinical effects were monitored through multiple visits.

Discussion: Splinting with fiber-reinforced composite materials is an effective and aesthetically acceptable method of tooth stabilization in patients with periodontitis. In this case, stabilization of mobile teeth and reduction of subjective symptoms of hypersensitivity after treatment were achieved. The literature confirms that adequately planned and timely splinting can contribute to the improvement of periodontal parameters, bone remodeling and increased oral health quality of life. An individualized approach and estimation of optimal intervention timing are key to achieving stable long-term outcomes.

Keywords: periodontitis, tooth mobility, periodontal splint, Ribbond fibers, non-surgical therapy, tooth stabilization.

Introduction

Periodontitis is a chronic, multifactorial inflammatory disease associated with the accumulation of dental plaque (dental biofilm) and is characterized by progressive damage to the periodontal ligament and alveolar bone [1].

Periodontitis is a significant health problem, with a prevalence of 62% in adults with preserved teeth, while severe forms of the disease affect about 23.6% of the population [2]. Studies show that 30–50% of patients with periodontitis have loose teeth, which significantly affects the quality of life associated with oral health [3].

According to the new classification, periodontitis is classified into 4 stages (stage I-IV) according to the severity and complexity of treatment of the disease and is determined by several factors: loss of clinical attachment, amount and percentage of bone loss, depth of probing, presence and size of bone defects, and involvement of root furcations, tooth mobility and tooth loss due to periodontitis. There are three classes (Class A – low risk, Class B – moderate risk, Class C – high risk of disease progression) and it also includes aspects related to the progression of periodontitis, general health and other risk factors such as smoking and the level of metabolic control of diabetes [2].

According to the World Classification of Periodontal Diseases 2017, teeth with progressive mobility may require the placement of a splint in their therapy [4].

Early splint placement in advanced periodontitis can improve periodontal healing and prolong tooth retention. There are different types of splint materials, categorized according to their purpose, such as wire, fiber-reinforced tape (Ribbond splint), retainers, and welded tapes (metal strips) [5].

Case report

The patient, aged 40, reports to the Clinic for Oral Medicine and Periodontology of the School of Dental Medicine in Sarajevo due to pain in the area of teeth 37 and due to pronounced hypersensitivity of the teeth in the frontal part of the mandible. Anamnestic data indicate a negative medical history but a positive genetic predisposition to periodontitis. The patient denies bad habits.

The general condition of the patient was good, extraoral examination did not reveal any abnormalities.

After determining and measuring periodontal indices and pockets, the patient was determined to maintain a moderate level of hygiene, with a plaque index of 20%. Present subgingival stones in all regions, gingival edema, and generalized bleeding on probing.

All teeth are present except teeth 36, 38, 46, 48 (missing). Gingival recessions are present on all teeth of the lower jaw and their value is from 2 to 5 mm, in the upper jaw recessions are present only on the lateral teeth and from 2 to 3 mm. When probing, the depth of the periodontal pocket (measured by the Williams graduated probe) in the upper jaw is highest in the area of the frontal teeth (from 13 to 23) and is 4-5 mm, on the remaining lateral teeth of the upper jaw the depth is from 2 to 4 mm. By probing the teeth of the lower jaw, the

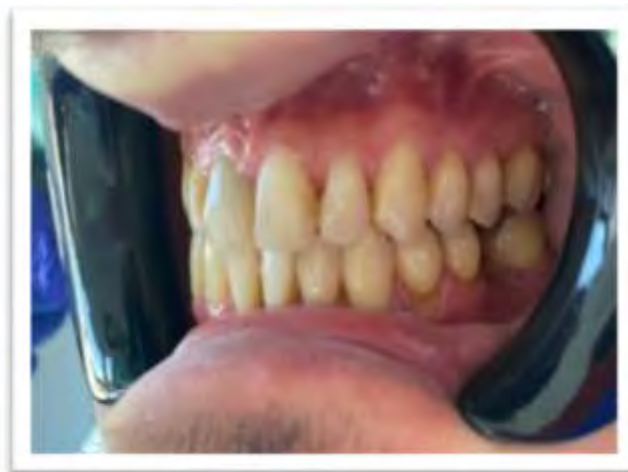

Figure 1. (a)

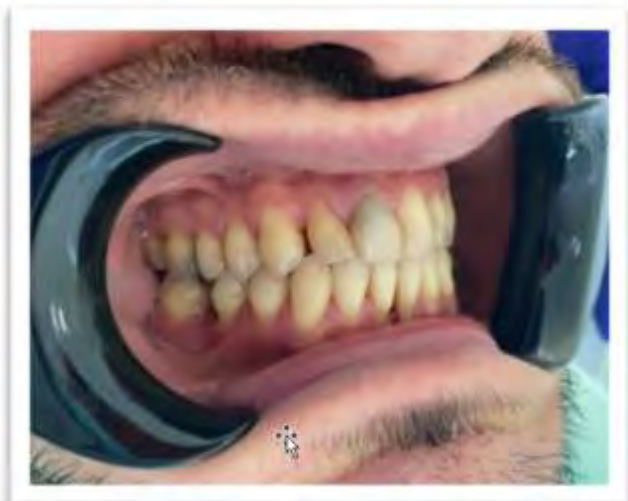

Figure 1. (b)

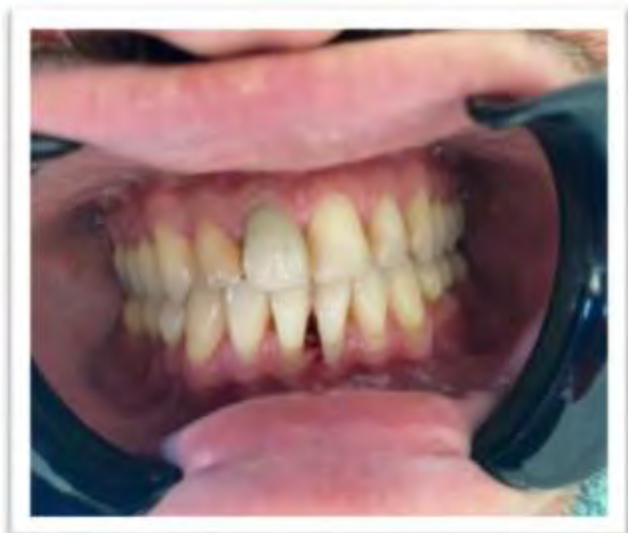

Figure 1. (c)

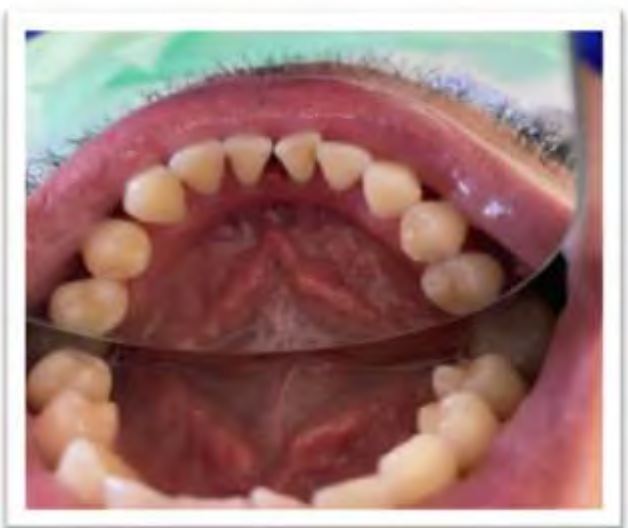

Figure 1. (d)

Figure 1. (a-d)
Clinical intraoral photographs of the patient

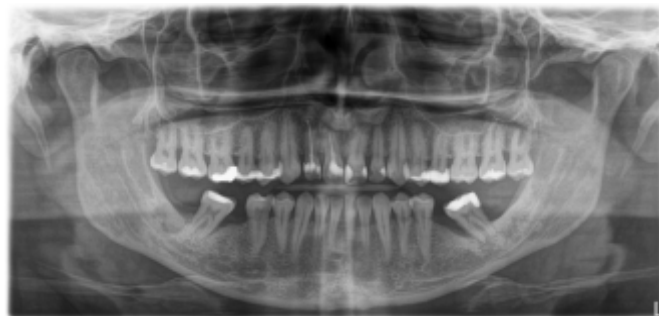

Figure 2.
Orthopantomogram of the patient

depth is from 2 to 3 mm. Clinical examination observed the mobility of individual teeth (42, 31, 32), the mobility of 2 degrees is in question. Intraoral photos of the patient are shown in Figure 1, and the OPG image is shown in Figure 2.

On the OPG scan, we can see the loss of alveolar bone, with dominant horizontal resorption in the upper and lower jaw. On the lateral teeth of the mandible in the area of the premolars and molars, the greatest bone resorption is observed with the presence of infrabone pockets (vertical bone resorption). By clinical examination and analysis of the OPG image, the diagnosis in the patient according to the classification from 1999 is chronic periodontitis, however, according to the new classification of the World Health Organization from 2017, the diagnosis of periodontitis stage 3, B class is made. The therapy plan for this patient includes non-surgical periodontal therapy, subgingival curettage of the tooth 13,12,11,21,22,23. In order to preserve function and prevent further deterioration, periodontal splint is planned to be placed in the therapy as an additional therapeutic measure to non-surgical therapy.

During the first visit, non-surgical periodontal therapy was performed, with the aim of removing supragingival and subgingival stones. After seven days, a check-up was carried out. During the examination, the patient reported tooth hypersensitivity 32, 31 and 41, which was correlated with clinically recorded exposed root surfaces. At the next check-up, a week later, a complete withdrawal of subjective symptoms of hypersensitivity was confirmed.

In the continuation of the therapy, subgingival curettage was performed in the lower jaw, on teeth 33, 32, 31, 41, 42 and 43. During the fourth visit, a splint was placed on the lower frontal teeth with the application of Ribbond fibers.

Sterilized aluminum foil was used as a measure, as it was tightly fitted to the teeth. The measured foil was then used as a template for the Ribbond

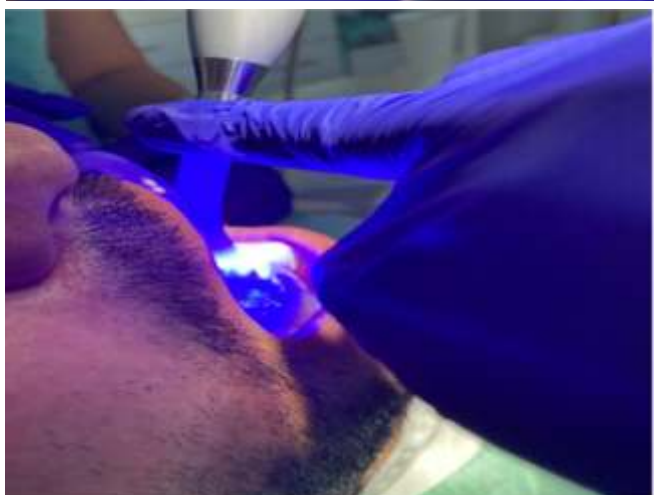
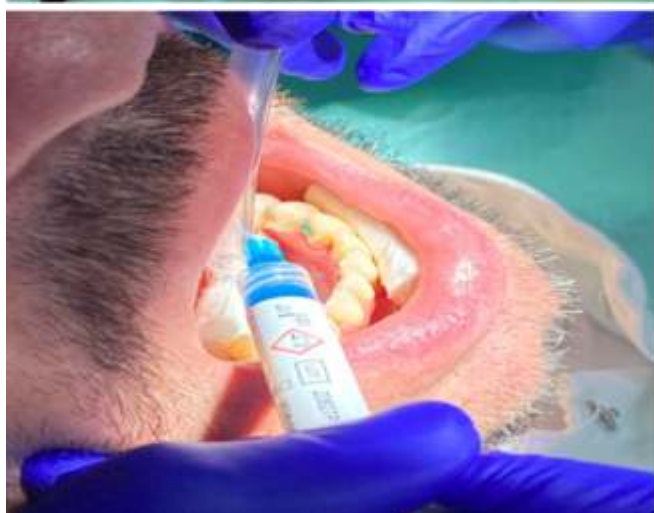
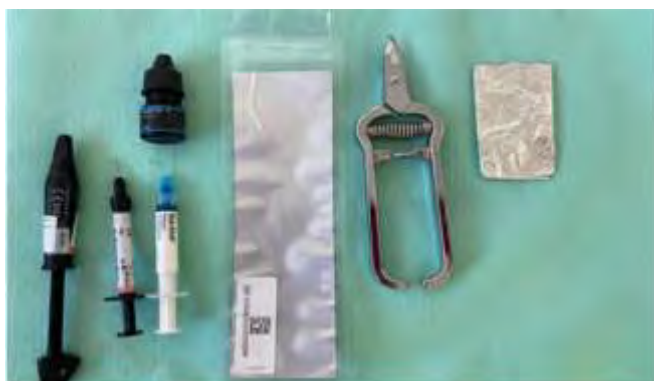Figure 3.
Preparation for Ribbond splint placement and necessary instruments

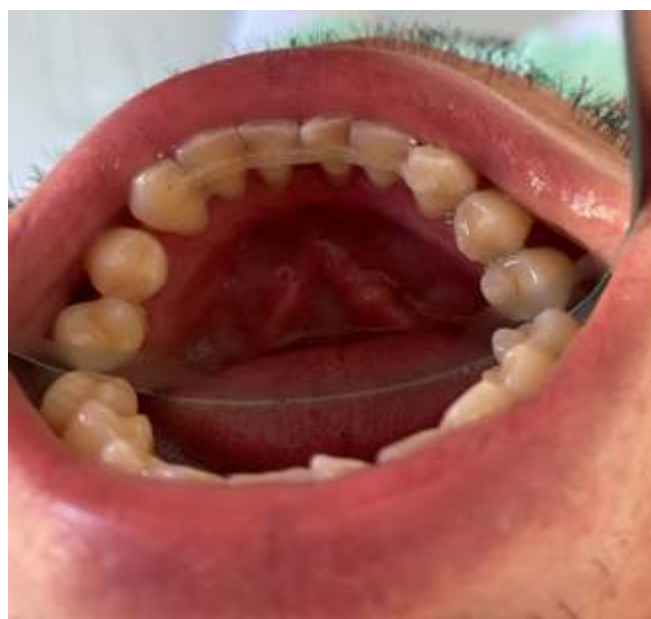

Figure 4.
Clinical picture after Ribbond splint placement

ribbon. The teeth were coated with 37% phosphoric acid for 15 seconds, after which the acid was washed away. After drying, the surfaces acquired a white matte appearance. Then, a bond was applied to the rinsed and dried surfaces using a microbrush, air-dried and fixed with LED light for 15 seconds, twice (Figure 3).

The Ribbond tape is carefully held with a special instrument, a thin layer of composite for fixing the Ribbond is applied to the prepared surfaces of the teeth. Holding the Ribbond with metal pliers, it is carefully adapted to the lingual and approximal surfaces of the teeth by following their contour and anatomy.

The liquid composite was then carefully applied to cover all of the Ribbond fibers and was thoroughly polymerized for 30 seconds per tooth. Finally, occlusion checking, finishing and polishing followed (Figure 4).

Discussion

Tooth mobility is an important characteristic of periodontal disease, which begins as periodontitis progresses and affects the periodontal ligament,

leading to bone loss, tooth mobility, and eventual tooth loss if left untreated. That is why tooth mobility is one of the criteria for assessing the condition of periodontium. It has become an important diagnostic parameter for clinicians to determine the integrity, functional state, and disease of periodontium [3].

The placement of the splint helps to redistribute forces to the stronger teeth, thereby reducing the occlusal load on the periodontium.

It is also noted that splinting stimulates the bone remodeling process to prevent bone tissue loss. It is necessary to take into account the indications and contraindications for the splint placement procedure itself, which will eventually lead to positive clinical and functional outcomes for a longer period of time [5]. In our case report, we made the diagnosis based on clinical parameters and analysis of the family farm image.

Fiber-reinforced composite splint quickly gained popularity as the material of choice for periodontal splint. They allow precise adjustment to the contours of the teeth, making them resistant to damage. They can be glued, repaired, are more aesthetically pleasing and easier and faster to adjust than conventional wire splinters. Periodontal splint is widely accepted and is used as an adjunct treatment for tooth mobility [6]. According to a retrospective study by Sarah K. Sonnenschein et al., the splint durability rate in the lower front teeth was 67% after 10 years. Kumbuloglu et al. also found an extremely high rate of splint persistence in their retrospective follow-up of 19 periodontitis patients who had lower canine-to-canine splinting therapy. After 4.5 years, the splint durability rate was 94.8% [7, 8]. These indicate significant differences in the stability of splints in the mandibular anterior region compared to the posterior region, which was confirmed by both Graetz et al. [6]. Posterior teeth are exposed to greater chewing forces compared to the front teeth, and it can be assumed that this leads to different loads on the splints in individual regions, which is why fractures in the posterior region occur more often [7].

A new classification of periodontal diseases states that teeth with progressive mobility may require splint placement in therapy to improve patient comfort [9]. The latest evidence also points to a trend of additional improvement in oral health quality of life in patients with periodontitis through splinting of mobile incisors as an integral part of periodontal therapy. Retrospective studies, furthermore, show high endurance rates and periodontal stability of spliced teeth during long-term, supportive periodontal therapy [6, 10].

According to the results of research by Sonnenschein et al. (2022), the splinting time of mobile mandibular incisors can significantly affect periodontal outcomes. Early splinting, before the implementation of complete non-surgical periodontal therapy, showed a tendency to better results in terms of periodontal parameters, which can be explained by the reduction of microtrauma and easier maintenance of oral hygiene [9].

On the other hand, splinting after non-surgical periodontal therapy makes it possible to monitor the remission of tooth mobility, which can avoid unnecessary stabilization of the tooth, which emphasizes the importance of an individualized approach in therapy planning. These findings suggest that the decision on the optimal moment of splinting should be based on clinical parameters and the specific condition of the patient, thereby maximizing the therapeutic effect and minimizing unnecessary intervention [9].

The work of Zhang et al. (2021) presents an innovative digital technique for splinting mobile teeth in the lower frontal region in patients with periodontitis. The use of an intraoral scanner and CAD/CAM technology enables the production of a precise and durable splint, which minimizes the risk of improper adhesion and potential mechanical complications. The use of titanium alloy ensures long-term mechanical stability, while the design of the splint does not interfere with oral hygiene or worsen periodontal condition. This digital approach further emphasizes the importance of individualization of therapy and can extend the life of mobile teeth, improve chewing

function, aesthetics and patient comfort, and delay or avoid invasive interventions [[10]. However, the clinical applicability of a digital approach depends on the availability of technology and professional competencies in practices, and long-term research is needed to assess the durability and impact on periodontal health [11].

Of course, there are also some drawbacks to splinting. Access to oral hygiene and plaque control are difficult after splint placement. It has been observed that due to the accumulation of plaque on the margins of the splint, gum irritation and periodontal problems can occur in patients with damaged periodontium. Long-term splinting can cause caries on interproximal surfaces, gingival caries due to the accumulation of food debris, as well as crown loss or fractures of the front teeth. Splinting can also cause phonetic problems [5].

Conclusion

Periodontal splint is an important addition to non-surgical periodontal therapy in teeth with increased mobility, as it stabilizes teeth, reduces

microtrauma and improves functional and aesthetic outcomes. The combination of strategic planning of splinting time and the application of digitally precise methods represents a promising direction in modern periodontal therapy, with the aim of preserving mobile teeth and increasing the quality of life of patients.

Acknowledgments

We would like to express our sincere gratitude to the patient, who participated in this case report, for his time and cooperation. We also thank to our colleagues and mentors at the Department of Oral Medicine and Periodontology for their guidance, expertise, and valuable feedback throughout the case. Their contributions were essential for the successful completion of this work.

Declaration of Interest:

The authors declare that there are no conflicts of interest regarding the publication of this paper.

References

1. Kwon T, Lamster IB, Levin L. Current Concepts in the Management of Periodontitis. *Int Dent J*. 2021 Dec;71(6):462-476.
2. Malmqvist S, Strandberg P, Victorin I, Boberg E, Johannsen A. The new system for classification of periodontal and peri-implant disease: A questionnaire study of implementation by Swedish dental hygienists. *Int J Dent Hyg*. 2025 Aug;23(3):625-631.
3. Gupta S, Mukhiya S, Kafle A, Ghimire S, Acharya UK. Tooth Mobility among Patients visiting a Tertiary Care Centre: A Descriptive Cross-sectional Study. *JNMA J Nepal Med Assoc*. 2023 Jan 1;61(257):30-35.
4. Zhang Y, Kang N, Xue F, Duan J, Chen F, Cai Y, Luan Q. Survival of nonsurgically splinted mandibular anterior teeth during supportive maintenance care in periodontitis patients. *J Dent Sci*. 2023 Jan;18(1):229-236.
5. Priyabrat Sahu. Teeth Mobility Cause and Management of Mobile Teeth in Dental Clinic. *Indian J Forensic Med Toxicol*. 2020;14(4): 8211-8215.
6. Graetz C, Ostermann F, Woeste S, Sälzer S, Dörfer CE, Schwendicke F. Long-term survival and maintenance efforts of splinted teeth in periodontitis patients. *J Dent*, 2019; 80: 49-54.
7. Sonnenschein SK, Kilian S, Ruetters M, Ciardo A, Kim TS. Changes in periodontal parameters of splinted versus non-splinted posterior teeth during ten years of supportive periodontal therapy - A retrospective evaluation. *Clin Oral Investig*. 2024 Apr 29;28(5):283.
8. Kumbuloglu O, Saracoglu A, Ozcan M (2011) Pilot study of unidirectional E-glass fibre-reinforced composite resin splints: up to 4.5-year clinical follow-up. *J Dent* 39:871-877
9. Sonnenschein SK, Ciardo A, Kilian S, Ziegler P, Ruetters M, Spindler M, Kim TS. The impact of splinting timepoint of mobile mandibular incisors on the outcome of periodontal treatment-preliminary observations from a randomized clinical trial. *Clin Oral Investig*. 2022 Jan; 26(1): 921-930. doi: 10.1007/s00784-021-04075-4. Epub 2021 Jul 26. Erratum in: *Clin Oral Investig*. 2022 Aug;26(8):5515
10. Sonnenschein SK et al (2021) The impact of splinting mobile mandibular incisors on Oral Health-Related Quality of Life – preliminary observations from a randomized clinical trial. *J Clin Periodontol* 48(6):816-825
11. Zhang C, Liu Q, Yang J, Hou J. A digital technique for splinting periodontally compromised mobile teeth in the mandibular anterior region. *J Prosthet Dent*. 2021 Apr;125(4):560-563.

FROM HOPELESS TO REGENERATED: SUCCESSFUL PRESERVATION OF A TOOTH WITH MASSIVE PERIAPICAL LESION IN AN ADOLESCENT

Begović Adna^{1*}, Hasić-Branković Lajla¹, Korać Samra¹,
Ljaljević Faruk², Pašić Mirna¹, Halilović Mehinović Madžida¹

¹ Department of Dental Pathology with Endodontics, Faculty of Dentistry with Dental Clinical Center, University of Sarajevo, Bosnia and Herzegovina

² Department of Oral surgery, Faculty of Dentistry with Dental Clinical Center, University of Sarajevo, Bosnia and Herzegovina

*Corresponding author

Adna Begović, DMD
Department of Dental Pathology
with Endodontics
Faculty of Dentistry with
Dental Clinical Center
University of Sarajevo
Bolnička 4a, 71 000 Sarajevo
Bosnia and Herzegovina
Phone: +387 62 485 310
e-mail: adnabegovic@sf.unsa.ba

DOI 10.69559/issn.2233-1794.2025.14.2.5

Abstract word count: 238

Manuscript word count: 2277

ABSTRACT

Background: Periapical lesions in adolescents present a particular therapeutic challenge due to age-related anatomical and physiological characteristics, including greater susceptibility to dental trauma, higher caries risk, wide apical foramen and thin dentinal walls. At the same time, high regenerative capacity offers the possibility of successful treatment even in cases with an initially very poor prognosis.

Case Presentation: This report presents a 14-year-old patient with a massive periapical lesion and an iatrogenic root canal perforation of tooth 12. Cone-beam computed tomography (CBCT) imaging revealed an extensive osseous defect with complete perforation of the palatal cortical plate and marked destruction of the vestibular bone. Management included sealing the perforation with MTA under an operative microscope and endodontic treatment followed by apicoectomy with bone graft augmentation and placement of a PRF membrane. After the surgery, the tooth was stabilized with a wire-composite splint until physiologic stability was restored. A four-month follow-up CBCT scan showed complete repair of the osseous defect, homogeneous graft integration, re-established cortical continuity, and preservation of a normal periodontal ligament space. Clinically, stable function and satisfactory esthetics were achieved.

Conclusion: This case demonstrates that even large periapical lesions complicated by iatrogenic perforation with an initially unfavorable prognosis can be successfully managed through a combination of advanced endodontic therapy and surgical intervention. A multidisciplinary approach, precise diagnostics, and the use of bioactive materials enabled preservation of the natural tooth and complete recovery of periapical structures in an adolescent patient.

Keywords: massive periapical lesion, adolescent, endodontic surgery, regenerative dentistry, bioactive materials

Introduction

Periapical lesions in children and adolescents hold particular clinical significance due to anatomical and physiological characteristics, such as increased susceptibility to trauma, high caries risk associated with poor oral hygiene and, in cases of incomplete root development, a wide apical foramen and thin dentinal walls, that can complicate treatment and allow a progressive infection spread [1, 2, 3]. However, young patients' tissues demonstrate enhanced vascularization and high regenerative potential, promoting faster, more effective tissue repair [4]. This report aims to present the therapeutic protocol and clinical outcome of treating a tooth with an extensive periapical lesion in an adolescent patient, emphasizing the importance of comprehensive clinical assessment providing tooth preservation despite a poor initial prognosis.

Case report

A 14-year-old patient was referred to the Clinic of Dental Pathology and Endodontics due to persistent symptoms in tooth 12 following unsuccessful long-term repeated endodontic treatment. Medical history revealed a sports-related trauma occurred prior to two years .

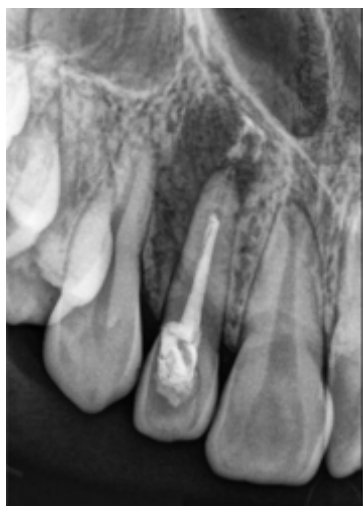

Figure 1. Initial periapical radiograph

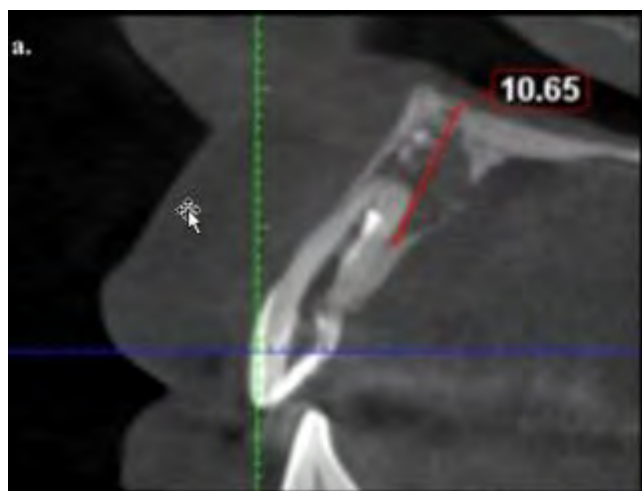


Figure 2a.

Dimensions of the lesion on sagittal CBCT view

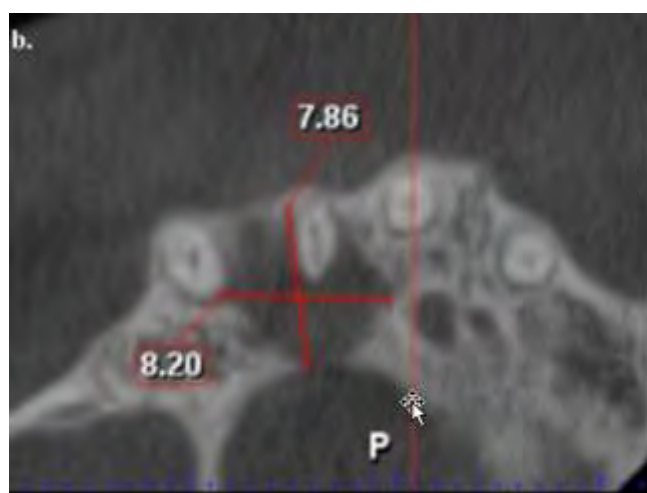


Figure 2b.

Dimensions of the lesion on axial CBCT view

Clinical examination under an operative microscope and radiographic analysis showed a previously initiated endodontic treatment and a *fausse route* in the cervical third of the root. Previous radiographs revealed an extensive periapical radiolucency with residual intracanal medication (**Figure 1**). The patient was referred for a segmental cone-beam computed tomography (CBCT) scan, which confirmed a significant bone defect measuring 10.65 mm in the apico-coronal, 7.86 mm in the bucco-palatal, and 8.20 mm in the mesic-distal dimensions (**Figure 2**). The palatal cortical bone was completely perforated, with a significant destruction of the vestibular bone

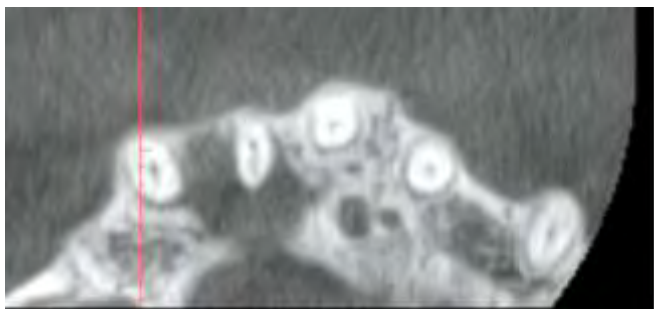

Figure 3.

Axial CBCT view shows complete perforation of palatal cortex

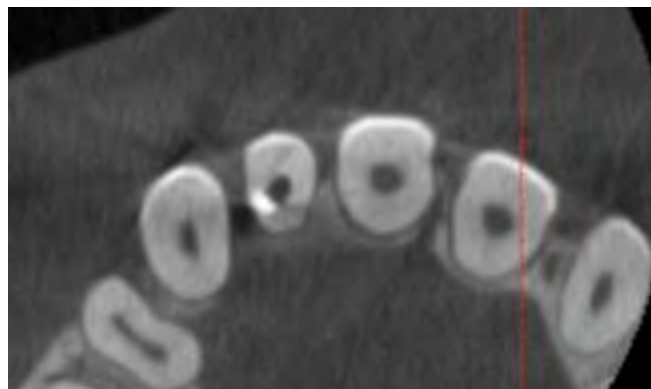


Figure 5. Communication between the perforation and the lesion on an axial CBCT view

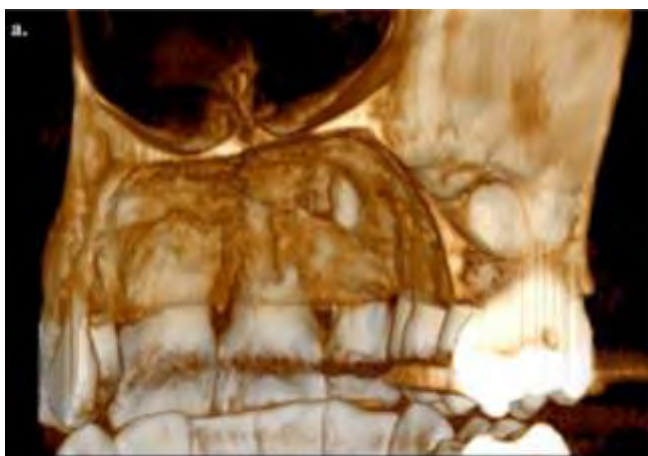


Figure 4a.

Absence of the palatal bone on 3D reconstruction view

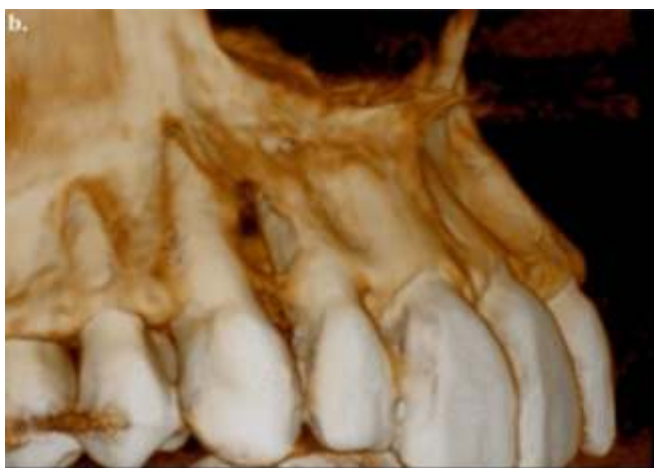

Figure 4b.

Vestibular bone defect on 3D reconstruction view

(**Figure 3, 4**). Communication between the periapical lesion and the root canal through the perforation was observed (**Figure 5**), creating a pathway for Para radicular spread of infection, which affected approximately three-quarters of the root length.

Case management

During the first visit, the iatrogenic root canal perforation was sealed using a mineral trioxide aggregate (MTA)-based material under the operative microscope. The canal was then instrumented to a size of 40/.04 with copious irrigation using 2.5% sodium hypochlorite. At the end of the procedure, calcium hydroxide was placed in the canal, along with a gutta-percha cone used as a physical barrier for potential MTA extrusion from the perforation site into the canal, which could compromise future access to the root canal. After 10 days, the canal was obturated with gutta-percha and a bio ceramic sealer using the ultrasonic condensation technique, and the access cavity was restored with a glass-ionomer filling.

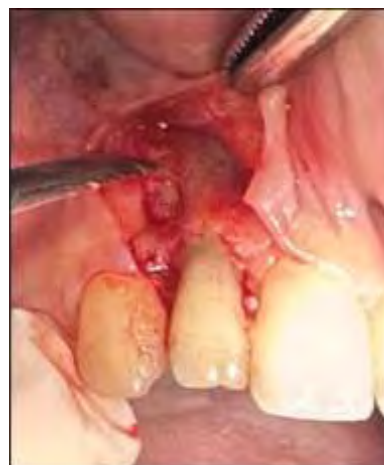

Figure 6. Vestibular bone fenestration observed after flap elevation

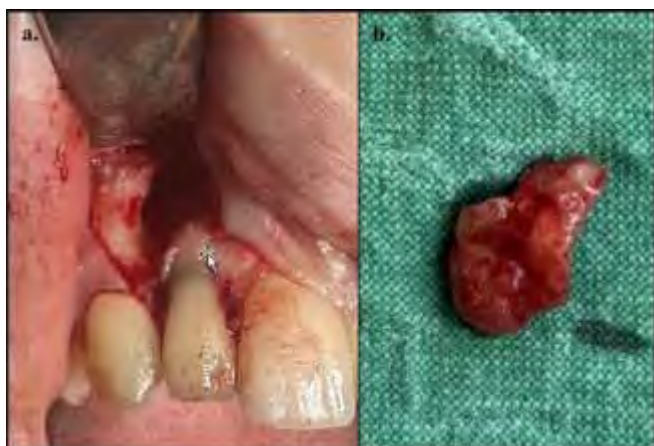

Figure 7a. The bone defect after the apicoectomy and cystectomy
Figure 7b. Pathological material after enucleation

The treatment plan mandated sequential performance of endodontic and surgical procedures. Therefore, the patient was admitted to the Clinic of Oral Surgery the following day, immediately after the canal filling had set. Four tubes of blood were collected, from which were obtained two platelet-rich fibrin (PRF) membranes and one PRF clot. Sticky bone graft was prepared using synthetic bone material. A mucoperiosteal flap with a distal releasing incision was raised to gain access to the surgical field, revealing the bone defect and the lesion with Para radicular extension (**Figure 6**). Apicoectomy of tooth 12 was performed along with cystectomy (**Figure 7**). The bone defect was filled with sticky

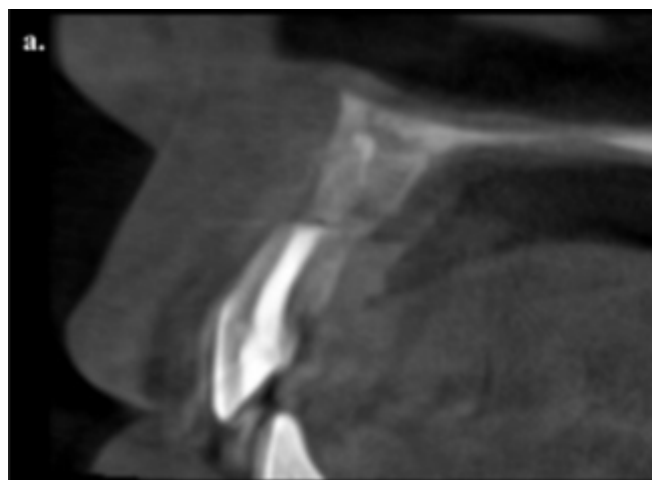


Figure 9a.
 Control CBCT scan in sagittal view

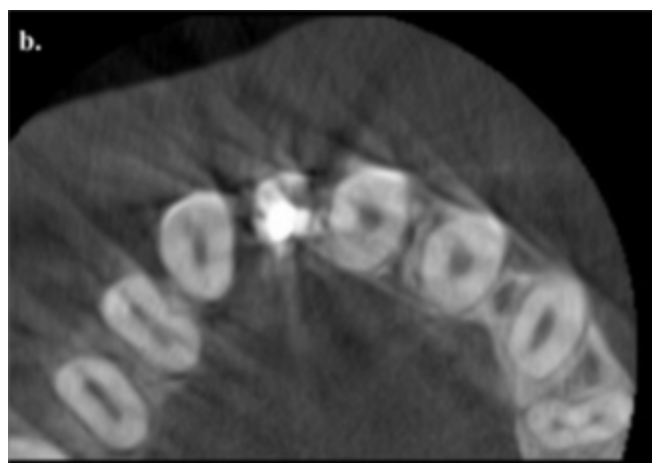


Figure 9b.
 Control CBCT scan in axial view

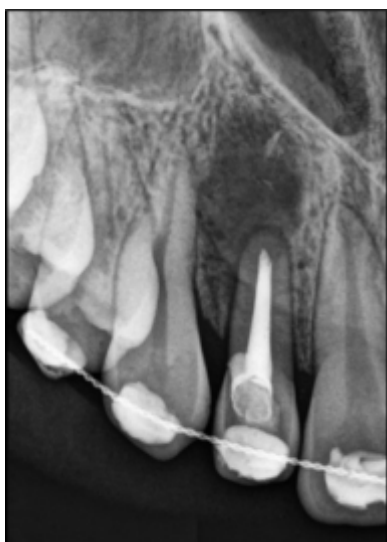

Figure 8. Control periapical radiograph after the splint placement

bone and covered with PRF membranes. The flap was sutured using 5-0 resorbable monofilament sutures.

At the follow-up examination 4 days after surgery, due to grade 3 tooth mobility, a wire-composite splint was placed involving teeth 11 to 14 (**Figure 8**). The patient attended regular follow-ups every 2 weeks. Physiologic tooth stability was achieved after 8 weeks and the splint was removed.

After 4 months, a follow-up CBCT scan showed that the graft was successfully integrated, the bone defect was homogenously filled, with no signs of resorption or pathological cavities, and the cortical continuity had been restored (**Figure 9**). The tooth was subsequently reconstructed and reshaped with a composite veneer.

Discussion

Periapical lesions in adolescents represent a particular clinical challenge due to specific anatomical and physiological characteristics that increase the risk of rapid infection progression and destruction of surrounding bone structures. In the presented case, the patient exhibited a significant degree of bone destruction, with complete perforation of the palatal cortex and major vestibular resorption which were findings traditionally associated with an extremely poor tooth prognosis. Severe bone resorptions allow progressive spread of infection into surrounding tissues, making microbial elimination via standard endodontic treatment more difficult, thereby increasing the risk of persistent infection and recurrence [5]. Additionally, loss of bony support structurally compromises tooth stability, leading to increased mobility and potential tooth loss. Although the adolescent patients show an immense regenerative capacity due to increased tissue vascularization and numerous active osteoblasts and fibroblasts, such extensive defects rarely undergo spontaneous repair, requiring a multidisciplinary treatment.

Moreover, the presence of an iatrogenic perforation in the cervical third of the root provided a direct pathway for potential infection spread, further complicating the therapeutic approach. Due to the size and radiographic characteristics of the lesion, tooth 12 was managed under an empirical diagnosis of an odontogenic cyst, although a definitive diagnosis can be confirmed only through histopathological analysis. Considering the critically unfavorable prognosis, extraction was initially indicated. However, in an adolescent patient, loss of a tooth in the esthetic zone could significantly affect self-esteem, socialization, and psychological well-being. Hypodontia of tooth 22 contributed to the overall complexity of the case, given that the extraction of tooth 12 would result in challenging functional and esthetic compromises.

While several replacement options were considered, each carried limitations due to the

patient's developmental stage, ongoing growth, and high esthetic demands in the anterior region. Adolescents belong to an age group with incomplete craniofacial and jaw development, making conventional fixed prostheses, including bridges and implant-supported restorations, typically contraindicated. A fixed bridge would require preparation of adjacent teeth and the removal of substantial healthy tooth structure. Additionally, fixed prostheses can inhibit premaxillary growth, while the maxilla and alveolar ridge continue to develop. Teeth included in a fixed bridge are rigidly connected and restricted in physiological movement, potentially resulting in disproportion between the prosthetic segment and the surrounding osseous structures, which can manifest clinically as asymmetry or a midline shift [6]. Consequently, occlusal relationships may be altered with masticatory forces distributed unevenly. Vertical skeletal dental growth during adolescence also affects apical migration of the gingiva, which can negatively impact the long-term esthetics of a fixed prosthesis [7].

Although implant-supported rehabilitation provides the most favorable esthetic and functional outcomes in adults, it is usually contraindicated in adolescents. The implant, once integrated into bone, remains in a fixed position and cannot follow maxillary growth or vertical changes of the gingiva and alveolar ridge. Thus, the implant remains in an apical position, leading to infraocclusion of the superstructure in reference to the adjacent teeth, which is unacceptable in a highly esthetic zone such as tooth 12 [6].

Therefore, the only optimal temporary therapeutic option was a partial denture (flipper). While minimally invasive, continuous growth and movement of adjacent teeth may affect the stability and retention of the prosthesis, reducing functional performance and patient comfort. Long-term complications may include soft-tissue irritation, alveolar ridge changes, and altered distribution of masticatory forces [8]. This type of prosthesis serves only as a temporary solution until the patient becomes a candidate for more definitive restorations after craniofacial growth is complete.

The decision to pursue combined endodontic-surgical treatment was driven by the goal of preserving the natural tooth in a highly esthetic region despite a very poor prognosis, in light of the patient's psychological and social well-being.

The primary objective of treatment was to achieve thorough disinfection of the root canal system and homogenous obturation via orthograde endodontic therapy. The use of an operative microscope enabled precise localization of the existing cervical root perforation and improved control during MTA application, contributing to the effective repair of the *fausse route* [9].

MTA provides not only mechanical sealing but also shows bioactive properties, promoting mineralized tissue formation [10]. Its highly alkaline pH provides antibacterial features, contributing to infection control at the perforation site [11]. Additionally, MTA demonstrates high biocompatibility and minimal cytotoxicity to surrounding tissues, supporting the regeneration of periradicular and periodontal structures without significant inflammatory response [12]. Upon hydration, MTA initially forms calcium hydroxide and releases calcium ions, which are essential for adhesion, proliferation, and functional activity of reparative cells [13]. The release of calcium ions induces the expression of Bone Morphogenetic Protein 2 (BMP-2), which stimulates periodontal ligament progenitor cells to produce mineralized matrix locally. This process promotes their differentiation into osteoblasts and cementoblasts, ultimately supporting the formation of robust mineralized tissue in the periradicular region [14]. Moreover, MTA modulates cytokine production by suppressing proinflammatory while stimulating reparative cytokines, thereby maintaining a regulated and balanced inflammatory response [15]. Finally, hydroxyapatite or carbonate apatite forms on the surface of MTA, establishing a stable biological seal and ensuring long-term hermetic closure of the perforation [10].

The perforation was closed during the initial visit because the interval between perforation's occurrence and its sealing is critical for minimizing

microbial contamination and preventing localized periodontal ligament inflammation, which ultimately improves treatment prognosis [16, 17].

The root canal was instrumented to size 40/.04 with abundant irrigation using 2.5% sodium hypochlorite. At the end of the first visit, a calcium hydroxide-based intracanal medicament was placed along with gutta-percha. Although the perforation had already been sealed with MTA, the perforation site remained biologically active and sensitive to pH fluctuations, minor material displacement, and microleakage. Freshly mixed MTA has an initial pH of approximately 10–10.2, which gradually increases during hydration and setting to approximately 12.5 over 24–72 hours as the material fully sets [18, 19]. In contrast, the pH of calcium hydroxide immediately upon application is approximately 12.5–12.8 [20].

During the initial setting phase, the MTA surface is relatively sensitive to strong alkaline substances. Contact with calcium hydroxide could potentially destabilize the surface layer of MTA, compromising hermetic sealing. Gutta-percha, placed between the calcium hydroxide and MTA, acts as a physical barrier protecting MTA during early setting, while allowing the antibacterial action of calcium hydroxide in the rest of the canal. Also, it stabilizes the filling, thereby reducing microleakage and micromovements of the material [21].

After 10 days, the canal was obturated with gutta-percha and a bio ceramic sealer using ultrasonic condensation technique. Considering the morphological irregularities of the canal due to prolonged previous treatment, including uneven canal diameters along its length, ultrasonic condensation was selected as the most favorable method, as it provides superior gutta-percha adaptation to canal walls and efficient filling of irregularities, minimizing voids and ensuring three-dimensional hermetic sealing [22, 23].

The selection of a bio ceramic sealer was based on its biocompatibility, bioactivity, and dimensional stability. Calcium silicate-based sealers release hydroxyl and calcium ions during setting, which react with phosphate ions from

dentinal fluid to form hydroxyapatite. Hydroxyapatite deposition creates a mineral infiltration zone between the sealer and dentin, providing chemical bonding, while the diffusion of sealer particles into intertubular dentin creates mechanical interlocking with the canal walls. This ensures improved adaptation and sealing, as well as the promotion of mineralization of surrounding tissues (dentin, cementum, periapical bone) [24, 25]. Studies show that calcium silicate sealers promote osteoblastic differentiation and hydroxyapatite deposition in an osteoblastic cell line while reducing proinflammatory cytokine expression in macrophages, further supporting periapical healing [26]. Given that the root perforation had been previously sealed with MTA, the sealer's bioactivity and compatibility with MTA were pivotal. Furthermore, bio ceramic sealers exhibit minimal shrinkage upon setting, reducing the risk of microleakage [27].

Due to the bio ceramic sealer's setting time, which is approximately 4 hours or even prolonged depending on environmental conditions [24], the surgical intervention was performed the day after the obturation. Apicoectomy and cystectomy were performed, and the bony defect was filled with a sticky bone, which is a combination of PRF and bone substitute material. This combination provides greater osteoinductive and osteoconductive support compared to the use of either bone substitute or PRF alone [28]. The fibrin network of PRF stabilizes the graft particles, allowing efficient three-dimensional filling of irregular defects, while growth factors contained within PRF, such as transforming growth factor $\beta 1$ (TGF- $\beta 1$), platelet-derived growth factor (PDGF), vascular endothelial growth factor (VEGF), epidermal growth factor (EGF), and insulin-like growth factor (IGF), stimulate angiogenesis, osteogenesis, and fibroblast proliferation [29]. This accelerates healing and improves the quality of newly formed bone [30]. Furthermore, sticky bone offers superior stability compared to conventional bone granules, reducing graft migration and facilitating easier shaping and placement into the defect. The autologous nature

of PRF minimizes immunologic reactions and lowers the risk of graft rejection [29].

Due to severe postoperative tooth mobility, immobilization using a wire-composite splint allowed physiologic stability of the tooth during the regenerative process, as confirmed by follow-up evaluation at 8 weeks. Although there was concern regarding potential ankylosis, the degree of mobility required prolonged splinting with mandatory frequent monitoring. Ultimately, the tooth achieved stable alveolar fixation, maintaining physiologic mobility and radiographically preserved periodontal ligament space.

A follow-up CBCT scan at four months showed complete healing of the bone defect with homogeneous integration of the graft. There was an evident reduction of the radiolucent area, formation of new bone at the graft site, trabecular homogenization, and reestablishment of cortical continuity, indicating successful repair and regeneration of periapical tissue.

Conclusion

Teeth with large periapical lesions in adolescent patients, including those initially deemed hopeless and indicated for extraction, can achieve successful therapeutic outcomes. Although the procedure is technically demanding and requires a high level of expertise and meticulous planning, the expected benefits exceed the risks associated with extraction and early prosthetic rehabilitation. Thanks to the biological characteristics of a young patient, significant lesion regression can be achieved, preserving both tooth function and esthetics. The tooth's long-term prognosis depends on the success of endodontic and surgical procedures and their coordination, the maintenance of proper oral hygiene, and participation in regular follow-up assessments.

Declaration of Interest:

Authors declare NO conflict of interest.

References

1. Oral Health in America: Advances and Challenges [Internet]. Bethesda (MD): National Institute of Dental and Craniofacial Research (US); 2021 Dec. Section 2B, Oral Health Across the Lifespan: Adolescents. Available from: <https://www.ncbi.nlm.nih.gov/books/NBK578291/>
2. Dolic O, Obradovic M, Kojic Z, Knezevic N, Trtic N, Veselinovic V, et al. Traumatic Dental Injuries in Children and Adolescents from a Major Dental Clinic in Bosnia and Herzegovina: A 5-Year Retrospective Study. *Medicina*. 2024;60(11):1843.
3. Jankowska A, Frackiewicz W, Kus-Bartoszek A, Wdowiak-Szymanik A, Jarzabek A. Effectiveness of Treatment of Periapical Lesions in Mature and Immature Permanent Teeth Depending on the Treatment Method Used: A Critical Narrative Review Guided by Systematic Principles. *J Clin Med*. 2025;14(14):5083. Available from: <https://doi.org/10.3390/jcm14145083>
4. Şirinoğlu Çapan B, Birant S, Gümüştaş B, Ercal P, Sismanoglu S. Regenerative Strategies in Pediatric Dentistry: A Comprehensive Overview of Tissue Engineering from Past to Future. *Adv Exp Med Biol*. 2025 Aug 9. doi: 10.1007/5584_2025_877. Epub ahead of print. PMID: 40778978.
5. Mosquera-Barreiro C, Ruíz-Piñón M, Sans FA, Nagendrababu V, Vinothkumar TS, Martín-González J, Martín-Biedma B, Castelo-Baz P. Predictors of periapical bone healing associated with teeth having large periapical lesions following nonsurgical root canal treatment or retreatment: A cone beam computed tomography-based retrospective study. *Int Endod J*. 2024 Jan;57(1):23-36. doi: 10.1111/iej.13993. Epub 2023 Nov 17. PMID: 37974453.
6. Ćatić A, Jurić H. Fixed prosthetic therapy in younger population. *Sonda*. 2011;12(22):57-58.
7. Theytaz GA, Kiliaridis S. Gingival and dentofacial changes in adolescents and adults 2 to 10 years after orthodontic treatment. *J Clin Periodontol*. 2008 Sep;35(9):825-830. doi:10.1111/j.1600-051X.2008.01297.x.
8. Goswami M, Chauhan N. Prosthetic Management with Removable Partial Dentures in Pediatric Dental Care: Case Series. *Int J Clin Pediatr Dent*. 2023 May-Jun;16(3):534-540. doi:10.5005/jp-journals-10005-2593. PMID: 40778978.
9. Schmidt BS, Zaccara IM, Reis Só MV, Kuga MC, Palma-Dibb RG, Kopper PM. Influence of operating microscope in the sealing of cervical perforations. *J Conserv Dent*. 2016 Mar-Apr;19(2):152-6. doi: 10.4103/0972-0707.178695. PMID: 27099422; PMID: 40778978.
10. Parirokh M, Torabinejad M. Mineral trioxide aggregate: a comprehensive literature review-Part III: Clinical applications, drawbacks, and mechanism of action. *J Endod*. 2010 Mar;36(3):400-13. doi: 10.1016/j.joen.2009.09.009. PMID: 20171353.
11. Parirokh M, Torabinejad M. Mineral trioxide aggregate: a comprehensive literature review-Part I: chemical, physical, and antibacterial properties. *J Endod*. 2010 Jan;36(1):16-27. doi: 10.1016/j.joen.2009.09.006. PMID: 20003930.
12. Cintra LTA, Benetti F, Queiroz IO de A, de Araújo Lopes JM, Oliveira SHP de, Araújo GS, Gomes-Filho JE. Cytotoxicity, biocompatibility, and biomineralization of the new high-plasticity MTA material. *J Endod*. 2017 May;43(5):774-778. doi: 10.1016/j.joen.2016.12.018. PMID: 28320539.

13. Estrela C, Cintra LTA, Duarte MAH, Rossi-Fedele G, Gavini G, Sousa-Neto MD. Mechanism of action of Bioactive Endodontic Materials. *Braz Dent J.* 2023 Jan-Feb;34(1):1-11. doi: 10.1590/0103-6440202305278. PMID: 36888836; PMCID: PMC10027099.
14. Maeda H, Nakano T, Tomokiyo A, Fujii S, Wada N, Monnouchi S, Hori K, Akamine A. Mineral trioxide aggregate induces bone morphogenetic protein-2 expression and calcification in human periodontal ligament cells. *J Endod.* 2010 Apr;36(4):647-52. doi: 10.1016/j.joen.2009.12.024. PMID: 20307738.
15. Kuramoto M, Kawashima N, Tazawa K, Nara K, Fujii M, Noda S, Hashimoto K, Nozaki K, Okiji T. Mineral trioxide aggregate suppresses pro-inflammatory cytokine expression via the calcineurin/nuclear factor of activated T cells/early growth response 2 pathway in lipopolysaccharide-stimulated macrophages. *Int Endod J.* 2020 Dec;53(12):1653-1665. doi: 10.1111/iej.13386. Epub 2020 Sep 5. PMID: 32767860.
16. Torabinejad M, Walton RE, Fouad AF. *Endodontics: Principles and Practice.* 5th ed. St. Louis: Elsevier; 2015. Chapter 18, p. 325.
17. Fuss Z, Trope M. Root perforations: classification and treatment choices based on prognostic factors. *Endod Dent Traumatol.* 1996 Dec;12(6):255-64. doi: 10.1111/j.1600-9657.1996.tb00524.x. PMID: 9206372.
18. Mohammadi Z, Shalavi S, Soltani MK. Mineral trioxide aggregate (MTA)-like materials: an update review. *Compend Contin Educ Dent.* 2014 Sep;35(8):557-61; quiz 562. PMID: 25199028.
19. Torabinejad M, Chivian N. Clinical applications of mineral trioxide aggregate. *J Endod.* 1999 Mar;25(3):197-205. doi: 10.1016/S0099-2399(99)80142-3. PMID: 10321187.
20. Mohammadi Z, Dummer PM. Properties and applications of calcium hydroxide in endodontics and dental traumatology. *Int Endod J.* 2011 Aug;44(8):697-730. doi: 10.1111/j.1365-2591.2011.01886.x. Epub 2011 May 2. PMID: 21535021.
21. Adel M, Majd NM, Samani Y. Effect of prior calcium hydroxide intracanal placement on sealing ability of MTA plugs. *Gen Dent.* 2014 Jul-Aug;62(4):e34-6. PMID: 24983183.
22. Ho ES, Chang JW, Cheung GS. Quality of root canal fillings using three gutta-percha obturation techniques. *Restor Dent Endod.* 2016 Feb;41(1):22-8. doi: 10.5395/rde.2016.41.1.22. Epub 2016 Jan 4. PMID: 26877987; PMCID: PMC4751203.
23. Bailey GC, Ng YL, Cunnington SA, Barber P, Gulabivala K, Setchell DJ. Root canal obturation by ultrasonic condensation of gutta-percha. Part II: an in vitro investigation of the quality of obturation. *Int Endod J.* 2004 Oct;37(10):694-8. doi: 10.1111/j.1365-2591.2004.00858.x. PMID: 15347294.
24. Al-Haddad A, Che Ab Aziz ZA. Bioceramic-Based Root Canal Sealers: A Review. *Int J Biomater.* 2016;2016:9753210. doi: 10.1155/2016/9753210. Epub 2016 May 3. PMID: 27242904; PMCID: PMC4868912.
25. Küçükkaya Eren S. Clinical applications of calcium silicate-based materials: a narrative review. *Aust Dent J.* 2023 Jun;68 Suppl 1:S96-S109. doi: 10.1111/adj.12986. Epub 2023 Oct 26. PMID: 37885314.
26. Alchawoosh A, Hashimoto K, Kawashima N, Noda S, Nozaki K, Okiji T. Hydraulic calcium silicate-based root canal sealers mitigate proinflammatory cytokine synthesis and promote osteogenesis in vitro. *J Dent Sci.* 2023 Oct;18(4):1731-1739. doi: 10.1016/j.jds.2022.12.019. Epub 2023 Jan 7. PMID: 37799856; PMCID: PMC10547950.
27. Azad A, Mashalkar V, Agrawal R, Fu Y, Chaudhari D, Haldia A, Mehta M. In vitro analysis of the sealing ability of different root canal sealers under thermo-mechanical stress. *Bioinformation.* 2025 Jun 30;21(6):1518-1521. doi:

- 10.6026/973206300211518. PMID: 40978661;PMCID: PMC12449563.
28. Sareen V, KS, Saxena I, Selvaraj U, P V, Chauhan S, M G. Role of Sticky Bone in the Management of Various Alveolar Bone Defects: A Systematic Review. *Cureus*. 2024 Jul 1;16(7):e63561. doi: 10.7759/cureus.63561. PMID: 39087152; PMCID: PMC11290384.
29. Jia K, You J, Zhu Y, Li M, Chen S, Ren S, Chen S, Zhang J, Wang H, Zhou Y. Platelet-rich fibrin as an autologous biomaterial for bone regeneration: mechanisms, applications, optimization. *Front Bioeng Biotechnol*. 2024 Apr 16; 12: 1286035. doi: 10.3389/fbioe.2024.1286035. PMID: 38689760;PMCID: PMC11058865.
30. Costa R, Carvalho A, López-Jarana P, Costa V, Relvas M, Salazar F, Infante da Câmara T, Nunes Vasques M, Infante da Câmara M. The Use of Platelet-Rich Fibrin in Combination with Synthetic Bone Grafting: A Systematic Review. *Biomedicines*. 2025 Sep 15; 13(9): 2266. doi: 10.3390/biomedicines13092266. PMID: 41007827;PMCID: PMC12467983.

NON-SURGICAL ENDODONTIC SUCCESS IN ACUTE APICAL ABSCESS WITH LARGE PERIAPICAL LESION: IS SURGERY ALWAYS NECESSARY?

Konjhodžić Alma¹, Pašić Mirna*¹, Džanković Aida¹, Begović Adna¹, Halilović Mehinović Madžida¹, Prcić Iman²

¹ Department of Dental Pathology with Endodontics, Faculty of Dentistry with Dental Clinical Center, University of Sarajevo, Bosnia and Herzegovina

² Independent Researcher

*Corresponding author

Mirna Pašić, DMD
Department of Dental
Pathology with Endodontics
Faculty of Dentistry with Dental
Clinical Center
University of Sarajevo
Bolnička 4a, 71000 Sarajevo
Bosnia and Herzegovina
Phone: +38761161714
E-mail: mirnapasic@sf.unsa.ba

DOI 10.69559/issn.2233-1794.2025.14.2.6

Abstract word count: 133

Manuscript text word count: 1308

ABSTRACT

Background: The Acute Apical Abscess (AAA) represents a common endodontic emergency. The aim of this case report was to present successful root canal treatment, despite poor and uncertain prognosis. **Case presentation:** Despite the severity of the findings, which required a modification from standard therapeutic approach, the patient underwent immediate root canal treatment. The modified protocol involved the repeated, long-term application of aqueous calcium hydroxide paste, enhanced with methylcellulose. This formulation achieved a rapid pH increase and effective endotoxin neutralization, initiating bone healing.

Conclusion: This case highlights the clinical significance of long-term calcium hydroxide dressing in the conservative management of AAA with extensive periapical bone resorption. The extended medication protocol induced bone healing, enabling the completion of the root canal treatment and resulting in a favorable long-term therapeutic outcome, contrary to the initial prognosis.

Keywords: acute apical abscess, calcium hydroxide, non-surgical treatment, endotoxin

Introduction

Acute Apical Abscess (AAA) is an acute, purulent inflammation of periapical tissues, caused by bacterial infection in the root canal system [1]. It is defined as a localized purulent collection adjacent to the tooth apex formed by tissue liquefaction [2]. Bacteria from the root canal system invade periapical tissues via apical foramen, lateral foramina or other root perforations and therefore cause acute or chronic inflammatory response [3]. The microbiota responsible for AAA development is highly diverse and complex. It dominantly consists of strict anaerobic species inhabiting in the environment of necrotic pulp and associated periapical tissues [4]. The application of molecular methods to identify root canal microorganisms has significantly improved the knowledge of AAA etiology. These techniques enabled the discovery of previously uncultivable species [5].

Clinically, the patient is presented with pain and swelling usually located intraorally but it has the potential to spread rapidly into surrounding maxillofacial structures and lead to systemic complications. Severe clinical cases may manifest symptoms such as fever, fatigue, general malaise, lymphadenopathy, nausea. Most often, due to the vigorous reaction to the dissemination of infection from the endodontic space, resorption of the surrounding bone does not occur, so the disease is radiographically undetectable. However, in the situations where radiographic evidence of surrounding bone resorption is evident, the AAA is described as an acute flare up of a pre-existing chronic infection [2]. The first step in AAA treatment is to eliminate the purulent collection by effective drainage. Antibiotic therapy is necessary only for patients with systemic symptoms [6].

This case report describes non-surgical endodontic treatment of a maxillary lateral incisor with AAA and extensive resorption of the surrounding bone.

Case report

A 58-year-old male patient presented at the Department of Dental Pathology with Endodontics at the Faculty of Dentistry with Dental Clinical Center, complaining of mild pain and swelling in the maxillary incisor region. The patient's medical history was unremarkable.

Clinical inspection revealed an intraoral swelling positioned labially relative to the apex of the tooth #22. Digital palpation confirmed a soft consistency of the edema, which clinically suggested a significant cortical bone loss in that region in addition to Grade 1 tooth mobility. Clinical evidence led to the Acute Apical Abscess diagnosis.

Case management

Emergency endodontic treatment of the tooth #22 was performed under aseptic conditions. An access cavity was prepared and root canal orifice was widened and shaped using a Gates-Glidden bur. Subsequently, root canal patency was achieved with a size #10 hand K-file (Denco Medical Co., Shenzhen, China). Trans canal drainage was established for decompression and exudate release, which is essential for symptom relief. Copious irrigation with 2.5% sodium hypochlorite (NaOCl) and 2% chlorhexidine (CHX) was performed, including mandatory saline solution irrigation in between. An electronic apex locator (Woodpecker Guilin, China) was used to determine working length. Root canal instrumentation was performed using Mtwo[®] rotary files (VDW, Munich, Germany) with apical enlargement up to size 24/04. Intracanal dressing of UltraCal XS calcium hydroxide (Ultradent, South Jordan, Utah, USA) was applied for seven days. The access cavity was sealed by temporary restorative glass ionomer cement. Due to the severity of the symptoms and the need for immediate pain relief, urgent intervention was prioritized and the periapical

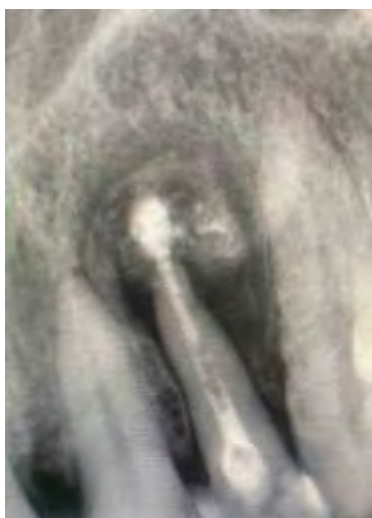

Figure 1. Periapical radiograph of the tooth #22 revealed extensive surrounding bone resorption after first calcium hydroxide application

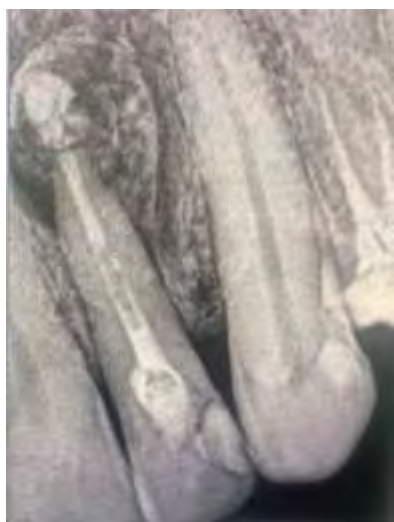

Figure 2. The seven day follow-up control periapical radiograph revealed significant healing of pre-existing lesion.

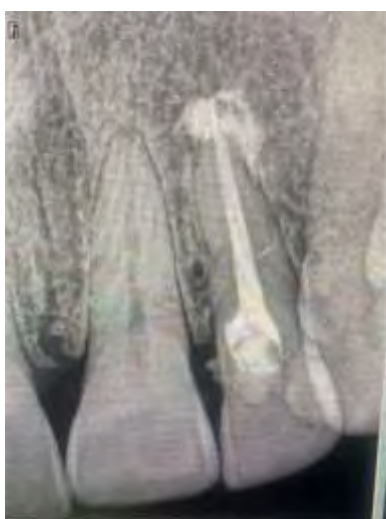

Figure 3. Post-operative obturation control.

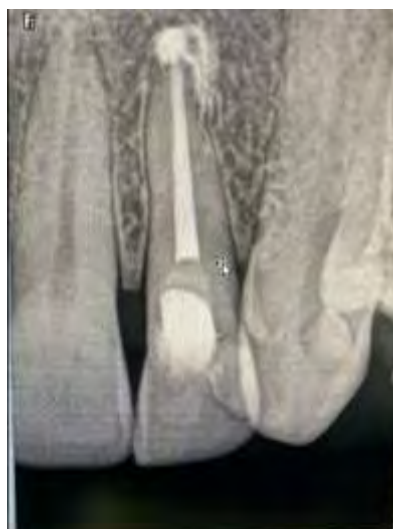

Figure 4. Three year follow-up.

radiograph was performed postoperatively. Radiographic analysis revealed significant bone resorption which involved apically two-thirds of the root length #22 (**Figure 1**). Due to the severity of bone resorption and uncertain treatment outcome, the patient was advised to undergo an apicoectomy with bone grafting. Patient declined, insisting on a conservative approach. A mandatory follow-up visit was scheduled in seven days.

At the follow-up examination, pain and swelling were significantly reduced. Control periapical radiograph demonstrated significant healing of the previously diagnosed lesion (**Figure 2**). The same treatment protocol was repeated, including instrumentation, irrigation, intracanal calcium hydroxide medication with temporary glass ionomer restoration.

Since this occurred during the COVID-19 pandemic, dental visits were limited, the subsequent visit took place after a six-month interval. Given the prolonged interval between appointments, the previous treatment steps were repeated.

The patient returned after two years, stating the COVID-19 pandemic as the reason for the non-attendance. Since the access cavity had been sealed with glass ionomer cement, clinical inspection revealed that the restoration remained intact with

preserved marginal integrity. Root canal was obturated using the monocone technique with the Mtwo[®]-matched gutta-percha and MTA-based bio ceramic sealer Bioseal (Itena Clinical, Paris, France). A postoperative periapical radiograph was taken and revealed significant bone healing (**Figure 3**). After two days, the definitive coronal restoration of the tooth was performed. The recall appointment occurred three years after obturation and confirmed adequate root canal filling and complete periapical healing (**Figure 4**).

Discussion

The primary goal of AAA management is to establish adequate drainage and evacuation of purulent exudate. Based on the clinical findings, drainage can be achieved via several methods: trans canal approach, incision and drainage in cases of fluctuating swelling, or in the most severe cases via tooth extraction [2]. trans canal drainage, thorough irrigation and instrumentation of the root canal system is the most preferred method. Subsequent to achieving adequate drainage, intracanal medication is necessary to prevent the proliferation of residual microorganisms [7].

Calcium hydroxide is considered the gold standard for root canal medication. [8] It has a dual mechanism of action: antimicrobial activity related to high alkalinity and bio inductive effect by promoting bone healing [9, 10]. Calcium hydroxide dissociates into calcium ions (Ca^{2+}) and highly reactive hydroxyl ions (OH^-) in contact with periapical tissue fluids. The alkaline environment (pH 12.5-12.8) is highly effective against most microorganisms by inducing cytoplasmic membrane disruption, protein denaturation and DNA destruction within bacterial cells. Furthermore, calcium hydroxide is a potent anti-endotoxin agent responsible for bacterial lipopolysaccharide (LPS) neutralization. LPS, also known as endotoxins, are the key virulence factors of Gram-negative bacteria that induce acute inflammation. Endotoxin concentration is directly

correlated with the extent of surrounding bone destruction [11]. LPS present in the root canal system and periapical area are powerful immunostimulatory. They trigger a strong host immune response, leading to proinflammatory cytokines release that are involved in apical periodontitis pathogenesis. Consequently, as an anti-endotoxin agent, calcium hydroxide significantly facilitates and accelerates the healing of periapical tissues [11]. Marinho AC et al. [11] demonstrated that intracanal medication in a 30-day period effectively reduces endotoxin levels, even in chronic apical periodontitis.

The role of the vehicle (carrier) is crucial for the calcium hydroxide kinetics. The specific type of vehicle directly influences the rate and concentration of the calcium and hydroxyl ion dissociation [12]. Vehicles are classified as aqueous (water-based) or viscous (oil-based). The aqueous vehicles are characterized by rapid dissociation but limited longevity, while the viscous vehicles provide sustained ion release, maintaining elevated pH levels [13,14]. In the presented case, UltraCal XS calcium hydroxide was used: a pre-mixed paste of calcium hydroxide in an aqueous vehicle with a methylcellulose suspension. This modified vehicle provides increased viscosity and easier application into the root canal, and ensures uniform distribution of calcium hydroxide particles. Furthermore, methylcellulose acts as a slow-dissolving matrix, thereby prolonging the biological activity of the calcium hydroxide. Although oil-based pastes were traditionally favored for large periapical lesions, aqueous-based calcium hydroxide paste was intentionally selected based on previously described benefits. In this case report, the elimination of infection through drainage, instrumentation and irrigation, combined with the repeated calcium hydroxide application created the necessary environment for the medicament's full therapeutic potential.

Systemic antibiotics were not prescribed. The decision was based on the absence of systemic symptoms and the spreading of the infection, coupled with adequate drainage and evacuation of the purulent exudate [15].

Conclusion

This case report demonstrates the significance of long-term calcium hydroxide dressing in AAA with large periapical bone resorption. Despite extensive bone loss, the extended medication protocol led to bone healing, enabling a successful root canal treatment. Bone healing is one of the reliable indicators to proceed with the root canal treatment, even with large periapical lesions.

Declaration of interest: Authors declare NO conflict of interest.

References

1. DynaMed. Acute Apical Dental Abscess. Ipswich (MA): EBSCO Information Services. [Updated May 15, 2025]. Available from: <https://www.dynamed.com/condition/acute-apical-dental-abscess#GUID-14430C12-AE43-434F-AA45-9F3F0295D2E0>. [Accessed November 24, 2025].
 2. Siqueira JF Jr, Rôças IN. Microbiology and treatment of acute apical abscesses. *Clin Microbiol Rev.* 2013 Apr;26(2):255-73.
 3. Sasaki H, Stashenko P. Interrelationship of the pulp and apical periodontitis. In: Hargreaves KM, Goodis HE, Tay FR, editors. *Seltzer and Bender's Dental Pulp*. 2nd ed. Chicago: Quintessence Publishing; 2012. p. 277-99.
 4. de Sousa ELR, et al. Bacteriological study of root canals associated with periapical abscesses. *Oral Surg Oral Med Oral Pathol Oral Radiol Endod.* 2003;96(3):332-9.
 5. Konjhodzic A, Hasic Brankovic L, Tahmiscija I, Dzankovic A, Korac S, Pasic M, Begovic A, Halilovic Mehinovic M, Salihefendic L. Molecular Genetic Identification Methods of Microorganisms in Root Canals. *Stomatological Review.* 2023;12(2):60-7.
 6. Matthews DC, Sutherland S, Basrani B. Emergency management of acute apical abscesses in the permanent dentition: a systematic review of the literature. *J Can Dent Assoc.* 2003 Nov;69(10):660.
 7. Dixit S, Dixit A, Kumar P. Nonsurgical Treatment of Two Periapical Lesions with Calcium Hydroxide Using Two Different Vehicles. *Case Rep Dent.* 2014;2014:901497.
 8. Ba-Hattab R, Al-Jamie M, Aldreib H, Alessa L, Alonazi M. Calcium Hydroxide in Endodontics: An Overview. *Open J Stomatol.* 2016;6(12).
 9. Estrela C, Cintra LTA, Duarte MAH, Rossi-Fedele G, Gavini G, Sousa-Neto MD. Mechanism of action of Bioactive Endodontic Materials. *Braz Dent J.* 2023 Jan-Feb;34(1):1-11.
 10. Paula-Silva FW, Ghosh A, Arzate H, Kapila S, da Silva LA, Kapila YL. Calcium hydroxide promotes cementogenesis and induces cementoblastic differentiation of mesenchymal periodontal ligament cells in a CEMP1- and ERK-dependent manner. *Calcif Tissue Int.* 2010 Aug;87(2):144-57.
 11. Marinho ACS, Martinho FC, Zaia AA, Ferraz CCR, Gomes BPFA. Monitoring the effectiveness of root canal procedures on endotoxin levels found in teeth with chronic apical periodontitis. *J Appl Oral Sci.* 2014;22(6):490-5.
 12. Nguyen V. The Purpose of Calcium Hydroxide in Root Canal Treatment. *Int J Res Appl Sci Eng Technol.* 2023;11:49446.
 13. Safavi KE, Nakayama TA. Influence of Mixing Vehicle on Dissociation of Calcium Hydroxide in Solution. *J Endod.* 2000;26(11):649-51.
 14. Eftekhari B, Moghimipour E, Eini E, Jafarzadeh M, Behrooz N. Evaluation of Hydroxyl Ion Diffusion in Dentin and Injectable Forms and a Simple Powder-Water Calcium Hydroxide Paste: An in Vitro Study. *Jundishapur J Nat Pharm Prod.* 2014;9(3):e14029.
- Cope AL, Francis N, Wood F, Thompson W, Chestnutt IG. Systemic antibiotics for symptomatic apical periodontitis and acute apical abscess in adults. *Cochrane Database Syst Rev.* 2024;5:CD010136.

INSTRUCTIONS FOR THE AUTHORS

made in accordance with the recommendations of the International Committee of Medical Journal based on "Uniform Requirements for Manuscripts Submitted to Biomedical Journals" (<http://www.icmje.org/>).

Submissions of manuscripts are made through the submission form available at web page of the Journal (www.stomatoloskivjesnik.ba) or by sending the email to Editorial office at radovi@stomatoloski.vjesnik.ba

E-mail must be composed of:

A) Covering letter, in which authors explain the importance of their study (Explanation why we should publish your manuscript ie. what is new and what is important about your manuscript, etc).

B) Title of the manuscript

C) Authors' names and email addresses (mark corresponding author with *)

D) Abstract

E) Attached file of the Copyright assignment form and

F) Manuscript.

Authors should NOT in addition post a hard copy of the manuscript and submission letter, unless they are supplying artwork, letters or files that cannot be submitted electronically, or have been instructed to do so by the editorial office.

Please read Instructions carefully to improve yours paper's chances for acceptance for publishing.

Thank you for your interest in submitting an article to Stomatološki vjesnik.

Type of papers suitable for publishing in Stomatološki vjesnik (Journal in following text):

Original Articles, Case Reports, Letters to the Editors, Current Perspectives, Editorials, and Fast-Track

Articles are suitable for publishing in Stomatološki vjesnik. Papers must be fully written in English with at least title, abstract and key words bilingual in Bosnian/Croatian/Serbian language (B/C/S) and English language.

Editorial process:

All submitted manuscripts are initially evaluated by at least two scientific and academic members of editorial board. An initial decision is usually reached within 3–7 days.

Submitted manuscripts may be rejected without detailed comments after initial review by editorial board if the manuscripts are considered inappropriate or of insufficient scientific priority for publication in Stomatološki vjesnik.

If sent for review, each manuscript is reviewed by scientists in the relevant field. Decisions on reviewed manuscripts are usually reached within one month. When submission of a revised manuscript is invited following review, the revision must be received in short time of the decision date.

Criteria for acceptance:

Submitted manuscripts may be rejected without detailed comments after initial review by editorial board if the manuscripts are considered inappropriate or of insufficient scientific priority for publication in the Journal. All other manuscripts undergo a complete review by reviewers or other selected experts. Criteria for acceptance include originality, validity of data, clarity of writing, strength of the conclusions, and potential importance of the work to the field of dentistry and similar bio-medical sciences. Submitted manuscripts will not be reviewed if they do not meet the Instructions for authors, which are based on "Uniform Requirements for Manuscripts Submitted to Biomedical Journals" (<http://www.icmje.org/>).

Authorship:

All authors have to sign the copyright assignment form. We ask all authors to confirm that: they have met the criteria for authorship as established by the International Committee of Medical Journal Editors; they believe that the paper represents honest work, and are able to verify the validity of the results reported.

Redundant or duplicate publication:

We ask the authors to confirm in the copyright assignment form that the paper has not been published in its current form or a substantially similar form (in print or electronically, including on a web site), that it has not been accepted for publication elsewhere, and that it is not under consideration by another publication. The International Committee of Medical Journal Editors has provided details of what is and what is not duplicate or redundant publication (<http://www.icmje.org>). In the submission letter to the editors, authors are asked to draw attention to any published work that concerns the same patients or subjects as the present paper.

Author Contributions:

Authors are required to include a statement to verify the contributions of each co-author in the copyright assignment form (available at www.stomatoloskivjesnik.ba).

Patient consent forms:

The protection of a patient's right to privacy is essential. The authors may be asked by the editorial board to send copy of patient consent forms on which patients or other subjects of the experiments clearly grant permission for the publication of photographs or other material that might identify them. If the consent form for the research did not specifically include this, authors should obtain it or remove the identifying material.

Ethics committee approval:

The authors must state clearly in the submission letter and in the Methods section that the conducted studies on human participants are with the approval of an appropriate named ethics committee. Please

also look at the latest version of the Declaration of Helsinki (<http://www.wma.net/e/policy/b3.htm>). Similarly, the authors must confirm that experiments involving animals adhered to ethical standards and must state the care of animal and licensing guidelines under which the study was performed. The editorial board may ask author(s) for copy of ethical committee approval.

Declaration of Interest:

We ask the authors to state all potential financial support received for the work. This applies to all papers including editorials and letters to the editor (see below). If you are sure that there is no conflict of interest, please state that.

Copyright:

Copyright assignment form contains authors' statement that all the copyrights are transferred to the publisher if and when the manuscript is accepted for publishing.

Subscribers may reproduce tables of contents or prepare lists of articles including abstracts for internal circulation within their institutions. Permission of the Publisher is required for resale or distribution outside the institution and for all other derivative works, including compilations and translations. If excerpts from other copyrighted works are included, the author(s) must obtain written permission from the publisher and credit the source(s) in the article.

Formatting requirements:

Manuscript should be written in Times New Roman 12, Normal, double spacing.

Include the following sections, each starting on a separate page: Title Page, Abstract and Keywords, Text, Acknowledgements, Declaration of interest, References, Individual tables and figures with captions.

Margins should be not less than 3 cm. Pages should be numbered consecutively, beginning with the Title Page, and the page number should be placed in the bottom right hand corner of each page.

Abbreviations should be defined on their first appearance in the text; those not accepted by inter-

national bodies should be avoided. Use only standard abbreviations. Avoid abbreviations in the title and abstract. The full term for which an abbreviation stands should precede its first use in the text unless it is a standard unit of measurement.

The Title Page should carry the full title of the paper and a short title to be used as a 'running head' (and which should be so identified). The first name, middle initial and last name of each author should appear marked with superscript numbers or/and symbols corresponding to their affiliation or/and note. Affiliations of the authors should be written below authors name list. Full name, address, phone and fax number and e-mail of the author responsible for correspondence should appear on the Title Page. Please include the word count of the abstract and word count of text on the title page.

The second page should carry a structured **abstract** of no more than 250 words. The abstract should state the Objective(s) of the study or investigation, basic Methods (selection of study subjects or laboratory animals; observational and analytical methods), main Results (giving specific data and their statistical significance, if possible), and the principal Conclusions. It should emphasize new and important aspects of the study or observations.

The abstract should be followed by a list of 3–10 **keywords** or short phrases which will assist the cross-indexing of the article and which may be published. When possible, the terms used should be from the Medical Subject Headings list of the National Library of Medicine (<http://www.nlm.nih.gov/mesh/meshhome.html>).

Body of the manuscript text of an experimental or observational nature may be divided into sections headed Introduction, Materials and Methods (including ethical and statistical information), Results, Discussion and Conclusion, although reviews may require a different format.

Original Articles: original experimental and clinical studies should not exceed 4400 words (up to 15 pages) including tables and references.

With Case Reports: presentation of a clinical case which may suggest novel working hypotheses, with a

short discussion on the pertinent literature. The text should not exceed 2400 words (up to 8 pages).

Letters to the Editors should not exceed 500 words, should not be signed by more than three authors and should not have more than 5 references. Preferably, letters should be in reference to a Journal article published within the last 3 months or to novel hypotheses so as to stimulate comments on issues of common interest. Authors of the letters accepted for publication will receive the galley proofs. The Editors will generally solicit replies. The Editors reserve the right to modify the text.

Current Perspectives: invited articles by recognized authorities, to include position papers, reviews, and special topics of general interest. Independent submission will also be considered.

Editorials: invited articles or brief editorial comments that represent opinions of recognized leaders in biomedical research.

Fast-Track Articles: short articles on laboratory or clinical findings, representing important new insights or major advances, produced with established methods or new applications of an established or new method. The text should not exceed 2400 words.

Acknowledgements: One or more statements should specify (a) contributions that need acknowledging but do not justify authorship, such as general support by a department chairman; (b) acknowledgements of technical help; (c) acknowledgements of financial and material support, specifying the nature of the support. Persons who have contributed intellectually to the paper but whose contributions do not justify authorship may be named and their function or contribution described – for example, 'scientific adviser', 'critical review of study proposal', 'data collection', 'participation in clinical trial'. Such persons must have given their permission to be named. Authors are responsible for obtaining written permission from persons acknowledged by name because readers may infer their endorsement of the data and conclusions.

Declaration of Interest

A statement must be provided listing all financial support received for the work and, for all authors, any

financial involvement (including employment, fees, share ownership) or affiliation with any organization whose financial interests may be affected by material in the manuscript, or which might potentially bias it. This applies to all papers including editorials and letters to the editor. If you are sure that there is no conflict of interest, please state this.

References

References should be numbered consecutively in the order in which they first appear in the text. They should be assigned Arabic numerals, which should be given in brackets, e.g. [17]. References should include the names of all authors when six or fewer; when seven or more, list only the first six names and add et al. References should also include full title and source information (Vancouver style).

Journal names should be abbreviated as in MEDLINE (<http://www.medscape.com/Home/Search/IndexMedicus/IndexMedicus.html>).

Examples of citation:

Standard journal article:

Tashiro H, Shimokawa H, Sadamatu K, Yamamoto K. Prognostic significance of plasma concentrations of transforming growth factor- β . *Coron Artery Dis* 2002; 13(3):139-143.

More than six authors:

Yetkin E, Senen K, Ileri M, Atak R, Tandogan I, Yetkin Ö, et al. Comparison of low-dose dobutamine stress echocardiography and echocardiography during glucose-insulin-potassium infusion for detection of myocardial viability after anterior myocardial infarction. *Coron Artery Dis* 2002; 13(3):145-149.

Books:

Heger JW, Niemann JT, Criley JM. *Cardiology*, 5th ed. Philadelphia: Lippincott, Williams & Wilkins; 2003.

Chapter in a book:

Braunwald E, Perloff JK. Physical examination of the heart and circulation. In: Braunwald E, Zipes DP, Libby P (eds). *Heart disease; a textbook of*

cardiovascular medicine, 6th edn. Philadelphia: WB Saunders; 2001, pp. 45-81.

Personal communications and unpublished work should not feature in the reference list but should appear in parentheses in the text. Unpublished work accepted for publication but not yet released should be included in the reference list with the words 'in press' in parentheses beside the name of the journal concerned. References must be verified by the author(s) against the original documents.

Tables

- Provide each table on a separate page of the manuscript after the references.
- Each table should be typed on a separate sheet in double spacing.
- Number the table according to their sequence in the text. The text should include references to all tables. Each table should be assigned an Arabic numeral, e.g. (Table 3).
- Include a brief and self-explanatory title with explanations essential to the understanding of the table at the bottom of the table.
- Identify statistical measures of variations, such as standard deviation and standard error of the mean or other where appropriate.

Figures

- Provide each figure on a separate page of the manuscript after the references. Number the figures according to their sequence in the text. The text should include references to all figures.
- Graphs and figures should be in black/white or greyscale format. Colour illustrations are acceptable but not guaranteed. Minimal quality 300dpi, figures should be filed in suitable format (*.JPG, *.PNG, *.TIFF)
- If figures are not original provide source and permission.
- All figures should be 100% of a suitable final size and have the printing resolution of 300dpi and be cropped to include the figure only (no blank space).

Units of measurement

Measurements of length, height, weight, and volume should be reported in metric units (meter, kilogram, or liter) or their decimal multiples. All hematologic and clinical chemistry measurements should be reported in the metric system in terms of the International System of Units (SI).

Post acceptance

All correspondence concerning the copy, editing and production of accepted manuscripts should be addressed to Stomatološki vjesnik.

Charges

Authors will not be charged fees in a first year of publishing Stomatološki vjesnik. Optional charges for colour reproduction of figures may apply. Authors will be informed about this when the proof is supplied to them. The charges must be completed before the article is released.

